

Case report : Pulmonary neoplasia associated with hypertrophic osteoarthropathy in a cow



Guyot H., Sandersen C., Jacquinet E. and Rollin F.

University of Liege, Faculty of Veterinary Medicine, Department of Clinical Sciences, Large Animal Internal Medicine



INTRODUCTION

Hypertrophic osteoarthropathy (HOA), also called acropachy or Marie's disease refers to the formation of subperiosteal new bone on the distal diaphyses of long bones or on the axial skeleton or facial bones, with nonedematous swelling of the extremities and occasional swelling and tenderness of joints. The precise cause of the unusual association between chronic pulmonary disease and periosteal proliferation of bone remains obscure. It was first described in humans at the end of the last century (1). Although known to occur in all domestic animal species, HOA is only rarely described in cattle.

CASE REPORT

A 12-year old cow was presented to our clinic with chronic respiratory disease and recent lameness. The cow showed a mixed dyspnoea, without cough and nasal discharge and excessive whistling audible on lung auscultation. The cow did not show any sign of fever. Its appetite was normal though the body condition was poor. Its walk was stiff, the four limbs being swollen and painful on palpation. Prescapular lymph nodes were hypertrophied. Blood examination revealed hyperproteinemia due to hyper-globulinemia. CBC and ionic profile were within normal range. Clinical diagnosis was chronic pneumonia with a suspicion of hypertrophic osteoarthropathy. Two months later, the cow was re-admitted to our clinic. Its general condition was aggravated. Spontaneous and fitful cough with a bilateral purulent discharge were present. Percussion revealed an increased lung field. On lung auscultation, whistling sounds were increased. They were audible over the left and right diaphragmatic lobes, being more important over the left side. Lameness and pain were also aggravated. Diagnosis of hypertrophic osteoarthropathy was based on clinical symptoms. Lungs and legs radiographs revealed increased opacity of the lung and light pleural effusion. Symmetrical periosteal proliferation, which could be characterised by a homogeneous thickness, smooth borders and a non-invasive aspect, was present. Because of the poor prognosis, the cow was euthanised.

Necropsy findings confirmed lesions of hypertrophic osteoarthropathy on the four limbs. A chronic parietal and visceral pleuritis in the left thoracic cavity and a generalised chronic interstitial pneumonia were found. On the left lung, scattered throughout the lung tissue, a dozen of purulent and necrotic granulomatous nodular masses of different shape and size were seen. Moreover, a dilated cardiomyopathy of the right ventricle was found.

Microscopically, masses contained proliferative epithelial cells. Epithelial cells had clear and oval nuclei, with prominent nucleoli, some having numerous nucleoli. The presence of those epithelial proliferations indicates for a bronchial carcinoma but further investigations are needed to confirm the diagnosis.

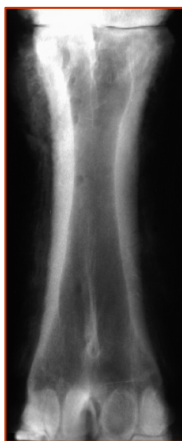

Photo 1 : Anteroposterior radiograph of right metacarpus

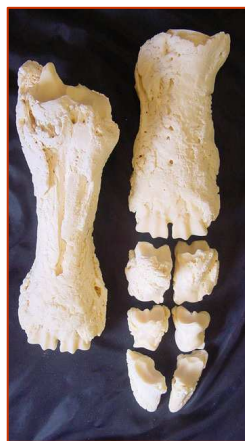

Photo 2 : Macroscopical aspect of the metatarsal (left) and metacarpal (right) bones and phalanges

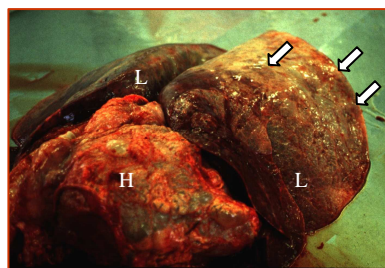


Photo 3 : Macroscopical aspect of the lungs (L) and the heart (H). Different masses (⊘) can be seen on the surface of the lung.

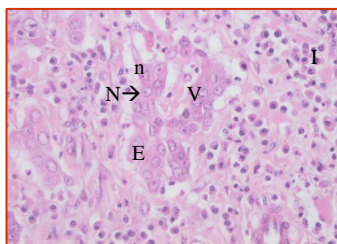
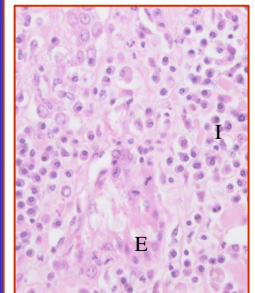


Photo 4-5 : Microscopical view of pulmonary masses (X 400 ; hematoxylin-eosin)

No normal pulmonary tissue is visible on these pictures. Proliferative epithelial cells (E), epithelial cells containing oval and clear nuclei (N) and prominent nucleoli (some epithelial cells having numerous nucleoli) (n), vacuolised epithelial cells (V), and inflammatory cells (I) are seen.

DISCUSSION

The osseous lesions of HOA are often associated with pulmonary disease, although the exact aetiology of the syndrome remains unclear. The disease involves two elements : proliferative changes of soft tissues, and periosteal proliferation of the limbs bones. Neural, humoral and hypoxic mechanisms have been proposed to explain HOA. According to the neural hypothesis, which seems to be the most credible, it appears to be a nervous reflex with afferent fibres originating in the thorax and efferent pathways affecting the connective tissue and periosteum of the limbs (2). The vagus nerve appears to play a key role in the disease since the changes in the distal limbs are often associated with a primary disease in areas of the body such as the lung, liver, diaphragm and the right side of the large colon, which are supplied by the vagus nerve (3) and since vagotomy allows bones lesions to regress (2). Furthermore, removal of the locus of afferent impulses by excision of the lung lesion will induce regression of the osseous lesions of HOA (2) as well as the administration of atropine sulfate (4). More recent knowledge suggests that HOA develops from the presence in the systemic circulation of one or more growth factors that are either normally inactivated in the lungs (5) or abnormally secreted by the primary lesion (tumours of endocrine glands or their pulmonary metastases) (6).

HOA has only been rarely described in cattle. Some cases have been reported in the literature including an 8-year-old Hereford cow with tracheobronchitis and a mummified fetus (3), a 5-year-old Hereford cow with pulmonary lesions (7), a 4-months-old Holstein calf with chronic broncho-pneumonia (8), a 10-year-old Ayrshire steer with chronic pneumonia (9) and a 3-months-old Holstein calf suffering from HOA of unknown aetiology (7).

Our findings are matching with those reported in the literature. Our case confirms that HOA is commonly related to lung diseases, although other primary lesions are possible. Our case is rendered exceptional by the fact that the primary lung lesion was neoplastic and not inflammatory as in all other reported cases. To our knowledge, this is the first description of HOA related to primary lung neoplasia in a cow.

REFERENCES

- (1) MARIE P. De l'ostéarthropathie hypertrophique pneumique. *Rev. Med. Paris*, 1890, 10 : 1-36
- (2) WATSON A.D.J., PORGES W.L. Regression of hypertrophic osteopathy in a dog following unilateral intrathoracic vagotomy. *Vet. Rec.*, 1973, 240-241
- (3) MARTIN S.W., PENNOCK P.W., PASS D. Hypertrophic pulmonary osteoarthropathy in a cow. *Can. Vet. Journal*, 1971, 12, 129-131
- (4) LOPEZ-ENRIQUET E., MORALES A.R., ROBERT F. Effect on Atropine Sulfate in pulmonary hypertrophic osteoarthropathy. *Arthritis Rheum.*, 1980, 7, 822-824
- (5) SILVEIRA L.H., MARTINEZ-LAVIN M., PINEIDA C., FONSECA M.C., NAVARRO C., NAVA A. Vascular endothelial growth factor and hypertrophic osteoarthropathy. *Clinic. Exp. Rheumatol.*, 2000, 1, 57-62
- (6) SUSANCK S.J., MACY D.W. Hypertrophic osteopathy. *Comp. Cont. Educ.*, 1982, 689-693
- (7) RAVARY B., FECTEAU G. Deux cas d'ostéopathie hypertrophique chez des bovins. *Le point vétérinaire*, 2000, 31, 71-77
- (8) SCHLACHER F., AUTEFAGE A., DELVERDIER M., ESPINASSE J., BEZILLE P., JOUGLAR J. Y. Ostéopathie hypertrophique chez un veau. *Revue Méd. Vet.*, 1989, 140, 567-571
- (9) MERRIT A.M., DODD D.C., REID C.F., BOUCHER W.B. Hypertrophic pulmonary osteopathy in a steer. *J. Am. Vet. Med. Ass.*, 1971, 159, 443-448