

Endobronchial ultrasound and value of PET for prediction of pathological results of mediastinal hot spots in lung cancer patients

Olivier Bauwens^a, Michelle Dusart^b, Philippe Pierard^a, Jean Faber^a, Thierry Prigogine^a, Bernard Duysinx^d, Bien Nguyen^{a,1}, Marianne Paesmans^c, Jean-Paul Soulier^c, Vincent Ninane^a

^a Chest Service, Saint-Pierre Hospital, Rue Haute 322, 1000 Brussels, Belgium ^b The Department of Nuclear Medicine, Institut Bordet, Brussels, Belgium ^c Internal Medicine, Institut Bordet, Brussels, Belgium ^d Chest Service, University Hospital, Liège, Belgium

Summary

In the staging of lung cancer with positron emission tomography (PET) positive mediastinal lymph nodes, tissue sampling is required. The performance of transbronchial needle aspiration (TBNA) using linear endobronchial ultrasound (real-time EBUS-TBNA) under local anaesthesia and the value of PET for prediction of pathological results were assessed in that setting. The number of eluded surgical procedures was evaluated. All consecutive patients with suspected/proven lung cancers and FDG-PET positive mediastinal adenopathy were included. If no diagnosis was reached, further surgical sampling was required. Lymph node SUVmax (maximum standardized uptake value) was assessed in patients whose PET was performed in the leading centre. One hundred and six patients were included. The average number of TBNA samples per patient was 4.9 ± 1.1 . The prevalence of lymph node metastasis was 58%. Sensitivity, accuracy and negative predictive value of EBUS-TBNA in the staging of mediastinal hot spots were 95, 97 and 91%. Patients without malignant lymph node involvement showed lower SUVmax (respective median values of 3.7 and 10.0; $p < 0.0001$). Surgical procedures were eluded in 56% of the patients. Real-time EBUS-TBNA should be preferred over mediastinoscopy as the first step procedure in the staging of PET mediastinal hot spots in lung cancer patients. In case of negative EBUS, surgical staging procedure should be undertaken. The addition of SUVmax cut-off may allow further refinement but needs validation.

Keywords: Endobronchial ultrasound; Lung cancer; Mediastinal lymphadenopathy; PET-scan; Staging; Transbronchial needle aspiration

1. INTRODUCTION

Staging before surgical resection of lung cancer is of paramount importance to limit the number of futile thoracotomies. In particular, patients with N2 mediastinal lymph node involvement remain poor candidates for initial surgical resection even if neoplastic invasion is limited to a single mediastinal station [1].

In the assessment of mediastinal lymph nodes, positron emission tomography with F¹⁸-fluorodeoxyglucose (FDG-PET) is more accurate than CT scan [2]. A recent consensus recommends that, in patients who are potential candidates for surgery, a whole-body FDG-PET scan should be performed to evaluate the mediastinum [3]. PET scan also provides significant additional information in the search for distant metastasis of lung cancer and is cost-effective [4]. Positive PET mediastinal lymph nodes nevertheless require histological confirmation because of possible increased FDG uptake related to non-neoplastic (mainly inflammatory) processes [2,3]. For that purpose, mediastinoscopy still remains the "gold-standard" [5]. However, this procedure has a mortality rate of 0.2% and a morbidity rate of 0.5-2.5%, and requires general anaesthesia; in addition, even if it can be performed on an ambulatory basis, many patients still stay at least one night in the hospital [6].

In this study, the diagnostic yield of a new tool, endobronchial ultrasound (EBUS) examination with real-time guided TBNA under local anaesthesia [7-9] was assessed in the staging of PET positive lymph nodes. The number of avoided surgical staging/diagnostic procedures was also evaluated. All the patients with suspected or proven lung cancers from Hôpital Saint-Pierre/Institut Bordet or referred from other hospitals to Hôpital Saint-Pierre/Institut Bordet endoscopic unit for this indication were included. As secondary aims, we also tried to assess whether the addition of a standardized uptake value (SUV, a semi-quantitative estimation of FDG uptake) cut-off to the usual simple visual (subjective) interpretation of FDG uptake in lymph nodes may allow further

¹ Present address: Respiratory Division, Hôpital du Sacré-Coeur de Montréal, 5400 Gouin Blvd W., Montreal, Quebec, Canada H4J 1C5.

refinement in patient selection [10].

2. MATERIALS AND METHODS

All the patients with suspected/proven lung cancer and FDG-PET positive lymph nodes referred to Hôpital Saint-Pierre/ Institut Bordet endoscopic unit were considered. Data were prospectively collected and retrospectively assessed. Patients had two different initial clinical presentations. In the first group (staging), the procedure was performed to stage the mediastinum in a proven lung cancer without any evidence for distant metastasis. In the second group (diagnosis and staging), patients had suspected lung cancer but the initial bronchoscopy was not contributive, and FDG-PET was abnormal on the tumour and on the mediastinum. Patients with previous chemotherapy induction treatment were excluded. Sixty-nine (65% of the study population) were referred from 26 other hospitals. All patients underwent EBUS for localization of the FDG-PET abnormal lymph nodes followed by real-time guided TBNA using the same standardized equipment and technique throughout the study period.

Forty-three patients (all the 37 patients from Hôpital Saint-Pierre/Institut Bordet and six referred patients) underwent FDG-PET scanning using the same combined PET/CT system in the leading centre (GE Discovery LS, GE Medical systems, Milwaukee, WI). Time of fasting before injection was at least 6h. Pre-injection serum glucose was normal (range 78-122 mg/dL). A fixed FDG dose of 296 MBq (8mCi) was administered 60 min before acquisition that included the trajectory from mid-thigh to mid-skull. Acquisition time was 4min at each table position. Attenuation correction used the tomodensitometry data. Image reconstruction using ordered subset expectation maximization (OSEM) was obtained with two iterations and 28 subsets after images were smoothed by a 5.45 mm FWHM Gaussian filter.

Bronchoscopy was performed using a linear-array ultrasound bronchoscope (BF TYPE-UC160F-OL8; Olympus Ltd., Tokyo, Japan) while patients were comfortably seated in a 30° recumbent position. Oxygen (2 L/min) was administered with nasal prongs, and transcutaneous hemoglobin saturation and cardiac rhythm (Ohmeda Biox 3740; Louisville, CO) were continuously monitored. Anaesthesia of the airways was performed as previously described [11] with conscious sedation using intravenous midazolam and patients were managed on an outpatient basis. The technical description of ultrasound examination and real-time guided needle aspiration of lymph nodes using 22-gauge needle has previously been described [7-9]. Colour Doppler was used as needed to avoid main vessel puncture. Identification of lymph nodes levels was performed according to the international staging system [12] and lymph nodes dimensions were also recorded. For positive PET lymph nodes areas, assessment was concentrated on N2 and/or N3 lymph nodes in case of proven lung cancer but also on positive PET N1 lymph node in case of suspected lung cancer. If accessible PET negative lymph nodes of higher staging were seen during EBUS, (e.g. N3 PET negative areas in case of N2 PET positive areas), we sampled these first in order to detect FDG-PET occult metastases. Two to seven punctures were performed in each patient, beginning with the highest staging node level if several areas were hypermetabolic on PET-scan. The aspirated material was smeared onto glass slides that were air-dried and also fixed in 70% alcohol. In addition, the catheter and needle were flushed with one millilitre of NaCl 0.9% and the material was collected for cytological examination. No rapid on-site cytological examination was used.

3. DATA ANALYSIS

For the purpose of EBUS lymph node size analysis, we considered the sampled lymph node with the largest short-axis in each patient. TBNA was considered contributive whenever a clear definite cytological or histological diagnosis was obtained. It was not contributive if no diagnosis could be reached. In these latter cases, surgical staging/diagnostic procedures (mediastinoscopy or thoracotomy with mediastinal lymph node dissection) were recommended. The sensitivity, specificity, positive predictive value, negative predictive value and accuracy were calculated using the standard definitions, excluding patients in whom surgery was not undertaken to verify non contributive TBNA results. False-positive aspirations were considered unlikely and no surgical verification was then performed [13]. In fact, the main source of false positive result is likely to be a lung tumour abutting the main tracheo-bronchial tree but none of our patients showed this condition. In fact the majority of the patients were assessed for the diagnosis and staging of peripheral tumour with mediastinal (hilar) PET positive lymph nodes and the peripheral localization also explains the low diagnostic performance of initial conventional bronchoscopy in this population. A surgical staging/diagnostic procedure was considered as eluded and therefore not performed whenever TBNA was contributive. Secondary aim included comparison of SUVmax measurements between patients with and without lymph node metastasis, using the Mann-Whitney *U*-test. These measurements were performed *a posteriori* by one experienced specialist in nuclear medicine (MD) in all the patients assessed using the same PET-CT machine from Hôpital Saint-Pierre/Institut Bordet. This specialist was

blinded to the results of EBUS-TBNA. For the purpose of analysis, the largest lymph node SUV value (SUVmax) measured in the sampled lymph node stations in each patient was used. The tomodensitometry data were used to locate the sampled lymph node stations and a region of interest was drawn encompassing the whole positive volume. SUVmax was chosen because it is less sensitive to the partial volume effect that could have a great influence on the uptake measurement of small objects. The relationship between the SUVmax value and the presence of lymph node metastasis was further analysed through a logistic regression model. ROC analysis was also performed to assess the value of SUVmax as a diagnostic technique for lymph node metastasis. No attempt was made to extend this analysis to other centres because of the known lack of standardization of SUV analysis between various PET systems.

This study included 20 patients whose results were previously published in a French journal [14].

4. RESULTS

From December 2004 to March 2007, 106 patients with suspected/proven lung cancer and positive FDG-PET mediastinal (hilar) lymph nodes were included. All patients already had a bronchoscopy for diagnostic purpose. Their main characteristics are summarized in Table 1. FDG-PET and CT scan images were always available but data on quantitative assessment including standardized uptake value (SUV) or lymph node size (CT scan) were most often missing due to non standardized initial diagnostic work-up done in 27 different centres. As previously reported, the procedure performed under local anaesthesia was well tolerated and side effects, notably cough, were seldom encountered [15]. In one patient with COPD, however, chest pain occurred during the procedure and chest X-ray confirmed a pneumothorax that required chest tube drainage. FDG-PET scan located abnormal lymph nodes in the mediastinum in 96 cases and at the hilar level only in 10 cases. EBUS localization of lymph nodes was always possible and required about 5 min, after which real-time guided TBNA was performed.

Punctured lymph nodes characteristics are showed in Table 2. A total number of 512 samples (mean number per patient: 4.9 ± 1.1) were obtained, in 188 different lymph node stations. The lymph node stations that were the most frequently explored were 4 (46% of the total number of sampled areas, 76 patients) followed by 7 (34%, 64 patients). In 18 patients, area 7 was the solely explored station. The smallest proven malignant lymph node had a short axis measuring 5 mm.

Table 1- Characteristics of the patients

Total number	106
Proven lung cancer	29
Suspected lung cancer	77
Mean pack (years)	42 ± 21
Male/female	79/27
Mean age (years)	64 ± 10
Hilar FDG-PET positive lymph nodes only	10
N2-N3 FDG-PET positive lymph nodes	96

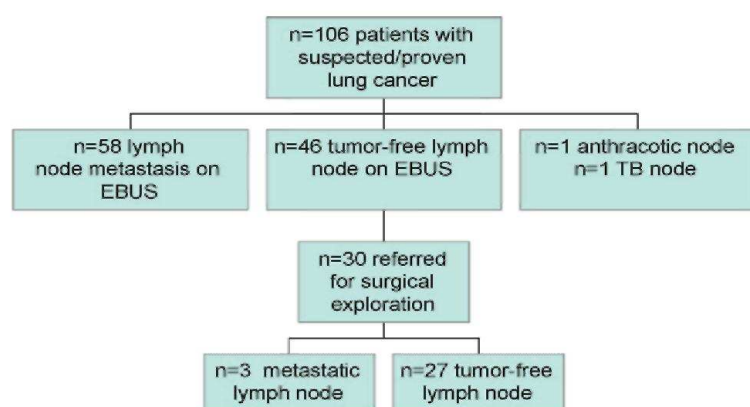
FDG-PET: 18-fluorodeoxyglucose-positron emission tomography.

Table 2- Punctured lymph nodes characteristics

Total number of samples (N)	512
Mean number of passes/patient	4.9 ± 1.1
Stations (N)	188
Distribution 7	64 (34%)
Distribution 4R	49 (26%)
Distribution 4L	37 (20%)
Distribution 11R	19 (10%)
Distribution 11L	6 (3%)
Distribution 10R	8 (4%)
Distribution 10 L	4 (2%)
Distribution 2L	1 (0.5%)
Mean diameter of the largest node in each patient (range) in mm	14.4 ± 6.7 (5.0-40.0)

Fig. 1 describes the final diagnosis in the 106 patients. EBUS-TBNA revealed lung cancer lymph node metastasis in 58 (55%) patients, including two cases of small cell carcinoma. In four of these cases, lymph node metastasis was also found in PET negative areas of higher lymph node level (2 N3 and 2 N2 confirmed cases that appeared respectively as N2 and N1 diseases on the basis of PET results). In one patient, several small biopsies showed normal lymph node tissue with anthracosis (biopsies are rarely obtained with the 22-gauge needle and the presence of lymph node tissue without neoplastic involvement was considered as a true negative result in this particular case) and in another patient, suspected tuberculosis was confirmed by pleural biopsies. If this latter debatable case is discarded, surgical intervention was eluded by the use of EBUS-TBNA in 56 % (59/106) of the patients. Thirty of the 46 patients with tumour negative EBUS findings had surgical verification that showed lymph node metastasis in three cases. In these latter cases, during EBUS, lymph nodes had been localized and biopsied in the areas that later showed metastasis during surgical exploration (area 7 in one patient, 4L in the second one and 4R in the third patient). In one case, EBUS sampling showed neither lymphocytes nor neoplastic cells suggesting inadequate sampling and in another patient, there was a 2 months delay between EBUS-TBNA and mediastinoscopy due to a major abdominal surgery. In contrast, no explanation was found for the third false negative result. In 16 patients, no surgical verification was performed because of patient refusal ($n = 5$) or loss of follow-up (two patients) or physician's decision to administer chemotherapy or radiotherapy without surgical verification ($n = 6$). In the last three cases, clinical follow-up was chosen by the referring team and was uneventful at 6 months, supporting non-neoplastic disease. The prevalence of lymph node metastasis in the whole population was 58% (61/106). Based on the 90 assessable patients, the sensitivity, specificity, positive predictive value, negative predictive value and accuracy of EBUS-TBNA for PET positive lymph node staging were 93, 100, 100, 91 and 97%.

Fig. 1- Final diagnosis of mediastinal lymph nodes. (EBUS: endobronchial ultrasound; TB: tuberculosis).



5. LYMPH NODE SUVMAX MEASUREMENT

PET-CT scan was performed in Hôpital Saint-Pierre/Institut Bordet in 43 of the 106 patients. Two cases were excluded from the analysis because no surgical verification was performed despite negative EBUS-TBNA results. Among the 41 assessable patients, lymph node metastasis was confirmed in 29 and excluded by surgical verification in 12 of them. The mean SUVmax of mediastinal lymph nodes was 9.1 ± 6.1 for the whole group but amounted to 11.1 ± 6.0 in the metastatic lymph nodes and only 4.1 ± 2.2 when no tumour was found while the median values were respectively 10.0 in positive patients and 3.7 in negative patients. Location of the SUVmax distribution was significantly associated to lymph node involvement ($p < 0.0001$). When SUVmax was analysed as a continuous variable, an increase by 1 in the SUVmax value divided by 2 the probability of being free of lymph node metastasis (OR = 0.49, 95% CI: 0.30-0.78, $p < 0.001$). The area under the ROC curve for predicting negative involvement of lymph nodes was 0.93. Using a cut-off value of 4, negative predictive value was 100 % for a sensitivity of 67%.

6. DISCUSSION

The present study shows that real-time EBUS-TBNA is a very safe and effective tool to stage patients with suspected/proven lung cancers and FDG-PET positive mediastinal lymph nodes. This technique could be performed after local anaesthesia, on an outpatient basis and was associated with a high sensitivity and accuracy. A serious complication (pneumothorax) was encountered in only one patient. It also allowed avoidance of surgical diagnostic/staging sampling in 56 % of patients. In a few patients, it also confirmed lymph node

metastasis in higher lymph node levels than that suggested by the PET scan. To that extent, this technique should be considered as a primary method of sampling in patients with suspected/proven lung cancers and FDG-PET positive mediastinal lymph nodes. If no lymph node metastases were demonstrated, further surgical sampling should still be performed due to endobronchial ultrasound's 91 % negative predictive value. The addition of SUVmax cut-off may allow further refinement but needs validation.

The study included patients from many different centres, leading to a potential selection bias. Indeed, 69 patients (65 % of the study population) were referred to the leading centre from 26 other hospitals over 28 months. This suggests that, in many centres, the criteria to refer these patients were not uniform. It is also likely that, as long as minimally invasive techniques (EBUS or EUS) were not available in these centres and evidence supporting their use was still limited, they were not considered as primary staging procedures by a varying proportion of the local chest physician and/or thoracic surgeons. This is also illustrated by the fact that very few patients were referred by thoracic surgeons. As already mentioned, surgical staging/diagnostic procedures (mediastinoscopy or thoracotomy with mediastinal lymph node dissection) were recommended whenever EBUS was not contributive but these recommendations were not always followed such that the negative predictive value of EBUS might be lower than the value reported. In addition, no attempt was made trying to standardize nodal sampling and/or dissection in the different centres. We believe however that the inclusion of all these referred patients in a study with a pragmatic approach and the encouraging results obtained in the present study strengthens the performance value of EBUS-TBNA for mediastinal staging.

Initially, EBUS lymph node localization has been performed using the ultrasonic probe technique. This probe however does not allow real-time guided TBNA. Herth and colleagues [16] have elegantly shown that this lymph node sampling technique is better than the conventional "blinded" TBNA. Recently, we have assessed the role of prior evaluation of FDG-PET positive lymph nodes using ultrasonic catheters before TBNA in patients with various clinical presentations and the overall diagnostic yield was 82 % [15]. For obvious reasons, however, the development of the new echo-bronchoscope allowing real-time guided TBNA will probably replace the indirect ultrasonic probe technique.

The performance of EBUS-TBNA in the present study was high despite the fact that no rapid on-site cytological examination was performed and lymph node size was relatively small. We believe that this is mainly explained by PET positive node selection and ultrasound guided sampling. Lymph node size has been reported to be a determinant of the diagnostic yield of blinded TBNA [17]. With real-time guided sampling, the impact of size on yield should decrease by a large amount. In fact, the mediastinal lymph node size in a given population of patients will depend mainly on the imaging diagnostic work-up. If selection is done by CT scan on the basis of lymph node short-axis >1 cm, one may expect that on the average, larger lymph nodes will be explored than when PET scan is used. Indeed, in the largest study on the staging of CT enlarged mediastinal lymph nodes using oesophageal ultrasound with fine needle aspiration, the mean size of sampled lymph nodes was 24 mm [13]. Despite differences in lymph node size and the fact that the latter study used rapid on-site cytological examination, both this latter and the present studies showed similar sensitivities and specificities of ultrasound guided sampling in the context of similar prevalence of lymph node metastasis.

Surprisingly, the prevalence of lymph node metastasis was relatively low (58 %) in this population of patients with PET positive lymph nodes. Several factors may contribute to the high-rate of "false positive PET". First, the study included a majority (73 %) of patients with not yet proven lung cancers. This factor increases the probability of finding non-neoplastic disorders (e.g. chronic infectious diseases including tuberculosis). Second, the semi-quantitative analysis (SUVmax) of PET hot spots done *a posteriori* in the 41 patients explored in a single institution (Hôpital Saint-Pierre/Institut Bordet), has shown that lymph nodes without metastasis had a significantly lower SUV than those with metastasis (median of 3.7 versus 10.0). If distinction between malignant and benign lymph nodes had been based on semi-quantitative assessment with as threshold, as an example, the best one (4.4) reported in a previous study [10], 8 of the 12 patients without lymph node metastasis would not have been referred for EBUS and our negative predictive value would have been 96 %. Such semi-quantitative measurements, however, are not routinely performed and still require between-centres (and various PET-CT machines) validation. Further, our sample size was quite small with only 12 negative patients leading to large confidence intervals when assessing the characteristics of any diagnostic rule despite an area under the ROC being quite interesting. Anyway, proposing a threshold for diagnosis purposes, at the present stage, is quite difficult as any threshold would have been to be validated in each institution before allowing its use in clinical practice. A potential explanation for the relatively high rate of false positive initial visual reading performed by well-trained PET specialist is related to the introduction of integrated PET-CT scans. Even if the visual analysis suggest moderate FDG uptake, fusion of PET and CT images, provided they confirm that the uptake is located within a lymph node, may lead to the decision to consider the lymph node as a suspicious one.

EBUS allowed to elude 56 % of the required surgical verification of PET positive mediastinal lymph nodes. These results are in accordance with previous studies showing that esophageal endoscopic ultrasound (EUS) with fine needle aspiration (FNA) in lung cancer patients with mediastinal and/or upper retroperitoneal FDG-PET hot spots in fact decreased by 62 % the number of surgical staging procedures and saved 40 % of staging costs [18].

Several studies have assessed the use of EUS-FNA in the evaluation of mediastinal hot spots [19,20]. No study has compared EBUS-TBNA with EUS-FNA in this particular indication and these techniques in fact appear more complementary than exclusive [21]. EBUS provides access to the same lymph nodes as mediastinoscopy (with even easier access to left lower paratracheal area, below the aorta and the posterior subcarinal area) whereas EUS allows visualization and access to lymph nodes close to the oesophagus, including the left paratracheal area, the aortopulmonary window, the subcarinal area and the posterior mediastinum. In our center, EBUS-TBNA is preferred over mediastinoscopy as the first staging procedure and EUS is reserved for exploration of lymph nodes that are located in the aortopulmonary window or in the lower mediastinum.

This initial non-surgical approach is also interesting in the present context of multi-modal treatment. Provided N2 disease is confirmed by initial EBUS (or EUS) sampling, restaging after the induction treatment that is of paramount importance to assess the important prognostic factor that is downstaging [22-25], might then be performed with mediastinoscopy. On the opposite, following initial staging with mediastinoscopy, remediastinoscopy is a difficult surgery performed by a limited number of thoracic surgeons [26,27]. Furthermore, although ultrasound guided needle aspiration may allow confirmation of the persistence of lymph node metastasis, it is not well suited to give a precise staging information such as single versus multiple level N2 disease or presence of extracapsular disease that will be considered as a clear contra-indication to surgical resection.

In summary, in patients with suspected/ proven lung cancer and FDG-PET positive mediastinal lymph nodes, EBUS-TBNA allowed to assess lymph node metastasis with a high sensitivity and accuracy. It also permitted sparing of a majority of surgical procedures. In case of negative EBUS, surgical staging procedure should be undertaken. The addition of SUVmax cut-off may allow further refinement but validation is required.

CONFLICTS OF INTEREST

None

References

- [1] Ohta Y, Shimizu Y, Minato H, Matsumoto I, Oda M, Watanabe G, et al. Results of initial operations in non-small cell lung cancer patients with single-level N2 disease. *Ann Thorac Surg* 2006;81:427-33.
- [2] Gould MK, Kuschner WG, Rydzak CE, Maclean CC, Demas AN, Shigemitsu H, et al. Test performance of positron emission tomography and computed tomography for mediastinal staging in patients with non-small-cell lung cancer: a meta-analysis. *Ann Intern Med* 2003;139:879-92.
- [3] Silvestri GA, Tanoue LT, Margolis ML, Barker J, Detterbeck F, American College of Chest Physicians. The noninvasive staging of non-small cell lung cancer: the guidelines. *Chest* 2003;123:147S-56S.
- [4] van Tinteren H, Hoekstra OS, Smit EF, van den Bergh JH, Schreurs AJ, Stallaert RA, et al. Effectiveness of positron emission tomography in the preoperative assessment of patients with suspected non-small-cell lung cancer: the PLUS multicentre randomised trial. *Lancet* 2002;359:1388-93.
- [5] Toloza EM, Harpole L, Detterbeck F, McCrory DC. Invasive staging of non-small cell lung cancer: a review of the current evidence. *Chest* 2003;123:157S-66S.
- [6] Luke WP, Pearson FG, Todd TRJ. Prospective evaluation of mediastinoscopy. *J Thor Cardiovasc Surg* 1986;91:53-6.
- [7] Krasnik M, Vilman P, Larsen SS, Jacobsen GK. Preliminary experience with a new method of endoscopic transbronchial real time ultrasound guided biopsy for diagnosis of mediastinal and hilar lesions. *Thorax* 2003;58:1083-6.
- [8] Yasufuku K, Chiyo M, Sekine Y, Chhajed PN, Shibuya K, Iizasa T, et al. Real-time endobronchial ultrasound-guided trans-bronchial needle aspiration of mediastinal and hilar lymph nodes. *Chest* 2004;126:122-8.

- [9] Rintoul RC, Skwarski KM, Murchison JT, Wallace WA, Walker WS, Penman ID. Endobronchial and endoscopic ultrasound-guided real-time fine-needle aspiration for mediastinal staging. *Eur Respir J* 2005;25:416-21.
- [10] Vansteenkiste JF, Stroobants SG, De Leyn PR, Dupont PJ, Bogaert J, Maes A, et al. Lymph node staging in non-small cell lung cancer with FDG-PET scan: a prospective study on 690 lymph node stations from 68 patients. *J Clin Oncol* 1998;16:2142-9.
- [11] Vermylen P, Pierard P, Roufousse C, Bosschaerts T, Verhest A, Sculier JP, et al. Detection of bronchial preneoplastic lesions and early lung cancer with fluorescence bronchoscopy: a study about its ambulatory feasibility under local anesthesia. *Lung Cancer* 1999;25:161-8.
- [12] Mountain CF, Dresler CM. Regional lymph node classification for lung cancer staging. *Chest* 1997;111:1718-23.
- [13] Annema JT, Versteegh MI, Veselic M, Voigt P, Rabe KF. Endoscopic ultrasound-guided fine-needle aspiration in the diagnosis and staging of lung cancer and its impact on surgical staging. *J Clin Oncol* 2005;23:8357-61.
- [14] Faber J, Pierard P, Prigogine T, Dusart M, Haller A, Bosschaerts T, et al. Endobronchial ultrasound and PET positive nodes in bronchial carcinoma. *Rev Mai Respir* 2006;23(1):37-42.
- [15] Plat G, Pierard P, Haller A, Hutsebaut J, Faber J, Dusart M, et al. Endobronchial ultrasound and PET positive mediastinal lymph nodes. *Eur Respir J* 2006;27:276-361.
- [16] Herth F, Becker HD, Ernst A. Conventional vs. endobronchial ultrasound-guided transbronchial needle aspiration: a randomized trial. *Chest* 2004;125:322-5.
- [17] Harrow EM, Abi-Saleh W, Blum J, Harkin T, Gasparini S, Addrizzo-Harris DJ, et al. The utility of transbronchial needle aspiration in the staging of bronchogenic carcinoma. *Am J Respir Crit Care Med* 2000;161 (2 Pt 1):601-7.
- [18] Kramer H, van Putten JWG, Post WJ, van Dullemen HM, Bon-gaerts AHH, Pruijm J, et al. Oesophageal endoscopic ultrasound with fine needle aspiration improves and simplifies the staging of lung cancer. *Thorax* 2004;59:596-601.
- [19] Annema JT, Hoekstra OS, Smit EF, Veselic M, Versteegh MIM, Rabe KF. Towards a minimally invasive staging strategy in NSCLC: analysis of PET positive mediastinal lesions by EUS-FNA. *Lung Cancer* 2004;44:53-60.
- [20] Eloubeidi MA, Cerfolio RJ, Chen VK, Desmond R, Syed S, Ojha B. Endoscopic ultrasound-guided fine needle aspiration of mediastinal lymph node in patients with suspected lung cancer after positron emission tomography and computed tomography scans. *Ann Thorac Surg* 2005;79(1):263-8.
- [21] Herth FJ, Lunn W, Eberhardt R, Becker HD, Ernst A. Transbronchial versus transesophageal ultrasound-guided aspiration of enlarged mediastinal lymph nodes. *Am J Respir Crit Care Med* 2005;171:1164-7.
- [22] Bueno R, Richards WG, Swanson SJ, Jaklitsch MT, Lukanich JM, Mentzer SJ, et al. Nodal stage after induction therapy for stage IIIA lung cancer determines patient survival. *Ann Thorac Surg* 2000;70:1826-31.
- [23] Voltolini L, Luzzi L, Ghiribelli C, Paladini P, Di Bisceglie M, Gotti G. Results of induction chemotherapy followed by surgical resection in patients with stage IIIA (N2) non-small cell lung cancer: the importance of the nodal down-staging after chemotherapy. *Eur J Cardiothorac Surg* 2001;20:1106-12.
- [24] Sawabata N, Keller SM, Matsumura A, Kawashima O, Hirono T, Osaka Y, et al. The impact of residual multi-level N2 disease after induction therapy for non-small cell lung cancer. *Lung Cancer* 2003;42:69-78.
- [25] Betticher DC, HSU Schmitz SF, Totsch M, Hansen E, Joss C, von Briel C, et al. Mediastinal lymph node clearance after docetaxel-cisplatin neoadjuvant chemotherapy is prognostic of survival in patients with stage IIIA pN2 non-small cell lung cancer: a multicenter phase II trial. *J Clin Oncol* 2003;21(9):1752-9.
- [26] Mateu-Navarro M, Rami-Porta R, Bastus-Piulats R, Cirera-Nogueras L, Gonzalez-Pont G. Remediastinoscopy after induction chemotherapy in non-small cell lung cancer. *Ann Thorac Surg* 2000;70:391-5.
- [27] Van Schil P, van der School J, Poniewierski J. Remediastinoscopy after neoadjuvant therapy for non-small cell lung cancer. *Lung Cancer* 2002;37:281-5.