

Treatment of Urological Complications Related to Aorto-iliac Pathology and Surgery

P. Bonnet,¹ C. Vandenberg² and R. Limet^{3*}

Departments of ¹Anatomy and Urology, ²Urology, ³Cardiovascular and Thoracic Surgery, Centre Hospitalier Universitaire de Liège, Domaine du Sart-Tilman, 4000 Liege 1, Belgium

Objectives. Proximity of ureters with iliac arteries makes them prone to damage by aorto-iliac pathology or surgery. The aim of this retrospective study is to analyse the incidence, the predisposing factors, and the optimal treatment of ureteral stenosis (US) or leakages (UL).

Design. Retrospective study.

Material. Fiftyone ureteral lesions in 41 patients referred to the urologist in a fourteen years period in the same institution.

Methods. Lesions are classified in three groups: A, preoperative; B, less than 3 months postoperatively; and C, more than 3 months postoperatively. Group A comprises 10 abdominal aortic aneurysm (AAA) patients; eight of the AAA are of the inflammatory type. Group B comprises 16 patients, 11 US and 9 UL. Group C comprises 15 patients and 15 US.

Results. Endoureteral treatment was successful in most of the group B patients. Some of them, however, had to be submitted to secondary open surgery, so that the global success rate is 70% in group B. In group C, the response is poor following endourological treatment alone (12.5% success) and open surgery is more often needed (3 ureterolyses and 1 nephrectomy). Global success rate is 40%.

Conclusion. Early diagnosis is associated to better results with less invasive procedure; late diagnosis is accompanied by a lower success rate of endourological treatment and requires more often primary open surgery.

Key Words: Abdominal aortic aneurysm; Inflammatory abdominal aortic aneurysm; Ureterolysis; Percutaneous nephrostomies; Urovascular fistula; Endoureteral catheter; Vascular prosthesis infection.

Introduction

Ureteral iatrogenic lesions encountered by urologists correspond in the first instance to cases of their own speciality and then to those derived from abdominal and gynaecological surgery.¹⁻³ At last, very few derive from vascular surgery.⁴⁻⁶ Ureteral lesions from vascular surgery would account for 0.8% of lesions recognised at time of surgery and 2.2% of complications observed later.⁷ According to others,⁸ vascular surgery would be responsible for 6.1% of iatrogenic lesions. Though infrequent, they can be extremely serious. Ureteral lesions from aorto-iliac pathology are not all iatrogenic; some may be present prior to the surgical procedure. They are related to the aneurysmal form of the aortic pathology.⁹ Moreover, besides lesions arising at time of surgery from iatrogenic accidents, some are developing from inflammatory

secondary reactions. The aim of this One Centre retrospective study is to analyse the occurrence rate of ureteral lesions, the predisposing factors, the modalities of the diagnosis, and the results of applied therapies, so that one can define an optimal treatment policy.

Material and methods

During a period of fourteen years, from 01/04/1986 to 01/04/2000, we encountered 41 vascular patients presenting, prior or post-aorto-iliac surgery, a uni- ($n = 31$) or bilateral ($n = 10$) ureteral problem, thus a total of 51 ureters. There were 31 men and 10 women, with a mean age of 70.5 years for men and 60.5 years for women. During the same period, 2297 patients underwent an aorto-iliac operation, either for an obstructive pathology ($n = 1159$), or for an aneurysmal pathology ($n = 1132$). The aneurysm group includes 40 inflammatory type aneurysms. The incidence of ureteral lesions (uni- or bilateral) observed is 1.8%

*Corresponding author. R. Limet, Department of Cardiovascular and Thoracic Surgery, Centre Hospitalier Universitaire de Liège, Domaine du Sart-Tilman, 4000 Liege 1, Belgium.

(41/2297). If we subtract the 10 patients with preoperative ureteral lesions, the occurrence rate falls to 1.3% (31/2287).

The series is analysed in three groups defined by the timing of occurrence of the urological problem: group A (lesions observed in the preoperative period), group B (lesions observed at the time of operation or in the early postoperative period (less than 3 months)) and group C (lesions observed late postoperatively (more than 3 months)).

Results

Type of lesions

The lesions are either pure ureteral stenoses (US) ($n = 42$) or urinary leakage (UL) ($n = 9$). Group A has 16 US in 10 patients; group B has 11 US and 9 UL in sixteen patients, and group C 15 patients and 15 US. The preoperative ureteral pathology appears in patients with aneurysm pathology only (10/10); the postoperative ureteral lesions appeared after surgery for aneurysm in 17 patients (17/1122, 1.5%) and after surgery for obstructive aorto-iliac lesions in 14 patients (14/1159, 1.2%).

Topography of ureteral lesions

The stenotic lesions (US) sit in the lumbar region in seven cases out of 42 (16.6%): three on the right and four on the left (Table 1). Five of the lumbar US are present in the preoperative period (group A) and are seen as part of aneurysm pathology (inflammatory, $n = 3$ or non-inflammatory, $n = 2$). Two other lumbar US occur late (group C) after surgery, one because of periprostheses fibrosis, and the other because of development of a false aneurysm on the upper aortic suture squeezing the ureteral paths (Fig. 1).

The other US ($n = 35$) are situated in the pelvic area. UL ($n = 9$) are found only in pelvic area.

Table 1. Topography of the ureteral lesions.

	Lumbar	Pelvic
Group A	5	11
Group B		
US	0	11
UL	0	9
Group C	2	13
Total	7	44

US, stenosis; UL, leakage.

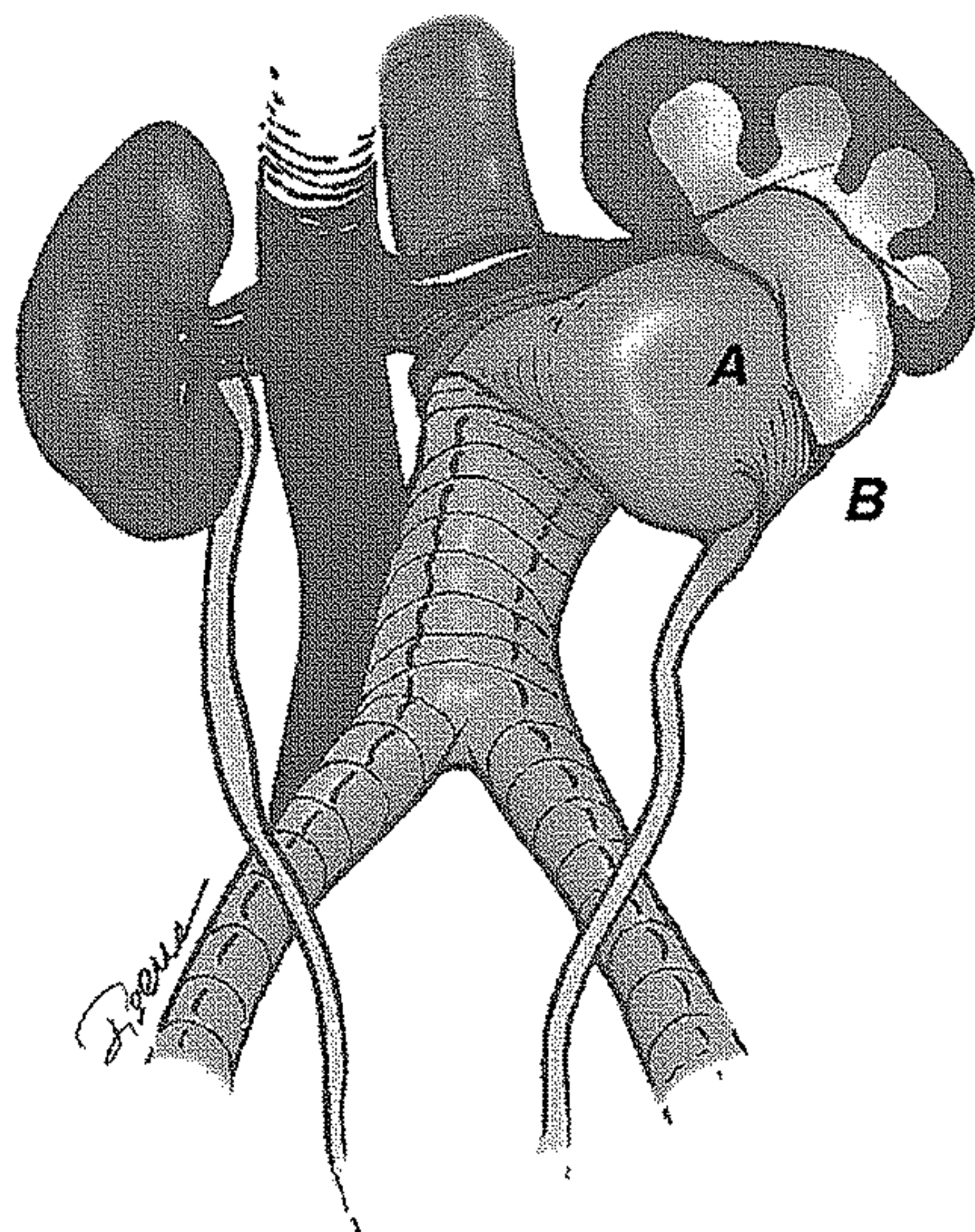


Fig. 1. Compression of left lumbar ureter (B) by the pseudoaneurysm (A) arising from the upper aortic anastomosis.

Diagnosis

Diagnosis is established differently in the 3 groups.

In group A, either uretero-hydronephrosis is observed on the CT-Scan performed for evaluation of a known aneurysm ($n = 7$) or, on the contrary, an aneurysm is observed during evaluation of uretero-hydronephrosis referred to the urologist ($n = 3$).

In group B, only one UL is recognised at the time of operation. In the eight other cases, either pyrexia ($n = 5$), ileus ($n = 1$) or/and urine found in a drainage catheter ($n = 8$) leads to diagnosis. In the US cases, creatinine increase is the diagnostic clue once only (one patient, two ureters). In the other cases, the ureteral problem is suspected on ultrasound performed for a variety of problems (six patients, nine ureters).

In group C, the late US are observed either at the time of a control radiographic exam ($n = 8$), or because of renal insufficiency ($n = 6$), or of haematuria ($n = 1$).

Factors predisposing to ureteral lesion

Inflammatory aneurysm

The preoperative lesions (10) are all related to the presence of an abdominal aortic aneurysm (AAA).

Eight AAA out of 10 were inflammatory. In a total of 40 inflammatory AAA, this represents a 20% prevalence rate (8/40) vs. 0.2% (2/1092) in patients with a non-inflammatory AAA ($p < 0.0001$) (*Chi square test*) (Table 2).

History of previous surgery

Among 2297 operated patients, 10 have a ureteral lesion prior to surgery, 2287 do not. Among these, 90 (4.1%) already have had a vascular operation at the same anatomic site. Eleven of these 90 patients have a pre- or postoperative ureteral problems (12.2%); among them, eight post-surgery for obstructive atherosclerosis and three for aneurysm surgery. On the contrary, in the population with no previous surgery at this anatomic site ($n = 2197$), 20 patients, only, demonstrate a pre- or postoperative ureteral problems (0.9%) ($p < 0.0001$) (*Chi square test*) (Table 2).

Prosthesis infection

Three patients with ureteral problems have infection of their arterial prosthesis. The total number of patients affected with infection of the prosthesis (other than these isolated at the groin) account for 18 patients; therefore, the prevalence of ureteral lesions is 3/18 (16.6%) vs. 1.2% in not apparently infected grafts ($p < 0.001$) (*Chi square test*) (Table 2).

Prosthesis malposition

In four cases, stenosis is accompanied by incorrect position of the prosthesis, which is situated in front of the ureter (these four cases are treated by ureterolysis and repositioning of the ureters, by severing and reanastomosing the vascular prosthesis). Prosthesis malposition is observed after repair of AAA in two cases and after reconstruction for obstructive vascular disease in two cases.

Treatment modalities and results

Therapeutic policies applied in the three groups appear in Table 3.

- Percutaneous nephrostomy ($n = 6$), double JJ-pigtail

catheter ($n = 23$) and combined nephrostomy and pigtail catheter ($n = 7$).

- Treatment by *open surgery*: nephrectomy (primary $n = 4$ or secondary $n = 1$), ureterolysis with or without ureteral resection (primary ureterolysis, $n = 7$, secondary ureterolysis, $n = 10$). Four ureterolyses are associated with uncrossing of a vascular prosthesis.
- Surgical abstention if the kidney has no function ($n = 2$) or in minor cases ($n = 2$).

Group A (10 patients, 16 ureteral lesions). Five nephrostomies and nine JJ-stents are placed at the time of surgery and one primary ureterolysis is performed during the vascular intervention. Among these five nephrostomies, one secondary ureterolysis is thereafter necessary. Among the nine JJ ureteral stented US, two secondary ureterolyses are performed. There is no nephrectomy in this group and one patient needs nothing but a short preoperative corticosteroid therapy. In the long term, out of these 16 renal units, 11 are preserved (69%), three demonstrate chronic renal stasis (19%) and two have no remaining function (12%) (Tables 3 and 4).

Group B (16 patients, 20 ureteral lesions hence, 11 US (7 patients) and nine UL (9 patients)). The 11 US are treated by corticosteroid therapy ($n = 1$), primary ureterolysis ($n = 3$) and JJ-stenting ($n = 7$). In the seven patients initially treated by JJ-stenting (one associated with nephrostomy), three secondary open ureterolyses are necessary (3/7). Also prolonged pigtail, more than six months, in two patients is responsible for one uretero-prosthetic fistula and one uretero-arterial (retrogradely perfused iliac aneurysm) (Fig. 2). The nine UL are treated as follows: two primary nephrectomies and seven endoureteral catheters (four associated with percutaneous nephrostomy drainage). Among the four patients primarily treated with a JJ-stent and percutaneous nephrostomy, secondary ureterolysis is necessary in only one patient.

In the long term follow-up, a third renal unit loses all its function, hence a total loss of three renal units (15%) (one US, two UL). Three chronic pyelo-caliceal chronic stenoses develop after US (15%). In the whole, 14 renal units (70%) are preserved with normal function (Table 4). Success rate of early endoureteral

Table 2. Predisposing factors. Incidence is calculated per patient. Cohorts are all AAA (1132) and 10 patients preoperatively affected. Cohorts for previous surgery and prosthesis infection comprise all patients from AAA and AOD (aortic occlusive disease), i.e. 2297 minus the 10 patients preoperatively affected (2297 - 10 = 2287).

Patient factor	Cohort	Yes	No	<i>p</i> value
Inflammatory type (10 patient preop)	1132 AAA	8/40 (20%)	2/1092 (0.2%)	<0.0001
Previous surgery (31 patients)	2297 AAA + AOD - 10 = 2287	11/90 (12.2%)	20/2197 (0.9%)	<0.001
Prosthesis infection (31 patients)	2297 AAA + AOD - 10 = 2287	3/18 (16.6%)	28/2269 (1.2%)	<0.0001

Table 3. Description of treatment and timing.

	Abstention	Steroids	Nephrostomy	JJ-pigtail	Ureterolysis		Nephrectomy		Urovascular fistula
					Primary	Secondary	Primary	Secondary	
Group A n patients = 10 n ureters = 16	0	1	5	9	1	3*	0		
Group B Stenosis: 11 n patients = 16 n ureters = 20	0 0	1	(1†) (4†)	7 7	0	3* 1*	0 2		2
Wounds: 9 Group C n patients = 15 n ureters = 15	2	0	1 (2†)	7	3	3*	2	1*	
Total n patients = 41 n ureters = 51	2	2	6 (7†)	30	7	10*	4	1*	2

*Secondary.

†Associated with JJ-pigtail.

treatment alone is 2/7 (29%) in US and 6/7 (86%) in UL.

Group C (15 patients, 15 US) are treated as follows: therapeutic abstention ($n = 2$), open surgery ($n = 5$) for two nephrectomies and three ureterolyses, percutaneous nephrostomies ($n = 1$), endoscopic treatment by JJ-stents ($n = 7$) with two associated percutaneous nephrostomies. Three out of seven pigtail catheters necessitate secondary ureterolysis. One isolated percutaneous nephrostomy is followed by secondary nephrectomy. One of the three primary ureterolyses is associated with the resection of false aneurysm of the subrenal aortic-prosthesis suture (Fig. 1). In total, five nephronic units were lost before or shortly after treatment; in the long term, two more nephronic units are lost, hence a total of seven kidneys is lost out of 15 (47%); two chronic stases are observed (13%), so that only six nephronic units (40%) are preserved and well functioning (Table 4). Endourological treatment ($n = 8$) necessitates four more open treatments (one nephrectomy, three ureterolyses) with only one final success, so that the success rate of endourological treatment alone is 12.5% in group C.

Discussion

There were 44 *iliac* lesions vs. 7 *lumbar*; this iliac segment vulnerability is due to the fact that the iliac vessels are almost inevitably dissected during reconstructive surgery. The role of the *inflammatory aneurysm* pathology in the development of preoperative US is prompted by the fact that, on a total of 40 inflammatory AAA, there are eight patients presenting US (20%) vs. two patients in the remaining 1092 non-inflammatory aortic aneurysms (0.2%). The presence of hydronephrosis at the time of aneurysm diagnosis must lead to suspicion of an inflammatory type. Surgery, itself, is more difficult in inflammatory AAA, resulting in the occurrence of two malpositions of the prosthesis. Ureteral lesions may be caused by careless surgery (perforation, transection), but also by ischemia (section of vascular feeding branches, extensive coagulation), which explains that UL may not be immediate. Lately, compression (aortic pseudo-aneurysm) or fibrosis are other mechanisms.

Any redo operation at the site of *previous surgery* carries an increased risk: the anatomic positioning of

Table 4. Long-term results.

	Kidneys lost (nephrectomy or non functionary)	Chronic stasis	Success
Group A $n = 16$	2 (12%)	3 (19%)	11 (69%)
Group B $n = 20$	3 (15%)	3 (15%)	14 (70%)
US ($n = 11$)	1	3	7 (64%)
UL ($n = 9$)	2	0	7 (78%)
Group C $n = 15$	7 (47%)	2 (13%)	6 (40%)
Total $n = 51$	12 (23.5%)	8 (16%)	31 (61%)

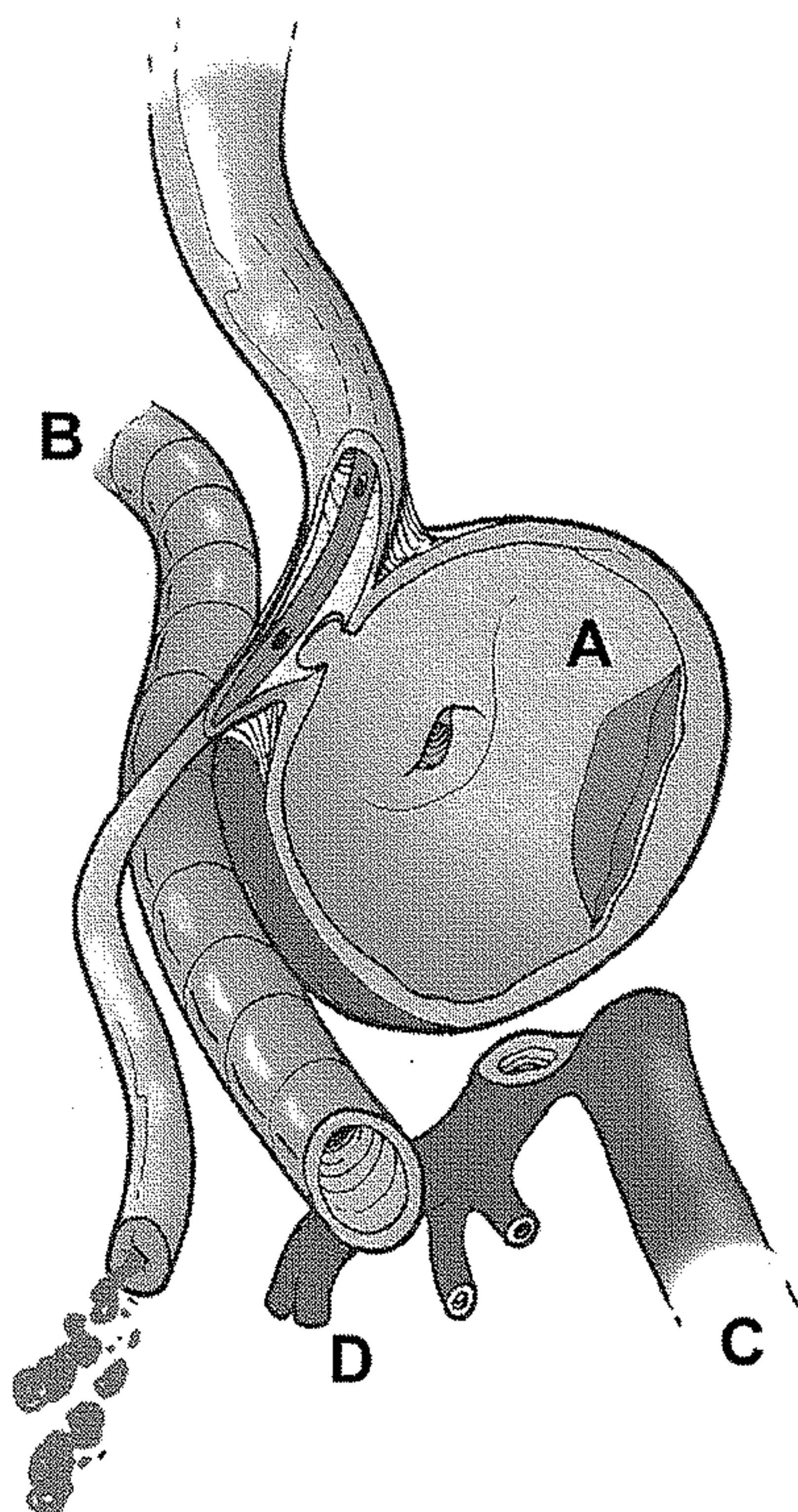


Fig. 2. Uro-vascular fistula with retrogradely perfused common iliac aneurysm. A, common iliac aneurysm; B, limb of iliac vascular prosthesis; C, external iliac artery; D, internal iliac artery.²⁷

the ureter may be modified, its vascularisation may be already made more vulnerable and dissection is made more difficult by previous scarring. This well known fact is again demonstrated in this series; ureteral complications rate after redo surgery is 12.2% vs. a 0.9% rate in patients not previously operated on.

Early postoperative hydronephrosis rate has a wide range of incidence rate in literature: from 0.1 to 0.85%,¹⁰ 10%,¹³ 2 to 20%.¹⁴ Usually, the evolution is spontaneously benign at the end of first 3 months.^{3,13} Therefore, the actual occurrence rate of silent postoperative hydronephrosis is not evaluated by clinical series that take into account only the cases referred to the Department of Urology, while the presence of

hydronephrosis was not systematically searched for. It is clear that many US can be asymptomatic. Systematic search of silent urologic complications was beyond the scope of this retrospective study and only a few prospective and limited series had addressed this issue.^{15,16}

Therapeutic options and results

The treatment aiming to restore the urinary tract continuity and preserve kidney function, the therapeutic choice is made taking into account the type of lesion, time of occurrence, function of the related kidney, and patient status. Most ureteral problems can benefit of improvements in the field of endo-urology (smaller calibre drains and endoscopes). The endoscopic treatment of stenosis (US) or ureteral leakage (UL) is known for 60 years.¹⁷ Ureteral lesions and pyelo-ureteral lesions are commonly treated using the internal route.¹⁸⁻²⁰ The endoscopic approach is nowadays recognized as first line treatment of most ureteral trauma.^{21,22} Percutaneous renal drainage under ultrasonic guidance allows effective drainage of the pyelum; JJ-stents placed endoscopically, apart from drainage, also assure correct alignment of the ureter during the healing process. Combination of internal drainage and nephrostomy appeared to be effective in the treatment of ureteral fistula: the JJ-stent guides ureteral healing whilst the nephrostomy enforces drying out of the ureteral leakage which would be only imperfectly obtained with an isolated internal drainage (Fig. 3). Thus, percutaneous drainage is also a useful tool for first line treatment. Placement of the catheter under local anaesthesia and under ultrasonic guidance is only slightly invasive and especially suitable in early follow-up of a major abdominal surgery operation. Transitory nephrostomy is placed at time of initial vascular intervention in one third of patients with preoperative uretero-hydronephrosis; this aims at improving renal function and not treating the stenotic lesion. Preoperative JJ-stent used in 9 ureters is also proposed to facilitate its identification during surgery, but efficacy of preventive drainage as in other types of surgery (rectal surgery for instance) is not proved to date.^{8,11}

Pigtail catheters have been widely used, but request secondary ureterolyses in the third (9/30) of the patients (Table 3). The need for secondary ureterolysis minimal in group A (2/9) and in group B UL (1/7), increases in group B US (3/7) and group C (3/7). But most importantly, after more than six months of drainage, two urgent urovascular surgeries are necessary, due to the occurrence of a uretero-prosthesis or

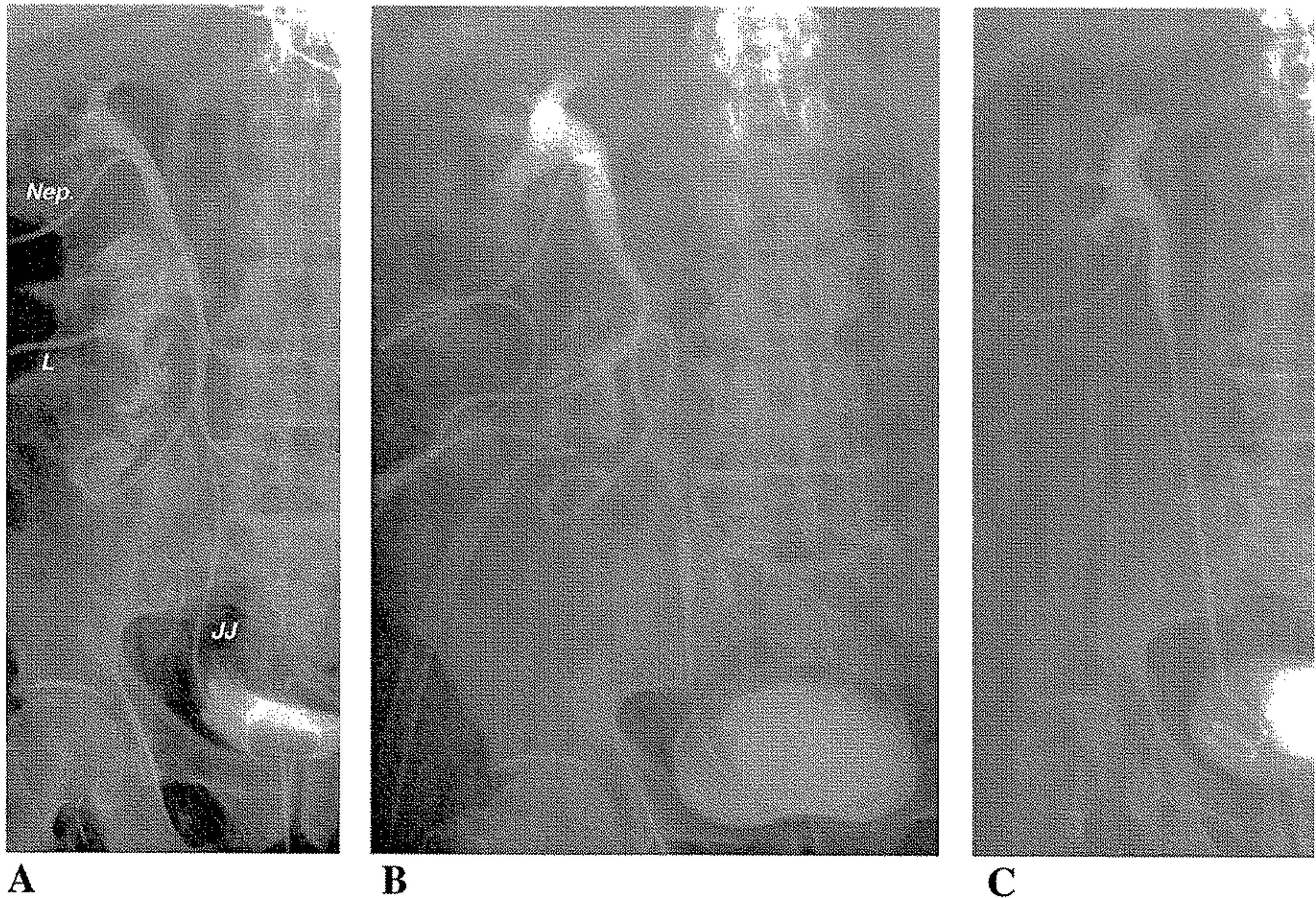


Fig. 3. Descending pyelography through nephrostomy tube evidences: (A) Ureteral leakage (UL) of left ureter immediately treated by JJ-pigtail (JJ) and percutaneous nephrostomy (NEP). (B) Two weeks later. (C) Complete healing at six weeks.

uretero-arterial fistula (Table 3 and Fig. 2). To prevent this life-threatening condition,²³⁻²⁸ we limit, now, the time of JJ drainage. It has been reported that the drainage period after endopyelotomy or ureteral incision could be limited to one week,²⁹ but this length may be too short and we suggest however that a 3-week drainage should be sufficient enough to obtain correct healing. Out of seven endourological treated UL in group B, secondary ureterolysis is needed in one case only; UL are clearly the best responder to endourological treatment.

Open surgery has been chosen either as first line primary treatment in some instances or as secondary treatment after failure of endosurgery. These surgical interventions consisted of ureterolysis, nephrectomy and uncrossing of the urinary and vascular prosthesis axes. Primarily ureterolysis is performed in long US or in combination with prosthesis malposition. Secondary ureterolysis is performed after failure of endourological treatment. Primary or secondary nephrectomy is done if pyeloureteral damage is too important to permit direct reconstruction. Short delay

treatment occurring prior to the formation of scar tissue and endoureteral approach avoids further devascularisation by undue dissection. Endourological treatment should then be recommended as the primary therapeutic choice.

Table 4 analyses long-term overall results in the three groups. Preservation of a nephronic unit without stasis is quoted as success. We observe a 69, 70 and 40% success rate from groups A, B, and C. Prevalence of chronic renal stasis, with basically preserved function, is 19, 15 and 13% in groups A, B, and C. There are 12, 15 and 47% lost kidneys in groups A, B and C. These data confirm that the longer the delay for diagnosis and treatment, the worse the results of treatment, either with endo-ureteral or open surgery, or both. Early recognition of the ureteral lesions is the key element in the success of treatment. Besides in group B, better results are observed in treatment of UL than in treatment of US. (78% vs. 64%).

As derived from the reported experience, our current attitude for early or late ureteral lesions is illustrated in Fig. 4. When facing early postoperative

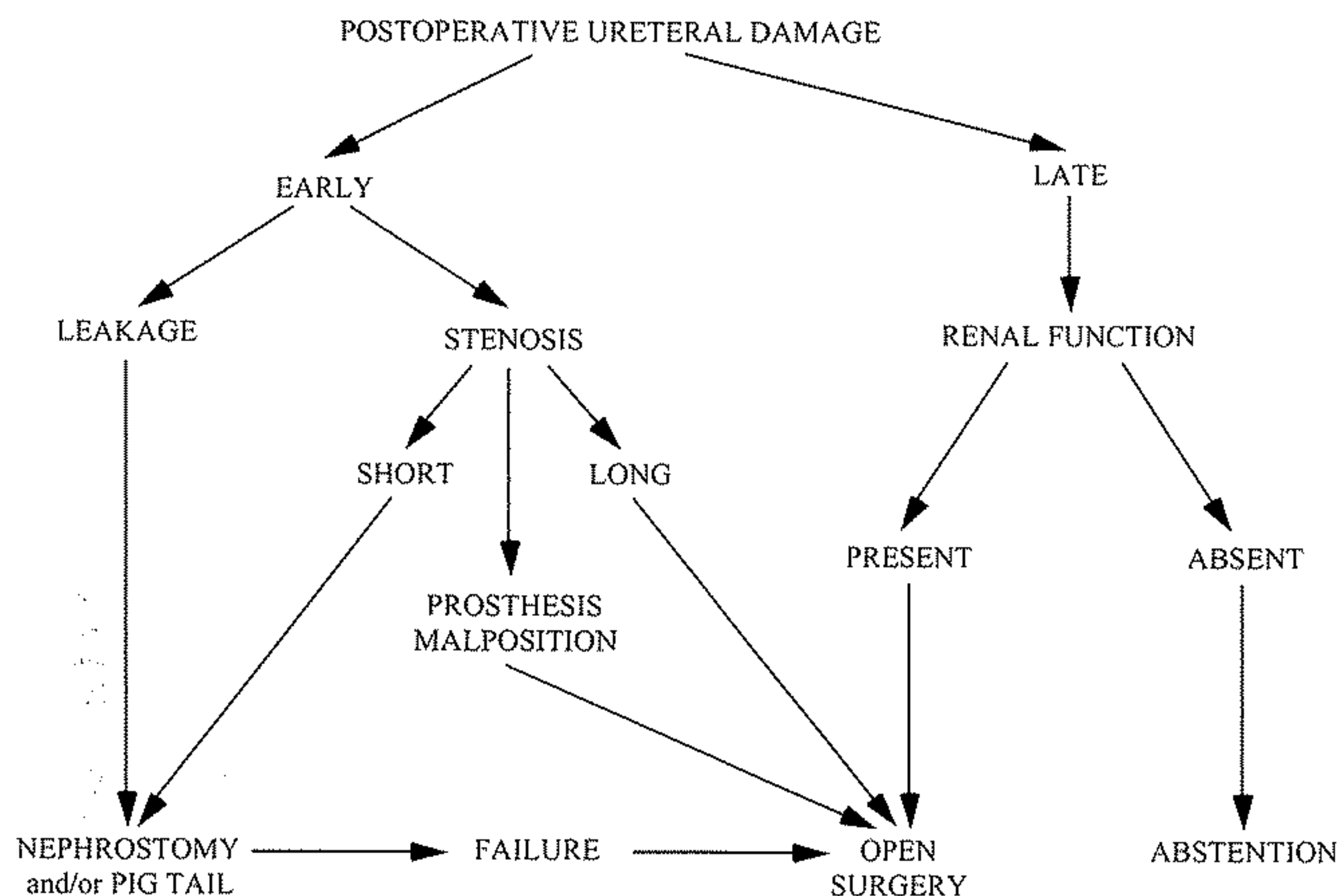


Fig. 4. Decision algorithm (see text).

lesions, if the arterial prosthesis is incorrectly positioned, if the stenosis is long, we choose open surgery as our first step treatment. If early stenosis is short and without prosthesis malfunction, and in every case of ureteral wound leading to UL, we opt for the endoscopic approach with nephrostomy and/or placement of a JJ-stent. A 10–15 days drainage with nephrostomy allows for complete drying out of the urinary fistula and for early stage ureteral healing. Thereafter, it will be completed by the internal drainage of the JJ-stent for no more than three weeks. For US lately diagnosed, we check first the functional status of the related kidney; if function is correct, we proceed to open surgery with no trial of endourological treatment.

Conclusion

This analysis of 51 ureteral lesions encountered during 14 years of aorto-iliac pathology evaluation and treatment enables us to further grasp many facts regarding causative mechanisms and treatment possibilities. The ureteral lesions in the aorto-iliac pathology either occur as part of the vascular pathology process or are of the iatrogenic type. In the first case, the specific urological treatment aims at re-establishing an optimal renal function. The endo-urological treatment is especially efficient in these indications. In post-surgical cases, the frequency of the iatrogenic

lesions will be decreased by a better understanding of the ureteral anatomy and, particularly, of ureteral vascularisation. Special attention needs to be given to operations carried out in multioperated anatomical sites, which carry a higher risk of ureteral trauma. A rapid diagnosis of every lesion improves the prognosis of the ureteral reconstruction, whatever the technique chosen.

Acknowledgements

The authors thanks Mrs Jacqueline Dehousse for her secretarial assistance. Original illustrations of this article have been drawn by first author, P. Bonnet.

References

- 1 BENNANI S, ABOUTAIEB R, EL MRINI M, BENJELLOUN S. Traumatismes de l'uretère: à propos de 29 cas. *J Urol (Paris)* 1994; **100**: 239–247.
- 2 JANKNEGT RA. Reconstruction of the ureter. *Prog Clin Biol Res* 1991; **370**: 37–46.
- 3 SELZMAN AA, SPIRNAK JP. Iatrogenic ureteral injuries: a 20-year experience in treating 165 injuries. *J Urol (Paris)* 1996; **155**: 878–881.
- 4 ADAMS JR JR, MATA JA, CULKIN DJ, VENABLE DD. Ureteral injury in abdominal vascular reconstructive surgery. *Urology* 1992; **39**: 77–81.
- 5 BLASCO FJ, SALADIE JM. Ureteral obstruction and ureteral fistulas after aortofemoral or aortoiliac bypass surgery. *J Urol (Paris)* 1991; **145**: 237–242.
- 6 Robert M, Drianno N. Traumatisme urétéral survenu pendant une chirurgie de l'anévrisme de l'aorte abdominale sous-rénale.

- A propos de deux sections complètes découvertes en post-opératoire. *J Chir (Paris)* 1995;132:127-130.
- 7 WRIGHT DJ, ERNST CB, EVANS JR, SMITH RF, REDDY DJ, SHEPARD AD et al. Ureteral complications and aortoiliac reconstruction. *J Vasc Surg* 1990; 11: 29-37.
 - 8 ST LEZIN MA, STOLLER ML. Surgical ureteral injuries. *Urology* 1991; 38: 497-506.
 - 9 SETHIA B, DARKE SG. Abdominal aortic aneurysm with retroperitoneal fibrosis and ureteric entrapment. *Br J Surg* 1983; 70: 434-436.
 - 10 DALSING MC, BIHRLE R, LALKA SG, CIKRIT DF, SAWCHUK AP. Vascular surgery-associated ureteral injury: zebras do exist. *Ann Vasc Surg* 1993; 7: 180-186.
 - 11 SCHOENEICH G, PERABO F, HEIMBACH D, DECKER P, MULLER SC. Hydronephrosis after aorto bifemoral graft surgery: a marker for late graft complications. *Scand J Urol Nephrol* 1999; 33: 317-320.
 - 13 HEARD G, HINDE G. Hydronephrosis complicating aortic reconstruction. *Br J Surg* 1975; 62: 344-349.
 - 14 BERGAN JJ, YAO JST. In: VEITH FJ, ed. *Current problems in vascular surgery*. St Louis: Quality Medical Publishing, Inc, 1990: 267-273.
 - 15 GOLDENBERG SL, GORDON PB, COOPERBERG PL, McLOUGHLIN MG. Early hydronephrosis following aortic bifurcation graft surgery: a prospective study. *J Urol* 1988; 140: 1367-1369.
 - 16 SPIRNAK JP, HAMPFEL N, RESNICK MI. Ureteral injuries complicating vascular surgery: is repair indicated? *J Urol* 1989; 129: 13-14.
 - 17 DAVIS D. Intubated ureterotomy: a new operation for ureteral and ureteropelvic stricture. *Surg Gynecol Obstet* 1943; 76: 513-523.
 - 18 GERBER GS, LYON ES. Endopyelotomy: patient selection, results, and complications. *Urology* 1994; 43: 2-10.
 - 19 GOLDFISCHER ER, GERBER GS. Endoscopic management of ureteral strictures. *J Urol* 1997; 157: 770-775.
 - 20 PRESTI J, CARROLL P. In: McANINCH J, ed. *Ureteral and renal trauma: traumatic and reconstructive urology*. Philadelphia: Saunders WB, 1996: 171-179.
 - 21 CORMIO L, BATTAGLIA M, TRAFICANTE A, SELVAGGI FP. Endourological treatment of ureteric injuries. *Br J Urol* 1993; 72: 165-168.
 - 22 LASK D, ABARBANEL J, LUTTWAK Z, MANES A, MUKAMEL E. Changing trends in the management of iatrogenic ureteral injuries. *J Urol* 1995; 154: 1693-1695.
 - 23 AWAKURA Y, YAMAMOTO M, FUKUZAWA S, OKUNO H, HASHIMURA T, FUKUYAMA T et al. A case of uretero-aortic fistula. *Hinyokika Kiyo* 1997; 43: 299-301.
 - 24 CAMPS JI, ORTIZ VN, VARGAS J, FIGUEROA M. Uretero-arterial fistula: a case report and review of the literature. *Bol Asoc Med P R* 1998; 90: 82-84.
 - 25 INOUE T, HIOKI T, ARAI Y, INABA Y, SUGIMURA Y. Ureteroarterial fistula controlled by intraluminal ureteral occlusion. *Int J Urol* 2002; 9: 120-121.
 - 26 LEVI N, SONKSEN JR, IVERSEN P, HELGSTRAND U. Rupture of an iliac artery pseudo-aneurysm into a ureter. *Eur J Vasc Endovasc Surg* 1999; 17: 264-265.
 - 27 VAN DAMME H, KEPPELNE V, SAKALIHASAN N, ANDRIANNE R, LIMET R. Uretero-arterial fistula: two observations. *Acta Chir Belg* 1997; 97: 133-136.
 - 28 VANDERSTEEN DR, SAXON RR, FUCHS E, KELLER FS, TAYLOR JR, LM, BARRY JM. Diagnosis and management of ureteroiliac artery fistula: value of provocative arteriography followed by common iliac artery embolization and extraanatomic arterial bypass grafting. *J Urol* 1997; 158: 754-758.
 - 29 KERBL K, CHANDHOKE PS, FIGENSHAU RS, STONE AM, CLAYMAN RV. Effect of stent duration on ureteral healing following endoureterotomy in an animal model. *J Urol (Paris)* 1993; 150: 1302-1305.

Accepted 29 July 2003