

CASE REPORT

ACTH silent adenoma shrinking under cabergolineP Petrossians¹, N Ronci², H Valdés Socin¹, A Kalife¹, A Stevenaert³, B Bloch², A Tabarin² and A Beckers¹¹Endocrinology, CHU Sart Tilman, Liège, Belgium, ²Endocrinology, CHU Bordeaux, Bordeaux, France and ³Neurosurgery, CHU Sart Tilman, Liège, Belgium

(Correspondence should be addressed to A Beckers, Service d'Endocrinologie, CHU Sart Tilman B35, Liège, Belgium; Email: albert.beckers@chu.ulg.ac.be)

Abstract

Objectives: The authors present a case report that proposes the use of cabergoline treatment in silent ACTH adenoma, an unusual member of the heterogeneous group of the so-called clinically non-functioning pituitary adenomas.

Design: Following the clinical and radiological improvement of a recurrent silent ACTH adenoma in a 77-year-old patient treated with cabergoline (0.5 mg every 2 days for 2 years), *in vitro* studies of the original tumor were performed.

Methods: The original tumor from the patient was studied by *in situ* hybridization and dopamine D2 receptor autoradiography. It was compared with four macroprolactinomas and two macroadenomas from patients with Cushing's disease.

Results: The D2 receptor mRNA signal of the reported case was intense and of the same order of magnitude as that observed in control prolactinomas. Dopamine D2 receptor autoradiography was twice that of control corticotroph adenomas and was close to that observed in prolactinomas.

Conclusions: This is the first description of an *in vivo* shrinkage of an ACTH silent adenoma under cabergoline. We demonstrate *in vitro*, the presence of D2 receptors in the primitive tumor in concentrations similar to those found in control prolactinomas. These results suggest that therapeutic trials with cabergoline might be undertaken in recurring cases of ACTH silent tumors and more generally, non-functioning pituitary adenomas.

European Journal of Endocrinology 144 51–57

Introduction

Silent corticotroph adenomas of the pituitary represent 2–7% of surgically removed adenomas (1). They are defined as 'non-functional' pituitary adenomas showing an adrenocorticotrophic hormone (ACTH) staining at immunohistology. With the exception of rare cases in which the 'silent' characteristic of these adenomas is due to the secretion of an ACTH molecule devoid of biological activity (2), these adenomas are mainly diagnosed at pathological examination. The proposed treatment in those cases relies mainly on the surgical removal of the tumor.

Dopamine agonists have been used in the treatment of non-functioning pituitary adenomas and a relative shrinkage of the tumor has been reported in 20% of the cases (3). Cabergoline is a dopamine D2 receptor agonist with a higher affinity and longer half-life than bromocriptine. Its effectiveness and tolerance has been demonstrated in the treatment of prolactinomas (4) and growth-hormone (GH)-secreting adenoma (5), but there are no consistent data on its efficacy in the case of clinically functional ACTH-secreting or ACTH silent adenomas.

We report herein the case of a relapsing ACTH silent adenoma that was treated efficiently by the sole use of cabergoline.

Case report

A 77-year-old man was referred to our hospital following a sudden loss of visual acuity. Ophthalmological examination showed a bilateral visual fields defect.

Magnetic resonance imaging (MRI) revealed a pituitary tumor of 15 mm diameter with suprasellar extension and chiasmatic compression. Indirect signs of pituitary hemorrhage were noted.

Clinical examination did not show any sign of hormonal hypersecretion. Biological endocrine tests revealed a somatotroph and gonadotroph deficiency. Thyrotroph function was normal. Corticotroph status was normal: ACTH 8 h = 90 pg/ml (10–90); total cortisol = 154 µg/l (60–240); free urinary cortisol = 42 µg/24 h (10–90). The tumor was believed to be clinically non-functioning.

The tumor was successfully removed by trans-sphenoidal surgery. Immunohistochemical study of

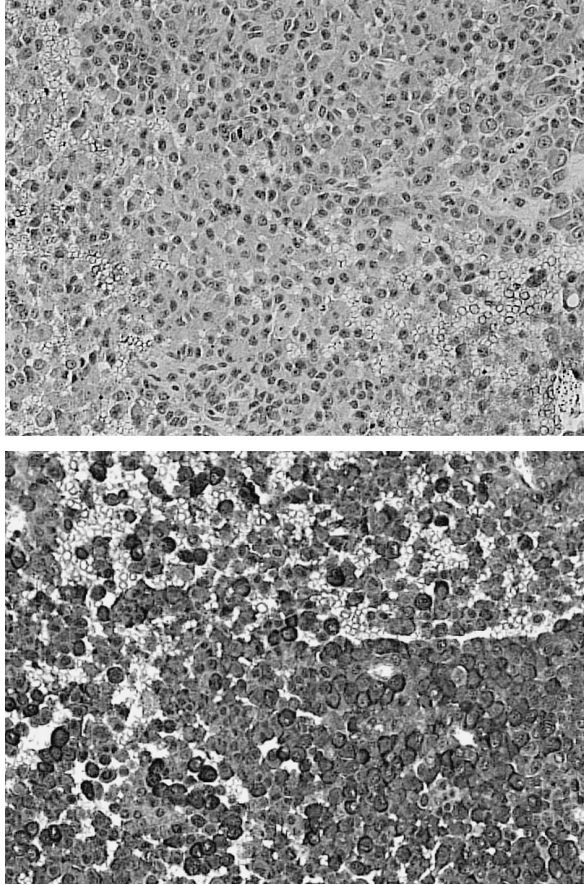


Figure 1 Immunohistochemical study of pituitary tumoral tissue. (A) Blank section of the patient's pituitary macroadenoma. (B) Immunohistochemistry revealed a staining for ACTH in 90% of the tumoral cells.

tumoral tissue revealed a staining for ACTH in 90% of the cells (Fig. 1). No staining was noted for other markers including chromogranine, prolactin (PRL), GH, luteinizing hormone, follicle-stimulating hormone and α -SU. The diagnosis of silent corticotroph adenoma was therefore established.

After surgery, complete recovery of hemianopsia was obtained. The patient was treated for multiple pituitary hormone deficiencies. The postoperative follow up and yearly MRI revealed no residual tumor. Two years after surgery, the patient was readmitted complaining of a right palpebral ptosis with right hemicranial headache, nausea and vomiting.

On physical examination, cranial nerves palsies (II, III, IV and VI), disorientation and a mild gait ataxia were noted. Pituitary MRI showed a recurrent mass extending to the right cavernous sinus without compression of the optic chiasm; the maximum tumor diameter was 30 mm (Fig. 2A).

Due to the poor general condition of the patient, further surgery was contraindicated. The patient refused stereotactic pituitary irradiation. Medical treatment with cabergoline was then started at a final dose of 0.5 mg every 2 days.

Four months later, MRI demonstrated a significant shrinkage of the adenoma with a maximal diameter reduced to 21 mm. This was associated with an improvement of the cranial nerve palsies. One year after, tumor diameter was further reduced to 17 mm (Fig. 2B) and ocular examination showed a nearly complete recovery of the ocular nerve functions. At 2 years' follow up, the size of the adenoma remains stable under cabergoline treatment and the patient remains asymptomatic.

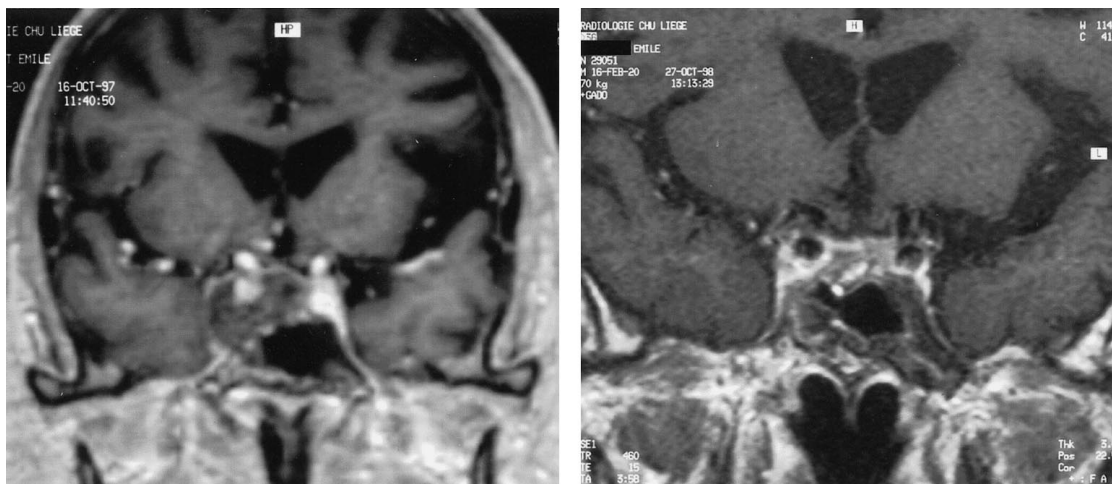


Figure 2 MRI of the pituitary (frontal views). (A) At tumor recurrence (2 years after surgery) the tumor measures 30 mm and invades the right cavernous sinus. (B) After 1 year of cabergoline treatment (0.5 mg every 2 days) there is a significant shrinkage of the tumor and nearly complete disappearance of the clinical symptoms.

Materials and methods

Tissues

The tumor was collected rapidly after excision and was stored in aluminum foil at -80°C . Four macroprolactinomas (P1–P4) known to exhibit a significant D2 mRNA signal using *in situ* hybridization were collected under the same conditions and used as positive controls. Acute administration of bromocriptine at a dose of 2.5 mg in patients bearing P2 and P4 suppressed the mean plasma PRL concentration by more than 50% within 8 h. Two additional corticotroph macroadenomas obtained from patients with Cushing's disease (C1, C2) were also studied.

In situ hybridization

All adenomas were hybridized during the same experiment. The protocol used has been described previously (6). Briefly, antisense and sense radiolabelled cRNA probes were prepared by *in vitro* transcription of the DNA template from plasmid pCMV5 constructs containing the cDNA encoding D2 receptor (2300 bp). The antisense probe recognized indifferently the two D2 receptor mRNA isoforms generated by alternative splicing. Plasmids containing the coding region of D2 receptor were generously provided by Dr Caron (Duke University, USA).

After hybridization, slides were exposed in contact with I-Max film for 1 month, then coated with Ilford K-5 emulsion and exposed for 3 months.

Control for specificity of the hybridization signal was performed using the corresponding sense probe for each section studied. No weak spurious or non-specific signal was observed when the slides were hybridized with the sense probe (Fig. 3).

Quantitative analysis of mRNA signal was performed at the macroscopic level (autoradiogram) using an image analyser system (Biocom, Les Ulis, France) fitted with a densitometric image system. A CDD camera provided a computerized image on a video monitor on which the regions of interest were delineated. The optical density (OD) was measured among each adenoma (in the whole section of each tumor). We measured the ODs of the antisense and the sense mRNA signal. The OD of the sense signal was then subtracted from the OD of the antisense signal. The OD of the sense signal was equal to zero or very weak.

Dopamine D2 receptor autoradiography

The protocol used has been described previously (7). Briefly, slides were preincubated and then incubated in the incubation buffer for 30 min at room temperature in the presence of the radioligand [^{125}I]-iodosulpride at a concentration of 0.5 nM (2000 Ci/mmol). Because this study was performed *in vitro* on pituitary tissue,

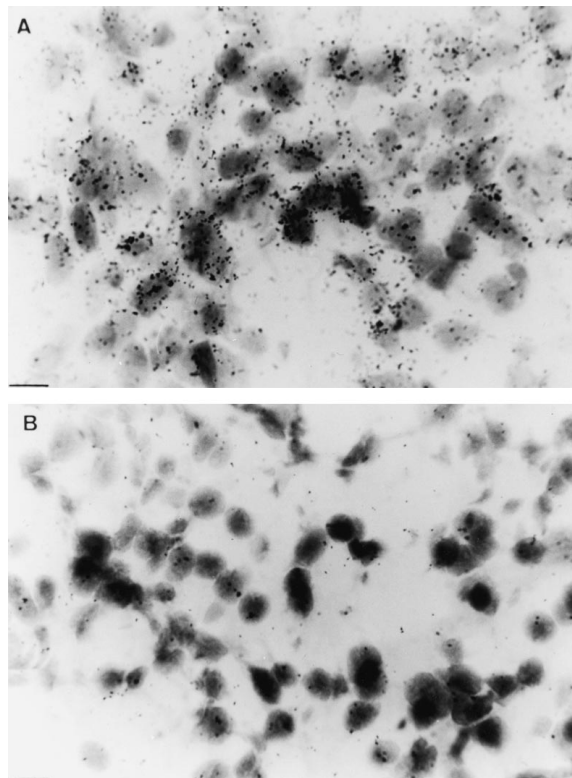


Figure 3 *In situ* hybridization for dopamine D2 receptor mRNA in the silent corticotroph adenoma (microautoradiography). (A) Hybridisation with the antisense probe shows dopamine D2 receptor mRNA in tumor cells. Scale bar = 10 μm . (B) Control for specificity of the labeling with the sense probe. Only weak background signal is observed. Scale bar = 10 μm .

where mainly D2 receptors are present, the use of iodosulpride, which is less specific than cabergoline, was considered satisfactory (8). Non-specific binding was determined on adjacent sections after addition of unlabelled competitor to the incubation medium (10^{-5} M sulpride). After washing, the sections were then exposed on 3H-Hyperfilm (Amersham Bucks, UK) for 1 month. The autoradiograms were quantified using an image analyzer system by measuring the mean OD for each tissue sample. The OD of the non-specific signal was equal to zero for all the adenomas.

Results

In situ hybridization

Using macroautoradiography (Fig. 4), the D2 receptor mRNA signal in the four prolactinomas studied was variable. A significant D2 receptor mRNA signal was found in the two control corticotroph adenomas (C1, C2). However, the intensity of the signal in these was approximately half of that observed in prolactinomas.

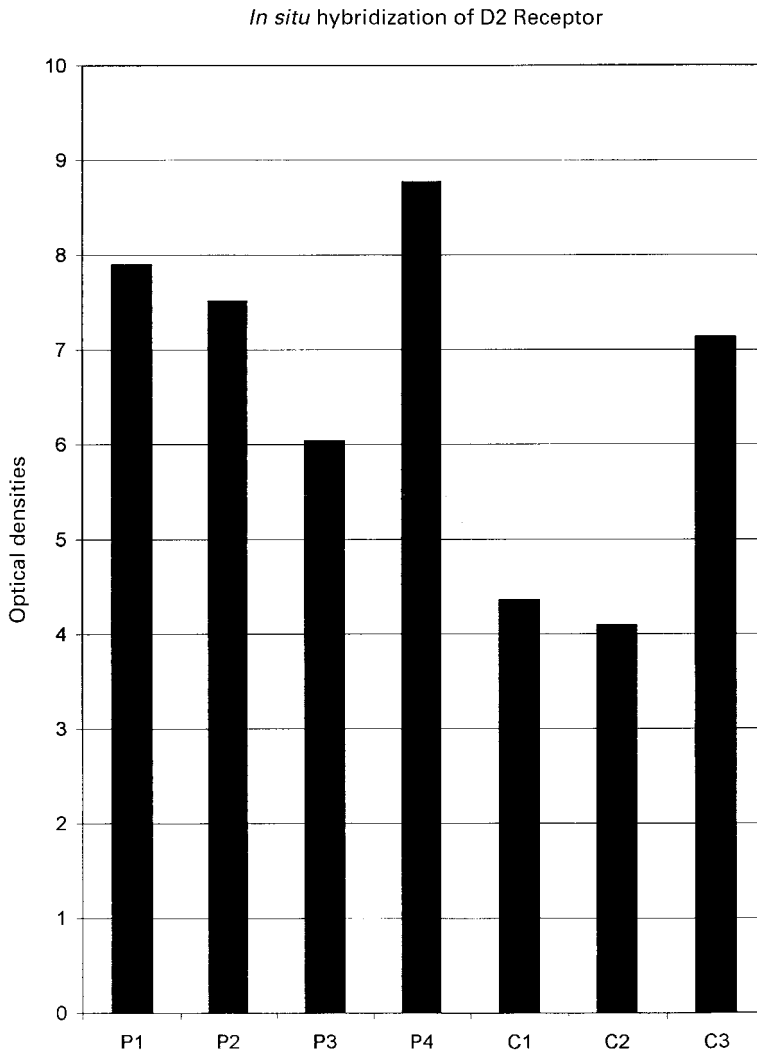


Figure 4 Quantitative *in situ* hybridization analysis of dopamine D2 receptor mRNA. Control prolactinomas (P 1–4), control corticotroph adenomas (C1, C2) and the adenoma of the reported case (C3).

By contrast, the D2 receptor mRNA signal in the adenoma of case reported (C3) was intense and of the same order of magnitude than that observed in prolactinomas.

Dopamine D2 receptor autoradiography

The prolactinomas exhibited a signal of variable intensity (Fig. 5). The two control corticotroph adenomas (C1, C2) showed a weak signal that was approximately one third of the median value observed in the prolactinomas. As a whole, the intensity of the signal in the tumor of the patient presented here (C3) was twice that of control corticotroph adenomas and was close to the range of values observed in prolactinomas.

Using macroautoradiography (Fig. 6), a weak dopamine D2 receptor signal appeared to be distributed along the whole surface of control corticotrophs (C1–C2). On the contrary, in adenoma C3, the distribution of D2 receptor binding sites was heterogeneous and

some areas displayed an intense signal comparable to that seen in prolactinomas.

Discussion

We report herein the first case of an ACTH silent adenoma showing a significant shrinkage under cabergoline treatment. The efficacy of this treatment was believed to be due to the presence of dopamine D2 receptors in the tumor cells.

ACTH silent adenomas are clinically non-functioning tumors that are usually diagnosed at immunohistologic examination of the tumorous tissues after surgical treatment. Although there are few reports about these tumors in the literature, they may represent 2–7% of all surgically treated adenomas (1). They present the same histological and ultrastructural features of ACTH-secreting adenomas of the pituitary in Cushing's disease (9). Different hypotheses have been proposed to explain the lack of clinical symptomatology of these tumors such as the defective packaging of tumor ACTH

Binding of D2 Receptor

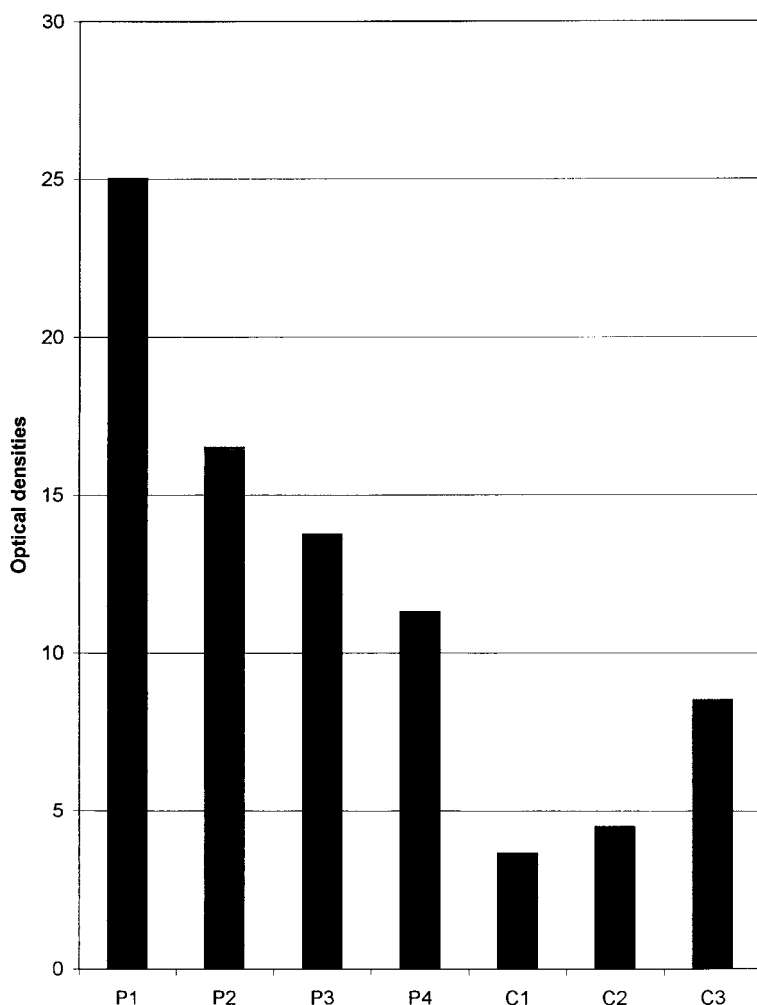


Figure 5 Quantitative analysis of binding of the dopamine D2 receptor. Control prolactinomas (P 1–4), control corticotroph adenomas (C1, C2) and the adenoma of the reported case (C3).

and the increased intracellular degradation of the hormone (10, 11). A few cases of tumors secreting a biologically inactive hormone have also been described (2).

Because these adenomas do not elicit a Cushing's disease, the main goal of the treatment is to obtain a reduction in tumor size. Surgery has been the main therapeutic approach in all described cases. To the best of our knowledge, only one report regarding the effectiveness of bromocriptine in obtaining murine tumor shrinkage in such cases has been published (22). In another report, bromocriptine was used in a patient to prevent the recurrence of an aggressive silent corticotroph adenoma (23). We did not find any report with cabergoline.

However, dopamine agonists have been successfully used for controlling hormonal hypersecretion in some ACTH secreting adenomas responsible for Cushing's disease (12, 13) and a few cases of tumor shrinkage have also been reported (14).

Five different dopamine receptors have been cloned so far. These receptors are divided in two groups by their molecular, biochemical and pharmacological differences (15). The first group comprises the D1 and D5 receptors and the second group the D2, D3 and D4 receptors. In the pituitary, hormonal response to dopamine agonists is related to the activity of the D2 receptor (16). The latter belongs to the family of the G protein-coupled receptors and acts through the inhibition of the AMP cyclase enzyme. Alternative splicing of the gene encoding the D2 receptor leads to two subtypes of this receptor, the short isoform (D2Rs) and the long isoform (D2Rl) (17).

The relation between the presence of the D2 receptor and the therapeutic response of pituitary adenomas to dopamine agonists has been studied in a variety of tumors. In prolactinomas, the presence of numerous D2 receptors explains the good therapeutic response of these tumors to dopamine agonists. Drug resistance in some of these adenomas may be explained either by the

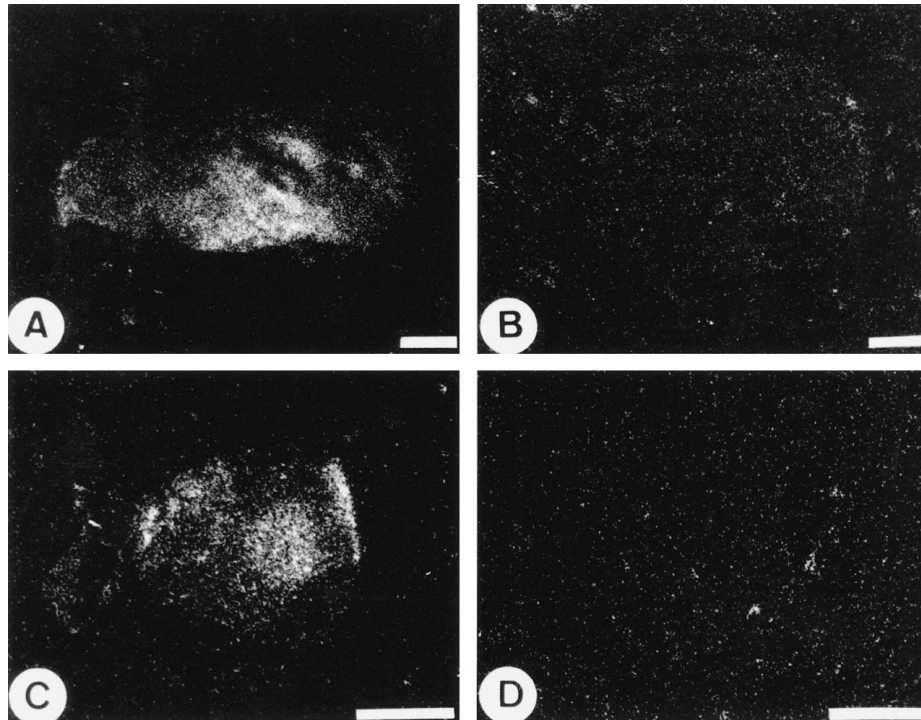


Figure 6 *In vitro* autoradiographical distribution of [¹²⁵I]-iodosulpride binding (scale: line = 1 mm). (A) Total binding in a control prolactinoma (P4). A heterogeneous signal is observed within the tumor. (B) Weak total binding in a control corticotroph adenoma (C1). (C) Total binding in the tumor of the patient (C3). (D) Control for non-specific binding in the tumor of the patient (C3). No residual binding is seen in the presence of 10⁻⁵ M sulpride.

absence or the reduced amount of these receptors (19) or by their functional inactivity (18). Treatment with dopamine agonists not only reduces the hormonal secretion, but also reduces the tumor size. Tumor shrinkage seems to be related to the disappearance of the rough endoplasmic reticulum and of the Golgi apparatus which leads to a reduction of tumor cell size (20).

Before somatostatin analogs, dopamine agonists were the only medical treatment for GH-secreting adenomas. Dopamine receptors have also been demonstrated in GH-secreting cells, but the biological and tumoral response to dopamine agonists is not as marked as in prolactinomas. This reduced sensitivity may be due to a difference in the abundance of D2 receptors as well as their structural and functional properties and a reduced AC inhibition. However, our data (5) demonstrates that despite a reduced number of D2 receptors and/or reduced effectiveness in GH-secreting adenomas, the resistance of these tumors to dopamine agonists can be overcome in a number of cases with the use of high affinity agonists, such as cabergoline.

In non-functioning adenomas, D2 receptors have been demonstrated in a large number of studied adenomas, but partial tumor shrinkage has been reported in only 20% of the published cases (3). Drug resistance in these adenomas may be due to the same

D2 receptor abnormalities than in GH-secreting adenomas. A recent study suggests that cells presenting the short subtype receptor (D2Rs) may present a better inhibitory response to DA, at least *in vitro* (21).

Less data are available about the efficacy of dopamine agonists in ACTH-secreting adenomas. Hormonal normalization has been described in some cases (12, 13). Dopamine agonists have also shown a growth inhibitory effect and provoked *in vitro* cellular apoptosis in murine ACTH-secreting pituitary adenoma cells (22). Interestingly, a report has recently demonstrated a complete remission of a Nelson's syndrome following bilateral adrenalectomy, after 1 year of treatment with cabergoline (24).

Our case is the first report of a silent ACTH adenoma treated by cabergoline. The dramatic tumor shrinkage in our case is likely due to the cabergoline therapy. Our *in vitro* studies on tumor tissue from the original adenoma provided evidence of D2 receptor expression within the tumor with an intensity roughly comparable to that found in control prolactinomas. In contrast, no or only weak expression of D2 receptor was found on control corticotroph adenomas of patients with Cushing's disease.

One might speculate that the partial shrinkage of the tumor under cabergoline treatment is due to the heterogeneous distribution of D2 receptors in tumor cells as demonstrated by *in situ* hybridization and

binding studies, although we can not exclude that the recurring tumor originated from a clone expressing the D2 receptor differently.

Whether cabergoline may be as efficient in other cases of ACTH silent adenomas and, more generally, non-functioning adenomas is to be assessed. Therapeutic trials may be performed in cases of recurring adenomas or when surgery is contraindicated. *In vivo* scintigraphy using D2 agonists (25, 26), or *in vitro* D2 receptor studies in recurring tumors may allow a better selectivity in the therapeutic choice.

Acknowledgements

This work was supported by a grant of the Pôle Aquitaine Santé from the Conseil Régional d'Aquitaine.

We thank Dr J Demotes-Mainard for technical assistance in binding studies.

References

- Horvath E, Scheithauer BW, Kovacs K, Lloyd RC, Graham DI & Lantos PL. Regional neuropathology: Hypothalamus and pituitary. In *Grenfields Neuropathology*, pp 1007–1094. New York: Oxford University Press, 1997.
- Ueyama T, Tamaki N, Kondoh T & Kurata H. Large, invasive silent corticotroph-cell adenoma with elevated serum ACTH: a case report. *Surgical Neurology* 1998 **50** 30–31.
- Liuzzi A, Dallabonzana D, Oppizzi G, Arrigoni GL, Cozzi R, Strada S *et al.* Is there a real medical treatment for 'non-secreting' pituitary adenomas? In *Pituitary adenomas: new trends in basic and clinical research*, pp 383–390. Eds G Faglia, P Beck Peccoz, A Ambrosi, P Travaglini & A Spada. Amsterdam: Excerpta Medica, 1991.
- Verhelst J, Abs R, Maiter D, Van den Bruel A, Vandeweghe M, Velkeniers B *et al.* Cabergoline in the treatment of hyperprolactinemia: A study in 45 patients. *Journal of Clinical Endocrinology and Metabolism* 1999 **842** 518–522.
- Abs R, Verhelst J, Maiter D, Van Acker K, Nobels F, Coolens JL *et al.* Cabergoline in the treatment of acromegaly: a study in 64 patients. *Journal of Clinical Endocrinology and Metabolism* 1998 **833** 74–78.
- Brana C, Charron G, Aubert I, Carles D, Martin-Negrier ML, Trouette H *et al.* Ontogeny of the striatal neurons expressing neuropeptide genes in the human fetus neonate. *Journal of Comparative Neurology* 1995 **360** 488.
- Martres MP, Bouthenet ML, Sales N, Sokoloff P & Schwartz JC. Widespread distribution of brain dopamine receptors evidenced with [¹²⁵I]iodosulpride, a highly selective ligand. *Science* 1985 **228** 752–755.
- Wood DF, Johnston JM & Johnston DG. Dopamine, the dopamine D2 receptor and pituitary tumours. *Clinical Endocrinology* 1991 **35** 455–466.
- Horvath E & Kovacs K. Ultrastructural diagnosis of human pituitary adenomas. *Microscopy Research and Techniques* 1992 **20** 107–135.
- Horvath E, Kovacs K, Killinger DW, Smyth HS, Platts ME & Singer W. Silent corticotrophic adenomas of the human pituitary gland: a histologic and immunocytoologic ultrastructural study. *American Journal of Pathology* 1980 **986** 17–38.
- Bilbao JM. Pituitary Gland. In *Ackerman's Surgical Pathology*, pp 2428–2432. Eds J Rossi. St Louis: Mosby, 1996.
- Lamberts SWJ, Klijn JGM, De Quijada M, Timmermans HAT, Uitterlinden P, De Jong FH *et al.* The mechanism of the suppressive action of bromocriptine on adrenocorticotrophin secretion in patients with Cushing's disease and Nelson's syndrome. *Journal of Clinical Endocrinology and Metabolism* 1980 **51** 307–311.
- Whitehead HM, Beacom R, Sheridan B, Kennedy AL, Hadden HR & Atkinson AB. The effect of cyproheptadine and/or bromocriptine on plasma ACTH levels in patients cured of Cushing's disease by bilateral adrenalectomy. *Clinical Endocrinology* 1990 **32** 193–202.
- Invitti C, De Martin M, Danesi L & Cavagnini F. Effect of injectable bromocriptine in patients with Cushing's disease. *Experimental Clinical Endocrinology and Diabetes* 1995 **103** 266–271.
- Civelli O, Bunzow JR & Gry DK. Molecular diversity of the dopamine receptors. *Annual Review of Pharmacology and Toxicology* 1993 **32** 281–307.
- Lamberts SWJ & MacLeod RM. Regulation of prolactin secretion at the level of the lactotroph. *Physiological Review* 1990 **70** 279–318.
- Giros B, Sokoloff P, Martres MP, Riou JF, Emorine LJ & Schwartz JC. Alternative splicing directs the expression of two D2 dopamine receptor isoforms. *Nature* 1989 **342** 923–926.
- Friedman E, Adams E, Hoog A, Gejman PV, Carsson E, Larsson C *et al.* Normal structural dopamine type 2 receptor gene in prolactin-secreting and other pituitary tumors. *Journal of Clinical Endocrinology and Metabolism* 1994 **785** 68–74.
- Pellegrini I, Rasolonjanahary R, Gunz G, Bertrand P, Delivet S, Jedynak CP *et al.* Resistance to bromocriptine in prolactinomas. *Journal of Clinical Endocrinology and Metabolism* 1989 **69** 500–509.
- Bevan JS, Webster J, Burke CW & Scanlon MF. Dopamine agonists and pituitary tumor shrinkage. *Endocrine Reviews* 1992 **13** 220–240.
- Renner U, Arzberger T, Pagotto U, Leimgruber S, Uhl E, Muller A *et al.* Heterogeneous dopamine D2 receptor subtype messenger ribonucleic acid expression in clinically nonfunctioning pituitary adenomas. *Journal of Clinical Endocrinology and Metabolism* 1998 **83** 1368–1375.
- Yin D, Kondo S, Takeuchi J & Morimura T. Induction of apoptosis in murine ACTH-secreting pituitary adenoma cells by bromocriptine. *FEBS Letters* 1994 **339** 73–75.
- Sakaguchi H, Koshiyama H, Sano T, Inoue D, Hashimoto N, Aoki N *et al.* A case of non-functioning pituitary adenoma resembling so-called silent corticotroph adenoma. *Endocrine Journal* 1997 **44** 329–333.
- Pivonello R, Faggiano A, Di Salle FD, Filippella M, Lombardi G & Colao A. Complete remission of Nelson's syndrome after 1-year treatment with cabergoline. *Journal of Endocrinological Investigation* 1999 **22** 860–865.
- Ferone D, Lastoria S, Colao A, Varella P, Cerbone G, Acampa W *et al.* Correlation of scintigraphic results using ¹²³I-methoxybenzamide with hormone levels and tumor size response to quinagolide in patients with pituitary adenomas. *Journal of Clinical Endocrinology and Metabolism* 1998 **83** 248–252.
- Colao A, Ferone D, Lastoria S, Cerbone G, Di Sarno A, Di Somma C *et al.* Hormone levels and tumour size response to quinagolide and cabergoline in patients with prolactin-secreting and clinically non-functioning pituitary adenomas: predictive value of pituitary scintigraphy with ¹²³I-methoxybenzamide. *Clinical Endocrinology* 2000 **52** 437–445.

Received 15 June 2000

Accepted 29 August 2000