

# Three-dimensional echocardiographic assessments of exercise-induced changes in left ventricular shape and dyssynchrony in patients with dynamic functional mitral regurgitation

Masaki Izumo<sup>1\*</sup>, Patrizio Lancellotti<sup>2</sup>, Kengo Suzuki<sup>1</sup>, Seisyou Kou<sup>1</sup>, Takashi Shimozato<sup>1</sup>, Akio Hayashi<sup>1</sup>, Yoshihiro J. Akashi<sup>1</sup>, Naohiko Osada<sup>1</sup>, Kazuto Omiya<sup>1</sup>, Sachihiko Nobuoka<sup>3</sup>, Eiji Ohtaki<sup>1</sup>, and Fumihiko Miyake<sup>1</sup>

<sup>1</sup>Division of Cardiology, Department of Internal Medicine, St Marianna University School of Medicine, 2-16-1 Sugao, Miyamae-ku, Kawasaki, Kanagawa 216-8511, Japan; <sup>2</sup>Department of Cardiology, University Hospital of Liège, CHU Sart Tilman, Liège, Belgium; and <sup>3</sup>Department of Laboratory Medicine, St Marianna University School of Medicine, Kawasaki, Japan

Received 3 May 2009; accepted after revision 20 August 2009; online publish-ahead-of-print 20 September 2009

## KEYWORDS

Left ventricular  
dyssynchrony;  
Mitral regurgitation;  
Exercise;  
3D echocardiography

**Aims** Left ventricular (LV) shape and LV dyssynchrony are two cofactors associated with functional mitral regurgitation (MR) in patients with heart failure. Both can be accurately examined by real-time three-dimensional echocardiography (3DE). We examined the relationship between dynamic MR and exercise-induced changes in LV shape and synchronicity using 3DE.

**Methods and results** Fifty patients with systolic LV dysfunction underwent 2D and 3D quantitative assessment of LV function, shape, and synchronicity at rest and during symptom-limited exercise test. According to the magnitude of change in MR, patients were divided into EMR group (15 patients, 30%), if the degree of MR increased during test, and NEMR group. During exercise, the changes in LV volumes and ejection fraction were similar in both groups, whereas changes in mitral valvular deformation parameters, in LV sphericity index, and in the extent of LV dyssynchrony were more pronounced in the EMR group. At rest, only the 3D sphericity index could distinguish the two groups. By stepwise multiple regression model, dynamic changes in the systolic dyssynchrony index, sphericity index, and coaptation distance were associated with dynamic MR ( $r^2 = 0.45$ ,  $P = 0.012$ ).

**Conclusion** Dynamic MR during exercise is related to the 3D changes in LV shape and in LV synchronicity.

## Introduction

Functional disability is one of the most common problems experienced by patients with chronic heart failure (HF). A limited increase in cardiac output is certainly the initial determinant of exercise intolerance and muscle fatigue in these patients.<sup>1</sup> In normal condition, the stroke volume gradually increases during exercise,<sup>2,3</sup> whereas in HF patients, exercise-induced changes in forward stroke volume have been shown to be inversely related to the extent of dynamic mitral regurgitation (MR).<sup>4–6</sup> Functional MR, a frequent condition in HF, is characteristically dynamic with intermittent changes in regurgitant volume in relation with loading conditions,<sup>5–9</sup> changes in LV shape,

and dynamic LV dyssynchrony.<sup>9,10</sup> An exercise increase by  $\geq 13 \text{ mm}^2$  in mitral effective regurgitant orifice is associated with a three-fold greater risk of cardiac-related death.<sup>11</sup> The recognition of the determinants of dynamic MR is therefore an important issue. Three-dimensional (3D) echocardiography is now widely used to complement the 2D echocardiographic assessments of cardiovascular functions. It allows better evaluation of LV geometry and classically overcomes the common limitations of tissue Doppler imaging for the assessment of LV dyssynchrony. To date, no clinical studies have assessed the effects of exercise on the 3D LV function. In the present study, we sought, thus, to examine the relationship between dynamic MR and exercise-induced changes in LV shape and synchronicity by using real-time 3D echocardiography (3DE) in a subset of HF patients.

\* Corresponding author. Tel: +81 44 977 8111; fax: +81 44 976 7093.  
E-mail address: m2izumo@marianna-u.ac.jp

## Methods

### Subjects

This prospective study involved 50 patients with compensated systolic HF [ejection fraction (EF) < 45%]. This study involved 10 patients (20%) with moderate MR [ $0.35 >$  effective regurgitant orifice (ERO)  $\geq 0.2 \text{ cm}^2$ ] and 40 patients (80%) with mild MR ( $0.2 \text{ cm}^2 >$  ERO). All patients underwent a comprehensive 2D and 3D echocardiogram at rest and at peak exercise. All study subjects were clinically stable; none was hospitalized or had any changes in the prescribed medications over the 7 days before the testing. The mean age was  $60 \pm 13$  years. Twenty patients were in functional NYHA class I, 28 in class II, and 2 in class III. The aetiology of HF was idiopathic dilated cardiomyopathy in 34 patients and ischaemic heart disease in 16. Ischaemic disease was determined when patients had either evidence of previous myocardial infarction (>6 months) or significant coronary artery disease detected by angiography (stenosis >50% in one of the major epicardial coronary arteries), the patients had no significant coronary artery stenosis at least 2 month before enrolment. Among the study population, 41 patients (82%) received diuretics, 36 (72%)  $\beta$ -blockers, 28 (56%) angiotensin-converting enzyme inhibitors, and 14 (28%) angiotensin II receptor antagonists (Table 1). No patients had a recent history of acute coronary syndrome or a revascularization procedure within the last 6 months, technically inadequate echocardiogram, organic MR, or unstable ventricular rhythm. The study protocol was approved by the St Marianna University School of Medicine Institutional Committee on Human Research (No. 1288). Written informed consent was obtained from all of the subjects prior to their enrolment.

### Exercise echocardiography

#### Exercise testing

All participants underwent a symptom-limited graded bicycle exercise test in a semi-supine position on a tilting exercise table for continuous 2DE and 3DE. After an initial 3 min workload at 10 W, the intensity was increased in 5 W every minute. All echocardiographic images were obtained at rest and within 3 min before the peak exercise and digitally stored. Single-lead electrocardiogram and blood pressure were recorded every minute. The participants were asked to declare their perceived exertions of the chest and legs separately according to a 6- to 20-category scale<sup>12</sup> during the test. The criteria to halt the test were chest pain, severe dyspnoea, severe fatigue, sustained blood pressure drop, sustained ventricular tachycardia, short runs of three or more ventricular premature contractions, pallor, or dizziness.

#### Echocardiography

All echocardiographic examinations were performed using an iE33 (Philips, Andover, MA, USA), 2D echocardiography equipped with a 2.5–5 MHz imaging probe, and a harmonic real-time 3DE with a matrix-array transducer (X3-1, 1.9/3.8 MHz). Recordings were performed according to the standard recommendations.<sup>13</sup> Harmonic real-time 3D imaging depicted the entire LV cavity within the pyramidal volume scan. A real-time 3D data set equipped with a wide-angle acquisition ( $93 \times 80^\circ$ ) mode could obtain four wedge-shaped subvolumes ( $93 \times 20^\circ$  each) during four consecutive cardiac cycles. Data were acquired from the apical four-chamber position during a breath hold at the end of expiration. Data were subsequently transferred to an offline computer for analysis using commercially available software (3DQ ADV, QLAB, Version 4.2, Philips). Each parameter was measured on the average of three consecutive beats at rest and at peak exercise, respectively.

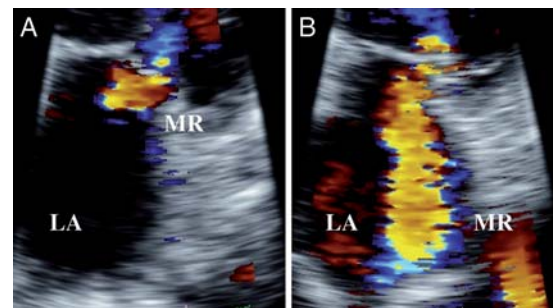
#### Two-dimensional echocardiography

Parameters were measured at rest and at peak exercise. The mitral annular diameter and mitral valve coaptation distance between the mitral annular plane and mitral leaflet coaptation point were

**Table 1** Baseline characteristics

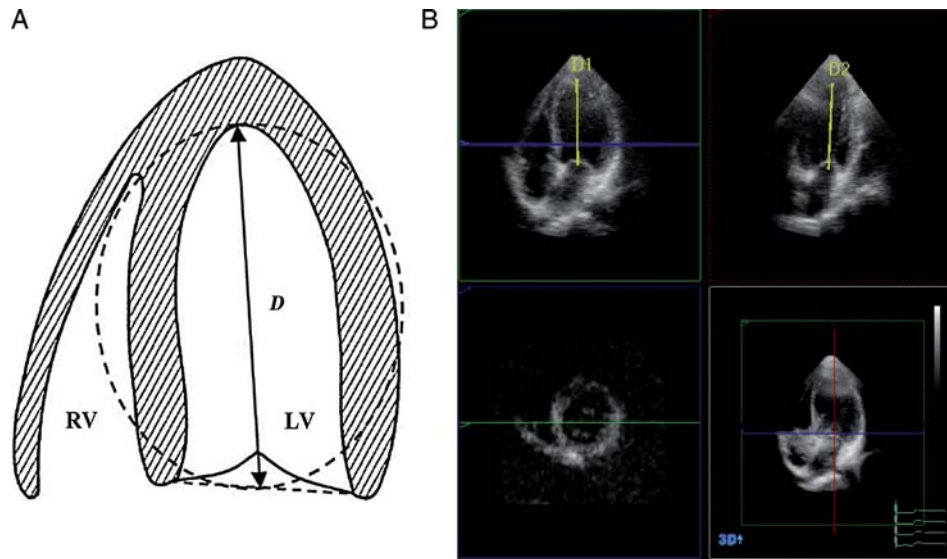
	EMR	NEMR	P-value
Age (years)	$65.3 \pm 8.5$	$54.5 \pm 11.2$	$P < 0.01$
Sex			
Male	12	32	NS
Female	3	3	NS
NYHA			
Class I	1	9	$P < 0.001$
Class II	13	15	NS
Class III	1	1	NS
BNP (pg/mL)	$297.5 \pm 225.3$	$229.0 \pm 211.5$	NS
QRS (ms)	$111.9 \pm 39.2$	$113.8 \pm 41.9$	NS
Peak blood pressure	$132.7 \pm 19.8$	$159.0 \pm 31.1$	NS
Peak heart rate (bpm)	$103.3 \pm 20.8$	$118.9 \pm 21.6$	NS
The causes of exercise cessation (shortness of breath/leg fatigue)	12/3	6/29	$P < 0.05$
Aetiology			
DCM	8	26	NS
PMI	7	9	NS
Medication			
ACEI	7	21	NS
ARB	4	10	NS
$\beta$ -blocker	9	27	NS
Diuretics	12	29	NS

EMR, exercise-induced mitral regurgitation; NEMR, no exercise-induced mitral regurgitation; NYHA, New York Heart Association; BNP, brain natriuretic peptide; DCM, dilated cardiomyopathy; PMI, previous myocardial infarction; ACEI, angiotensin-converting enzyme inhibitor; ARB, angiotensin II receptor blocker.



**Figure 1** An example of exercise-induced increase in mitral regurgitation (A) at rest and (B) at peak exercise. LA, left atrium; MR, mitral regurgitation.

measured in the parasternal long-axis view. In addition, the valvular tenting area was measured by the area enclosed between the annular plane and the mitral leaflets in the parasternal long-axis view. All parameters of mitral deformation were measured at late systole. Exercise-induced changes in echocardiographic variables were expressed as absolute differences between the values at peak exercise and at rest ( $\Delta$  value) (Figure 1). Functional MR was quantified according to the proximal isovelocity surface area method; the ERO and the regurgitant volume, which indicates the severity of functional MR, were obtained. HF patients were classified as EMR group, if the degree of MR increased during test ( $\Delta_{\text{rest-peak exercise ERO}} \geq 13 \text{ mm}^2$ ), and NEMR group in the other cases ( $\Delta_{\text{rest-peak exercise ERO}} < 13 \text{ mm}^2$ ).<sup>11</sup>



**Figure 2** (A) The three-dimensional sphericity index. This figure shows the left ventricular cavity, where  $D$  is the left ventricular end-systolic major long axis. The formula:  $4/3 \times \pi \times (D/2)^3$ . The spherical volumes in millilitres can be calculated, where  $D$  is the diameter (cm). The three-dimensional sphericity index is calculated by  $EDV/[4/3 \times \pi \times (D/2)^3]$ , a modification of the equation used in Mannaerts *et al.*<sup>14</sup> (B) Quad image display of the dynamic three-dimensional data set with two near perpendicular long axis images (top panels), a short axis images (lower left), and a cubical display with the corresponding cutplane (lower right). The measurement of  $D$  is shown. The left ventricular long axis ( $D_1$  or  $D_2$ ) was obtained from the three-dimensional echocardiographic data set as the longest distance between the centre of the mitral annulus and the endocardial apex. The longest  $D$ s were used in the four-chamber view ( $D_1$ ) and two-chamber view ( $D_2$ ).

### Three-dimensional echocardiography

The global LV volumes, the end-systolic volume index (ESVI), the end-diastolic volume index (EDVI), and the global EF (in%) were obtained from the results of 3DE. The 3D sphericity index was calculated from ESV divided by the volume of a sphere with a diameter corresponding to the major axis at end-systole in LV long view. The LV long axis was obtained from 3D echocardiographic data as the longest distance between the centre of the mitral annular and the endocardial apex (Figure 2).<sup>14</sup> The LV was divided into 17 segments from the apex to the base according to American Heart Association and American Society of Echocardiography segmentation schema, and curves depicting regional volumes over the cardiac cycle were obtained for each segment. The regional ejection time, defined as the time interval between the R wave and minimal end-systolic volume ( $T_{msv}$ ), was automatically calculated based on each regional volume curve excluding the apical cap (the segment 17). The standard deviation (SD) of the regional volume time curves was obtained using 16 segments ( $T_{msv} - 16$  SD) to assess systolic synchrony. The maximal difference of  $T_{msv}$  was also calculated, generating the following additional indices of dyssynchrony: the maximal difference of  $T_{msv}$  among 16 segments; among the 6 basal and 6 middle segments; and among the 6 basal segments. We calculated the difference of  $T_{msv}$  between the basal septal and basal lateral segments and the difference of  $T_{msv}$  between the basal septal and basal posterior segments as well.<sup>15</sup>

The dyssynchrony index was calculated by the time taken to reach minimum regional volume for each segment as a percentage of the cardiac cycle. The systolic dyssynchrony index (SDI) was defined as the SD of these timings. Higher SDI indicates increasing intraventricular dyssynchrony. To allow comparisons between patients with significantly different heart rates, SDI was expressed as a percentage of the duration of the cardiac cycle rather than in milliseconds (Figure 3).

### Statistical analysis

Data are expressed as mean  $\pm$  SD. Student's paired two-tailed *t*-test was used to compare measurements obtained at rest and during exercise. Spearman's regression analysis was used to analyse the correlations between two parameters. A value of  $P < 0.05$  was

considered significant. Linear regression analysis to determine cofactors associated with changes in MR during exercise, a stepwise multiple linear regression analysis, was performed. All continuous variables were included in the multivariable model.

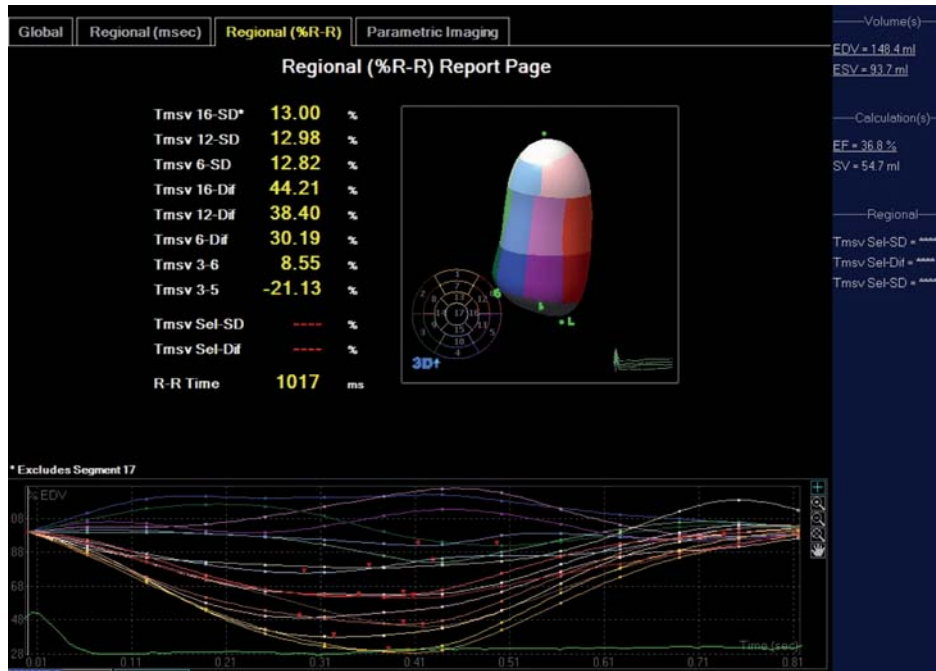
## Results

### Baseline and exercise characteristics

The study protocol was successfully completed, and technically adequate recordings were obtained for analysis in all patients. None of them experienced chest pain or manifested ST segment depression during exercise. During test (mean duration  $11.0 \pm 4.0$  min), systolic blood pressure ( $126 \pm 9$  to  $158 \pm 13$  mmHg) and heart rate ( $78 \pm 11$  to  $118 \pm 9$  bpm) significantly increased ( $P < 0.0001$ ). The causes of exercise cessation were shortness of breath in 18 patients (36%) and leg fatigue in the remaining 32 subjects (64%). Fifteen (30%) patients had a severe increase in the amount of MR during exercise and were categorized into the EMR group.

### Exercise-induced changes in left ventricular shape and synchronicity

The effects of exercise on LV function and shape are summarized in Table 2. During exercise, changes in EDVI, ESVI, and EF were similar in both the EMR and the NEMR groups. Conversely, changes in mitral valvular deformation parameters (systolic tenting area, coaptation distance, and annular diameter) were more pronounced in the EMR patients. More severe the deformation, more significant the MR. By 3DE, the LV sphericity index ( $P < 0.0007$ ) and the extent of LV dyssynchrony increased significantly in the EMR patients, whereas these parameters remained fairly unchanged in the NEMR group. To note, the 3D sphericity index was greater at rest in the EMR group ( $P < 0.0001$ ). Under resting conditions, the 3D sphericity index was the sole significant parameter



**Figure 3** Example of left ventricular dyssynchrony indices automatically acquired with real-time three-dimensional echocardiography, left ventricular cast, and volumetric regional curves of 16 segments are shown.

**Table 2** Echocardiographic changes during exercise

	EMR		NEMR	
	Rest	Exercise	Rest	Exercise
<b>2D echocardiogram</b>				
Coaptation depth (mm)	14.6 ± 3.4	17.4 ± 4.0 <sup>*,†</sup>	12.7 ± 4.0	12.3 ± 4.1
Tenting area (mm <sup>2</sup> )	258.4 ± 60.6	356.6 ± 492.2 <sup>*,†</sup>	233.7 ± 70.7	227.1 ± 68.4
Annular diameter (mm)	35.9 ± 5.0	38.3 ± 4.4 <sup>*,†</sup>	32.1 ± 5.4	32.4 ± 5.0
RV (mL)	17.5 ± 9.8	41.8 ± 17.0 <sup>*,†</sup>	18.7 ± 12.8	19.7 ± 9.3
ERO (mm <sup>2</sup> )	14.0 ± 7.0	30.0 ± 10.0 <sup>*,†</sup>	14.0 ± 8.0	17.0 ± 7.0
<b>3D echocardiogram</b>				
EDVI (mL/m <sup>2</sup> )	104.1 ± 40.8	97.7 ± 49.4	85.8 ± 26.6	86.1 ± 33.3
ESVI (mL/m <sup>2</sup> )	66.6 ± 34.3	62.6 ± 34.8	32.2 ± 11.6	52.5 ± 25.9
SVI (mL/m <sup>2</sup> )	36.8 ± 13.7	35.6 ± 14.6	32.2 ± 11.6	38.6 ± 17.7
Ejection fraction (%)	37.7 ± 10.2	37.3 ± 8.5	40.1 ± 10.1	43.4 ± 11.3
Sphericity index	0.36 ± 0.11 <sup>*</sup>	0.45 ± 0.09 <sup>*,†</sup>	0.28 ± 0.09	0.29 ± 0.08
SDI (%)	5.2 ± 4.1	9.0 ± 4.4 <sup>*</sup>	4.2 ± 4.2	2.9 ± 3.4

RV, regurgitant volume; ERO, effective regurgitant orifice; EDVI, end-diastolic volume index; ESVI, end-systolic volume index; SVI, systolic volume index; SDI, systolic dyssynchrony index. Other abbreviations were shown in Table 1. <sup>\*</sup>Significant difference ( $P < 0.05$ ) EMR vs. NEMR; <sup>†</sup> $P < 0.05$  peak vs. rest.

able to distinguish the two groups of patients. The 3D SDI was indeed identical in both groups. In contrast, at exercise, the 3D SDI raised more in the EMR group ( $P < 0.0001$ ) than in the NEMR patients. By stepwise multiple regression model, dynamic changes in SDI, in sphericity index, and in coaptation distance were associated with dynamic MR (generalized  $r^2 = 0.45$ ,  $P = 0.012$ ) (Table 3).

### Cofactors correlated with mitral regurgitation severity

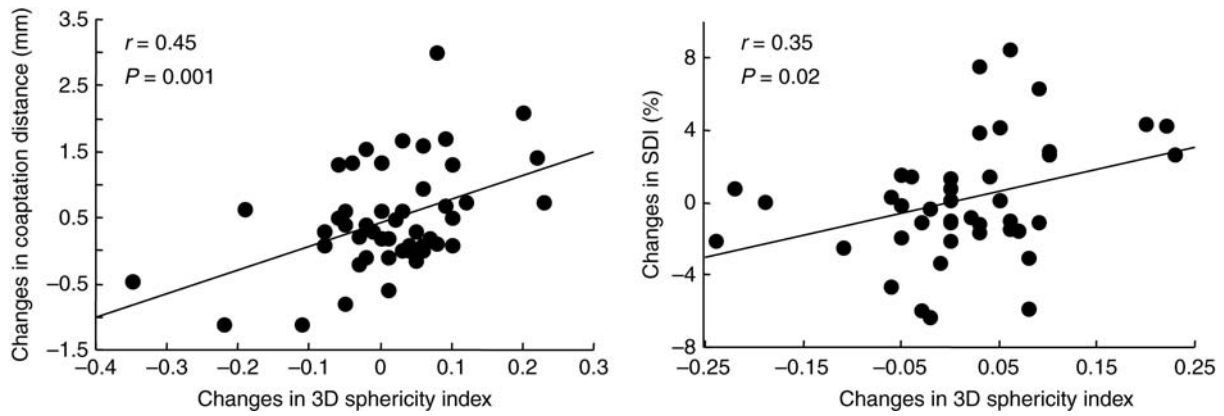
The exercise-induced LV spherical changes had weak correlations with the coaptation distance ( $r = 0.45$ ,  $P = 0.001$ ) and the SDI ( $r = 0.35$ ,  $P = 0.02$ ) (Figure 4). The

**Table 3** Predictors of dynamic mitral regurgitation

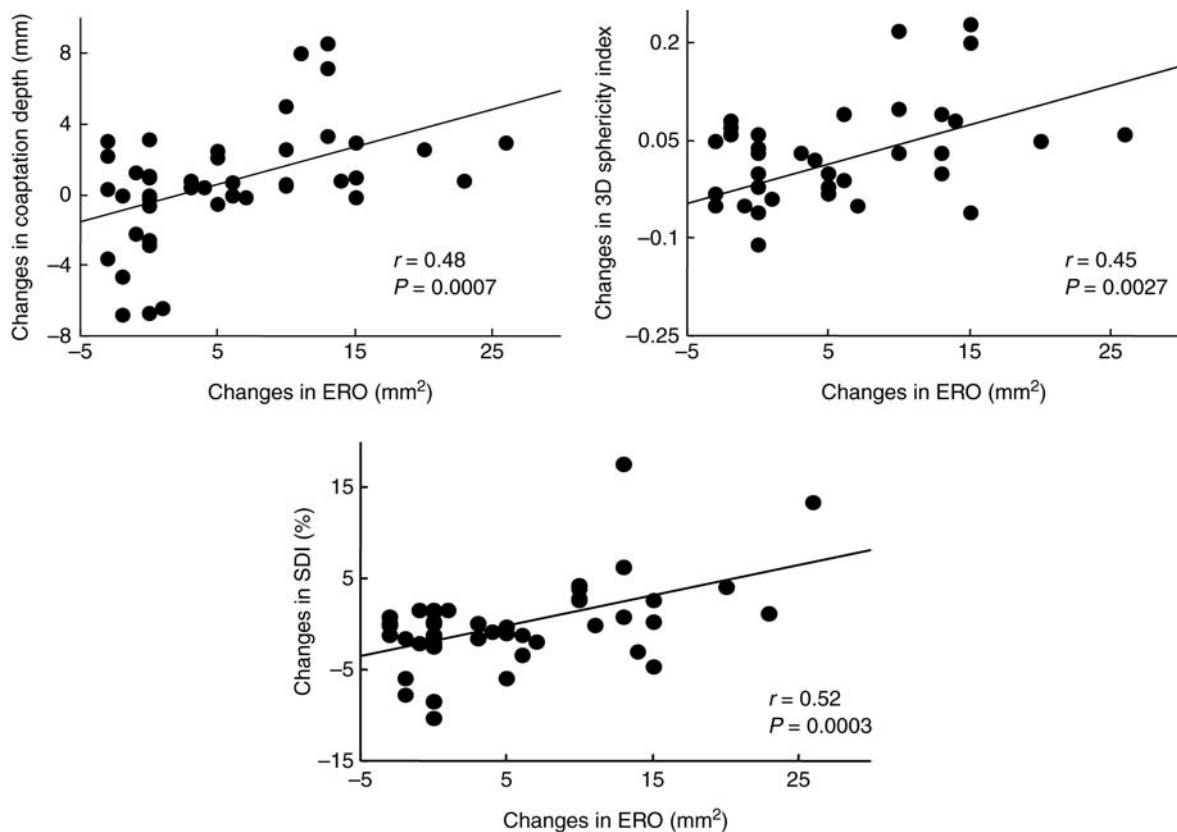
	$\beta$	95% CI for $\beta$	$P$ -value
Coaptation distance	0.721	0.13–1.31	0.018
Sphericity index	23.32	3.80–42.84	0.02
SDI	0.53	0.12–0.94	0.012

Abbreviation was shown in Table 2.

exercise-induced changes in ERO were related with those in coaptation distance ( $r = 0.48$ ,  $P = 0.0007$ ), the 3D sphericity index ( $r = 0.45$ ,  $P = 0.0027$ ), and the SDI ( $r = 0.52$ ,  $P = 0.0003$ ) (Figure 5).



**Figure 4** Relationship between the three-dimensional sphericity index and the changes in mitral valvular deformation and in left ventricular dyssynchrony. SDI, systolic dyssynchrony index.



**Figure 5** Relationship between the changes in mitral valvular deformation, three-dimensional sphericity index, left ventricular dyssynchrony, and the changes in ERO. SDI, systolic dyssynchrony index.

### Cut-off value for dynamic mitral regurgitation

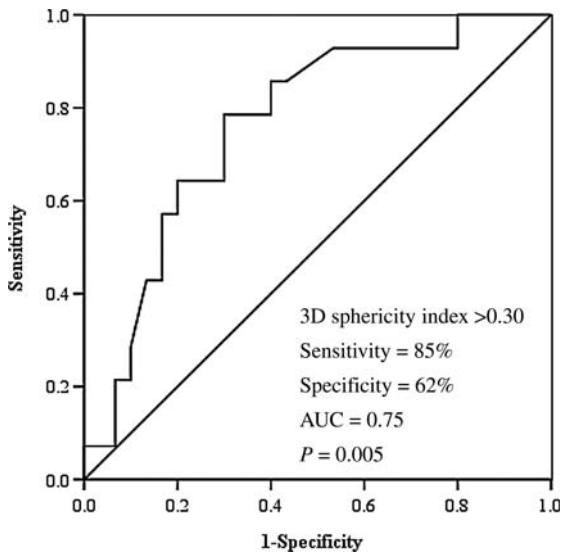
Receiver exercise echocardiography characteristics curve analysis yielded cut-off values of 3D sphericity index at rest  $>0.30$  best associated with EMR (Figure 6).

### Reproducibility of measurements

At rest and during exercise, there were good agreements for 2D and 3D echocardiographic measurements of LV volumes and shape (Table 4).

### Discussion

Functional MR is frequently observed in patients with systolic LV dysfunction; however, the mechanisms to determine its presence and severity have not been entirely elucidated. In the present study, we demonstrated for the first time that dynamic MR during exercise was related to the 3D changes in LV shape and in LV synchronicity. The acute exercise LV remodelling concomitantly with dynamic LV dyssynchrony accentuated mitral valve tethering triggered worsening of MR.



**Figure 6** Receiver exercise echocardiography of the three-dimensional sphericity index at rest of exercise-induced mitral regurgitation group. 3D, three-dimensional echocardiography; AUC, area under the curve.

**Table 4** Intra- and inter-observer agreement of rest and peak exercise: two- and three-dimensional echocardiography

	2DE		3DE	
	Rest	Peak	Rest	Peak
Intraobserver (%)	94	92	92	88
Interobserver (%)	88	86	88	84

2DE, two-dimensional echocardiography; 3DE, three-dimensional echocardiography.

### Left ventricular shape, mitral valve geometry, and mitral regurgitation

Normally, increased LV pressure acts to push the leaflets towards the left atrium, while tethering force of the chordae pulls the leaflets towards papillary muscles and prevent leaflet prolapse into the left atrium. Incomplete closure of normal mitral leaflets, the cause of functional MR, is in part due to complex distortion of ventricular geometry and of mitral valve apparatus. Progressive distortion of LV architecture leads to apical and lateral displacement of papillary muscles, which in turn causes tethering and restrictive motion of the mitral leaflets, thus contributes to mitral valvular miscoaptation. Global enlargement of the LV usually occurs in association with increased sphericity and annular dilatation, all contribute to MR. During exercise, it has been shown that LV geometry could be modified due to a lack of peripheral ability to decrease afterload. As cardiac function deteriorates along with increased LV size, LV shape changes from elliptical to globular, and the leaflet tethering increases. Lapu-Bula *et al.*<sup>9</sup> and Giga *et al.*<sup>16</sup> demonstrated that the exercise-induced LV sphericity provokes mitral valve deformation (tethering) and increases mitral tenting area through excessive leaflet tension, resulting in the exacerbation of functional MR. Thus, changes in regional loading conditions and a more

spherical LV shape during exercise directly contribute to changes in mitral valve configuration.

### Left ventricular asynchrony and mitral regurgitation

Dyssynchronized myocardial contraction deteriorates global LV performance and increases the extent of MR. The individual degree of LV asynchrony by increasing local leaflet tethering forces due to the asynchronous activation of the medial and lateral segments supporting the papillary muscles contributes to MR under resting conditions. Several authors have reported that exercise could alter the magnitude of ventricular dyssynchrony.<sup>10,17</sup> However, these studies examined LV dyssynchrony by using tissue Doppler imaging, a technique suffering from a limited feasibility in the setting of LV asynchrony (PROSPECT study).<sup>18</sup> In our present study, we used 3DE to assess LV dyssynchrony at rest and during exercise. Real-time 3DE has been shown to be an accurate and reproducible technique for detecting and quantifying LV dyssynchrony.<sup>19</sup> Recently, it has been suggested that LV dyssynchrony, even at rest, might affect the behaviour of MR in patients with systolic HF.<sup>20</sup> However, although LV dyssynchrony at rest was able to identify patients with dynamic MR, changes in its magnitude during exercise better correlated with the extent of changes in MR during test. Both LV dyssynchrony and dynamic MR could alter the stroke volume adaptation during exercise. Furthermore, LV dyssynchrony by decreasing mitral closing forces and increasing local tethering forces plays an important role in generating dynamic MR. These data were confirmed and extended in the present study. We also found that dynamic LV dyssynchrony was directly correlated with changes in 3D sphericity index, suggesting that LV geometry could influence LV synchronicity and vice versa.

### Clinical implication

Exercise echocardiography plays an important role, especially when a symptom appears regardless of the severity of underlying diseases. Ypenburg *et al.*<sup>21</sup> reported that the presence of baseline LV dyssynchrony was related to the improvement of MR after CRT. This study results indicated that exercise could alter the level of intraventricular dyssynchrony in the HF patients. If the assessment of dyssynchrony during exercise along with changes in MR and stroke volume is established, it will be useful to select candidates for cardiac resynchronization therapy which improve exercise-induced MR and exercise capacity. Furthermore, it is necessary to take surgical repair into account when a patient has exercise-induced MR after CRT. This study suggested that we aggressively considered exercise echocardiography in patients with LV spherical change.

### Study limitations

This study excluded the patients in New York Heart Association class IV who would have more severe dynamic LV dyssynchrony and MR. The echocardiographic measurements were performed at rest and during maximal symptom-limited exercise. It was uncertain what effects would be produced by a lesser degree of exertion. The dynamic changes in LV dyssynchrony were assessed using 3DE. We did not evaluate the strain and strain rate parameters.

Peteiro *et al.*<sup>22</sup> suggested that advantages of exercise 3DE would be lower acquisition time and the possibility of image multiple parallel planes in each view.

## Conclusions

3DE during exercise allows accurate assessment of the determinants of dynamic MR in patients with systolic HF. The increase in the magnitude of LV dyssynchrony and in LV geometry by altering the mitral valve forces generates exercise worsening of MR.

## Acknowledgements

We thank Satoshi Watanabe, Kazuhiro Izawa, Keiko Kohno, and the cardiac rehabilitation staff in the Department of Rehabilitation Medicine, St Marianna University Hospital, for their technical assistance in this study.

**Conflict of interest:** none declared.

## References

- Sullivan MJ, Knight D, Higginbotham MB, Cobb FR. Relation between central and peripheral hemodynamics during exercise in patients with chronic heart failure: muscle blood flow is reduced with maintenance of arterial perfusion pressure. *Circulation* 1989;**80**:769–81.
- Higginbotham MB, Morris KG, Williams RS, McHale PA, Coleman RE, Cobb FR. Regulation of stroke volume during submaximal and maximal upright exercise in normal man. *Circ Res* 1986;**58**:281–91.
- Higginbotham MB, Morris KG, Conn EH, Coleman RE, Cobb FR. Determinants of variable exercise performance among patients with severe left ventricular dysfunction. *Am J Cardiol* 1983;**51**:52–60.
- Ballester M, Jajoo J, Rickards A, McDonald L. The mechanism of mitral regurgitation in dilated left ventricle. *Clin Cardiol* 1983;**6**:333–8.
- Tanabe K, Ishibashi Y, Ohta T, Oyake N, Shimada T, Murakami R *et al.* Effect of left and right lateral decubitus positions on mitral flow pattern by Doppler echocardiography in congestive heart failure. *Am J Cardiol* 1993;**71**:751–3.
- Stevenson LW, Brunken RC, Belil D, Grover-MacKay M, Schwaiger M, Schelbert HR *et al.* Afterload reduction with vasodilators and diuretics decreases mitral regurgitation during upright exercise in advanced heart failure. *J Am Coll Cardiol* 1990;**15**:174–80.
- Stevenson LW, Bellil D, Grover-McKay M, Brunken RC, Schwaiger M, Tillisch JH *et al.* Effects of afterload reduction (diuretics and vasodilators) on left ventricular volume and mitral regurgitation in severe congestive heart failure secondary to ischemic or idiopathic dilated cardiomyopathy. *Am J Cardiol* 1987;**60**:654–8.
- Karen G, LeJemtel TH, Zelcer AA, Meisner JS, Bier A, Yellin EL. Time variation of mitral regurgitant flow in patients with dilated cardiomyopathy. *Circulation* 1986;**74**:684–92.
- Lapu-Bula R, Robert A, Van Craeynest D, D'Hondt AM, Gerber BL, Pasquet A *et al.* Contribution of exercise-induced mitral regurgitation to exercise stroke volume and exercise capacity in patients with left ventricular systolic dysfunction. *Circulation* 2002;**106**:1342–8.
- Lancellotti P, Stainier P-Y, Lebois F, Pierard LA. Effect of dynamic left ventricular dyssynchrony on mitral regurgitation in patients with heart failure due to coronary artery disease. *Am J Cardiol* 2005;**96**:1304–7.
- Lancellotti P, Troisfontaines P, Toussaint AC, Pierard LA. Prognostic importance of exercise-induced changes in mitral regurgitation in patients with chronic ischemic left ventricular dysfunction. *Circulation* 2003;**108**:1713–7.
- Borg G. Perceived exertion as an indicator of somatic stress. *Scand J Rehabil Med* 1970;**2**:92–8.
- Boltwood CM, Tei C, Wong M, Shah PM. Quantitative echocardiography of the mitral complex in dilated cardiomyopathy: the mechanism of functional mitral regurgitation. *Circulation* 1983;**68**:498–508.
- Mannaerts HF, van der Heide JA, Kamp O, Stoel MG, Twisk J, Visser CA. Early identification of left ventricular remodeling after myocardial infarction, assessed by transthoracic 3D echocardiography. *Eur Heart J* 2004;**25**:680–7.
- Takeuchi M, Jacobs A, Sugeng L, Nishikage T, Nakai H, Weinert L *et al.* Assessment of left ventricular dyssynchrony with real-time 3-dimensional echocardiography: comparison with Doppler tissue imaging. *J Am Soc Echocardiogr* 2007;**20**:1321–9.
- Giga V, Ostojic M, Vujisic-Tesic B, Djordjevic-Dikic A, Stepanovic J, Beleslin B *et al.* Exercise-induced changes in mitral regurgitation in patients with prior myocardial infarction and left ventricular dysfunction: relation to mitral deformation and left ventricular function and shape. *Eur Heart J* 2005;**26**:1860–5.
- Lafitte S, Bordachar P, Lafitte M, Garrigue S, Reuter S, Reant P *et al.* Dynamic ventricular dyssynchrony. An exercise-echocardiography study. *J Am Coll Cardiol* 2006;**47**:2253–9.
- Yu C, Abraham WT, Bax J, Chung E, Fedewa M, Ghio S *et al.* Predictors of response to cardiac resynchronization therapy (PROSPECT)—study design. *Am Heart J* 2005;**149**:600–5.
- Monaghan MJ. Role of real time 3D echocardiography in evaluating the left ventricle. *Heart* 2006;**92**:131–6.
- Ennezat PV, Maréchaux S, Le Tourneau T, Lamblin N, Bauters C, Van Belle E *et al.* Myocardial asynchronism is a determinant of changes in functional mitral regurgitation severity during dynamic exercise in patients with chronic heart failure due to severe left ventricular systolic dysfunction. *Eur Heart J* 2006;**27**:679–83.
- Ypenburg C, Lancellotti P, Tops LF, Boersma E, Bleeker GB, Holman ER *et al.* Mechanism of improvement in mitral regurgitation after cardiac resynchronization therapy. *Eur Heart J* 2008;**29**:757–65.
- Peteiro P, Piñon R, Perez L, Monserrat D, Perez A. Comparison of 2- and 3-dimensional exercise echocardiography for the detection of coronary artery disease. *J Am Soc Echocardiogr* 2007;**8**:959–67.