



# The year 2014 in the European Heart Journal— Cardiovascular Imaging: part II

**Bernhard L. Gerber<sup>1</sup>, Thor Edvardsen<sup>2,3</sup>, Luc A. Pierard<sup>4</sup>, Antti Saraste<sup>5</sup>,  
Juhani Knuuti<sup>5</sup>, Gerald Maurer<sup>6</sup>, Gilbert Habib<sup>7,8</sup>, and Patrizio Lancellotti<sup>4,9\*</sup>**

<sup>1</sup>Division of Cardiology, Department of Cardiovascular Diseases, Institut de Recherche Expérimentale et Clinique (IREC), Cliniques Universitaires St Luc, Université Catholique de Louvain, Brussels, Belgium; <sup>2</sup>Department of Cardiology, Oslo University Hospital, Rikshospitalet and University of Oslo, Oslo, Norway; <sup>3</sup>Centre of Cardiological Innovation, Oslo, Norway; <sup>4</sup>Avenue de l'hôpital, 1, Department of Cardiology, University of Liege Hospital, GIGA Cardiovascular Sciences, Heart Valve Clinic, Imaging Cardiology, CHU Sart Tilman, 4000 Liege, Belgium; <sup>5</sup>Turku PET Centre and Heart Center, Turku University Hospital and University of Turku, Kiinmylynkatu 4-8, 20520 Turku, Finland; <sup>6</sup>Division of Cardiology, Department of Internal Medicine II, Medical University of Vienna, Vienna, Austria; <sup>7</sup>Aix-Marseille Université, 13284 Marseille, France; <sup>8</sup>Department of Cardiology, La Timone Hospital, Bd Jean Moulin, 13005 Marseille, France; and <sup>9</sup>GVM Care and Research, E.S. Health Science Foundation, Lugo, RA, Italy

Received 11 August 2015; accepted after revision 12 August 2015

The European Heart Journal—Cardiovascular Imaging, created in 2012, has become a reference for publishing multimodality cardiovascular imaging scientific and review papers. The impressive 2014 impact factor of 4.105 confirms the important position of our journal. In this part, we summarize the most important studies from the journal's third year, with specific emphasis on cardiomyopathies, congenital heart diseases, valvular heart diseases, and heart failure.

## Keywords

Cardiomyopathies • Congenital heart diseases • Valvular heart diseases • Heart failure

## Cardiomyopathy

Cardiomyopathies have been discussed in several original papers. The first review article of Borgquist *et al.*<sup>1</sup> evaluated the diagnostic performance of imaging in arrhythmogenic right ventricular cardiomyopathy (ARVC). A significant proportion of patients with imaging-positive ARVC by cardiac magnetic resonance (CMR) did not fulfil echocardiographic ARVC 2010 criteria, suggesting that the traditional echocardiographic evaluation of subtle structural changes in the right ventricle may be less sensitive. Madonna *et al.*<sup>2</sup> highlighted the fundamental value of multimodality imaging in patients with Fabry's cardiomyopathy. Di Bella *et al.*<sup>3</sup> also reported that the latest improvements in non-invasive imaging diagnostic techniques with increased diagnostic power have led to a reduced need for biopsy in patients with cardiac amyloidosis. Similarly, Bossone *et al.*<sup>4</sup> demonstrated that an integrated multimodality imaging approach offers significant advantages in patients with Takotsubo cardiomyopathy (TTC). Several other studies also demonstrated the important role of CMR tissue characterization in patients with cardiomyopathies. Florian *et al.*<sup>5</sup> evaluated extravascular volume and late gadolinium enhancement (LGE) by CMR in 27 patients with Becker muscular dystrophy and demonstrated that 74% of muscular dystrophy patients had LGE, and that extravascular

volume in muscular dystrophy was higher than in controls. The presence of LGE correlated with low ejection fraction and low ejection fraction and high extracellular volume fraction were associated with arrhythmic events. Further in 139 patients with hypertrophic cardiomyopathy (HCM), Ellims *et al.* evaluated the phenotype and investigated links between genotype and phenotype. They observed that compared with healthy subjects those with HCM manifest lower post-contrast myocardial T1 times, suggestive of more diffuse myocardial fibrosis, and a greater quantity of LGE, consistent with more regional myocardial fibrosis.<sup>6</sup> Furthermore, HCM patients with an identifiable genetic mutation had evidence of significantly more regional, but less diffuse, myocardial fibrosis, than patients without mutations. They did not demonstrate significant associations between individual HCM mutations and specific phenotypic characteristics. Interestingly, Geske *et al.*<sup>7</sup> showed that the echocardiographic regional strain differences in genotyped HCM patients are dependent on septal morphology or thickness, but not on genotype. Also in patients with HCM, Gyllenhammar evaluated myocardial perfusion by phase-contrast mitral regurgitation (MR) in the coronary sinus at rest and during adenosine and compared it against healthy controls and patients at risk, but HCM.<sup>8</sup> They showed that young patients with HCM have significantly lower myocardial perfusion during adenosine compared with controls, this decrease is

\* Corresponding author: Tel: +32 4 366 71 94; Fax: +32 4 366 71 95. E-mail: plancellotti@chu.ulg.ac.be

Published on behalf of the European Society of Cardiology. All rights reserved. © The Author 2015. For permissions please email: journals.permissions@oup.com.

found in HCM patients without diastolic dysfunction or left ventricular (LV) outflow tract obstruction, and MP in young subjects at HCM risk is similar to controls.

Diabetic cardiomyopathy is defined as diastolic or systolic myocardial disease in the absence of valvular dysfunction, coronary artery disease, and hypertension. In young adults with Type 2 diabetes mellitus, diabetes duration and aortic distensibility are associated with diastolic dysfunction.<sup>9</sup> Whether medical treatment may revert these structural anomalies has been examined by Jellis et al. Surprisingly, spironolactone-induced changes in myocardial structure and diastolic properties in these patients were not associated with changes in collagen biomarkers or CMR T1 values.<sup>10</sup>

The pathophysiology of Takotsubo syndrome continues to be elusive. Whether myocardial hypoperfusion is the cause or a consequence of TTC has been evaluated in a rat model of stress-induced TTC. Redfors et al.<sup>11</sup> showed that apical perfusion was not impaired in the early phase of stress-induced TTC. In patients with TTC, the LV recovery consists of two components. The first component is a rapid systolic recovery with a minimal diastolic recovery, whereas the second component is a postponed diastolic recovery accompanied by a minor residual systolic recovery.<sup>12</sup>

LV non-compaction is a rare but challenging cardiomyopathy. Peters et al.<sup>13</sup> showed that LV twist, an important component of systolic function, as assessed by 2D speckle tracking echocardiography, was diminished in these patients through normal LV rotation. Cardiac resynchronization therapy (CRT) has become a mainstay in heart failure management, but still 30% of patients failed to respond to therapy. Although imaging plays an important role in heart failure patients, no standardized method has been shown to be superior to another to evaluate potential responders to CRT. Bakos et al.<sup>14</sup> showed that identifying and presenting a target segment for LV lead implantation in CRT is feasible preoperatively, using a bullseye plot with combined data from computed tomography (CT), CMR, and echocardiography (Figure 1). In 40 heart failure patients, Djordjevic Dikic et al.<sup>15</sup> demonstrated that preserved coronary flow reserve in patients with dilated cardiomyopathy is predictive of LV improvement after CRT implantation.

Finally, two papers emphasized the role of CMR in myocarditis. In the June issue of the journal, Lurz et al.<sup>16</sup> evaluated the incremental role of pericardial effusion to a comprehensive CMR imaging protocol, in 132 patients undergoing endomyocardial biopsy for the diagnosis of myocarditis. They found that pericardial effusion was a common finding on CMR imaging in patients with suspected myocarditis mainly in patients with a shorter duration of symptoms. However, the presence of PE was found to be not specific for the diagnosis of myocarditis and did not improve the overall diagnostic accuracy of cardiac MR for the diagnosis of myocarditis. In the October issue of the journal, Vermes et al.<sup>17</sup> reported in 37 patients referred for acute myocarditis the prognostic value of CMR for LV functional improvement. They found that patients with the Lake-Louise + criteria had significantly lower ejection fraction at baseline and follow-up, but was associated with improvement of dysfunction. Among these criteria, myocardial oedema on T2-weighted MR image was the strongest predictor of recovery, indicating that that recovery of dysfunction likely reflects recovery of reversibly injured myocardium.

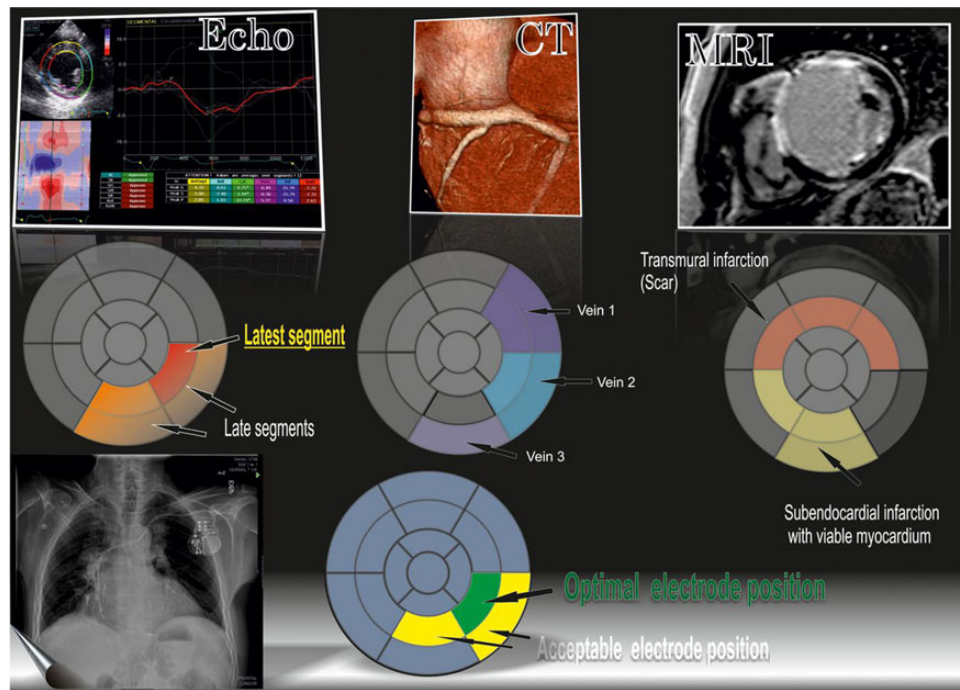
Cardiac CT is a well-established imaging modality for the assessment of coronary artery disease. CT has also recently emerged as a

valuable tool to examine myocardial pathology, due to its excellent patient compatibility and tolerability, high spatial resolution, and acceptable tissue characterization. Two review articles<sup>18,19</sup> highlighted the possibilities of cardiac CT in detecting myocardial pathology and evaluating structural abnormalities associated with cardiomyopathies and congenital heart diseases. This information should be kept in mind when performing coronary CT angiography and CT may also be useful in patients for whom other imaging techniques, particularly magnetic resonance imaging (MRI), are not suitable.

[18F]fluorodeoxyglucose (FDG) accumulation is increased in the right ventricular (RV) free wall of patients with pulmonary hypertension. The results of Tatebe et al.<sup>20</sup> indicate that enhanced FDG accumulation reflecting impaired RV substrate metabolism in the pressure overloaded RV free wall may be a prognostic factor in patients with pulmonary hypertension. In 27 patients and >5 years of follow-up, high RV standardized uptake value of FDG-positron emission tomography significantly predicted combined end-point of cardiovascular clinical worsening, including all-cause mortality, lung transplantation, hospitalization for the progression of pulmonary hypertension, and deterioration of WHO functional class and/or reduction in 6 min walking distance.

## Congenital heart disease

Several studies demonstrated the increasing role multimodality imaging in congenital heart disease. Orwat et al.<sup>19</sup> described, in an elegant review article, the current armamentarium of imaging tools available to the adult congenital heart disease cardiologist and put emphases on the usefulness of advanced imaging modalities. Menting et al.<sup>21</sup> performed speckle tracking echocardiography and cardiac MR in 82 patients with repaired tetralogy of Fallot. They observed that 29% of patients with tetralogy of Fallot had abnormal twist by speckle tracking echocardiography. This was associated with larger LV dimensions and decreased LV and RV systolic function and this suggests that such abnormal twist could be a new objective diagnostic criterion for detection of ventricular dysfunction. Jing et al.<sup>22</sup> used MR feature tracking computation of strains in patients with repaired tetralogy of Fallot and demonstrated that these patients had intra- and interventricular dyssynchrony related to their RV bundle branch block and that this dyssynchrony correlated with LV but not RV dysfunction. Bell et al.<sup>23</sup> evaluated the ability of real-time 3D echocardiography to assess RV function in 41 infants with hypoplastic left heart syndrome and compared these measurements with cardiac MR as reference method. They found that real-time 3D echocardiography was well correlated with CMR, and highly reproducible. However, the measurements obtained by 3D echocardiography were significantly lower than those obtained by CMR, with wide limits of agreement such that these two methods cannot be used interchangeably. Finally, Jimenez-Juan et al.<sup>24</sup> evaluated pregnancy outcomes in 28 women with aortic coarctation with respect to aortic morphometry by 3D-contrast enhanced MR angiography. They found that minimal aortic diameter related to the odds of developing a cardiovascular event during pregnancy, and that a minimum aortic diameter  $\leq 12$  mm was identified as an important anatomic determinant of adverse cardiovascular outcomes, and in particular hypertensive crisis. This aortic dimension may help



**Figure 1** Schematic representation of how the appropriate target segment for cardiac resynchronization was selected. Four bullseye plots together with colour coding. Plot (A) shows echocardiography data, the segment with latest mechanical activation is red, neighbouring segments with late activation are yellow and remote segments are grey. Plot (B) shows CT data, segments with one or more suitable vein branches are highlighted. Plot (C) shows MRI data, viable segments are grey, segments with non-transmural infarction (<50%) are yellow, and segments with transmural infarction ( $\geq 50\%$ ) are red. The final plot (D) shows the optimal segment (green), acceptable adjacent segments (yellow), and non-suitable or remote segments (grey). MRI, magnetic resonance imaging; CT, computed tomography. (From Bakos *et al.*<sup>14</sup>)

identify women at low risk of adverse events in pregnancy and those who would benefit from intervention prior to and/or heightened surveillance during pregnancy. Manganaro *et al.*<sup>25</sup> reviewed the literature about accessory mitral valve tissue, which is a rare congenital cardiac anomaly where an imaging plays a major diagnostic role. Labombarda *et al.*<sup>26</sup> highlighted the usefulness of trans-thoracic echocardiography for initial screening of major coronary anomalies in children and adults. However, when the diagnosis is made or suspected, the imaging work-up has to be completed by CT or CMR angiogram or coronary angiography. Atrial septal defect (ASD) is one of the most common congenital heart diseases in adults. Whether percutaneous closure of secundum ASD can affect left atrial (LA) mechanical functions has been examined by Aslan *et al.*<sup>27</sup> in 41 patients. The authors showed no change in the LA mechanical reservoir functions, but improved conduit function and impaired contractility functions early and in the mid-term after percutaneous closure of ASD.

## Valvular heart diseases

Several original articles have been published on valvular heart diseases. Secondary MR is frequent in patients with aortic stenosis. In a series of 172 patients, 63% of the patients had secondary MR. The association between the severity of aortic stenosis and effective regurgitant orifice was not significant. LV function was found to be a

main determinant of secondary MR, even in the patients in whom LV ejection function was preserved.<sup>28</sup>

Quantification of aortic regurgitation (AR), even when an integrated approach is used, remains difficult. There are several limitations in the assessment of quantitative parameters. In particular, when the proximal isovelocity surface area is used, a hemispheric assumption of the flow convergence zone is one of these limitations. Multi-beam high-pulse repetition frequency (HPRF) colour Doppler was used to quantify the vena contracta area in 29 patients with mild to severe AR. CMR was used as the standard of reference. The agreement between CMR and multi-beam HPRF colour Doppler was good in patients with severe or moderate AR but the agreement was modest for those with mild AR.<sup>29</sup>

CMR was compared with trans-thoracic echocardiography in 31 patients with isolated mitral stenosis in sinus rhythm. Good correlations between the two methods were found for the measurements of trans-mitral diastolic velocities and planimetric mitral valve area. CMR appears to be a reliable tool in patients with mitral stenosis.<sup>30</sup>

3D trans-thoracic echocardiography, using LV volumes was used for a quantitative assessment of primary MR. Regurgitant fraction was calculated from 2D echo or 3D LV volumes. The 3D method had a high feasibility of 90%. The inter-reader concordance for MR grading was excellent ( $\kappa$ -value of 0.90). The authors suggest that this parameter could be included in the multiparameter integrative approach for evaluating primary MR.<sup>31</sup>

3D transoesophageal echocardiography was performed in 72 patients with secondary MR. By measuring mitral annular area and leaflet area in early and late systole, the authors defined mitral annular area fractional change and coaptation index as the strongest predictors of MR. They emphasize the importance of LA dilatation that leads to mitral annular area enlargement, reduces leaflet coaptation, and produces MR.<sup>32</sup>

Two articles dealt with mechanical prosthetic valve dysfunction. A review paper based on a literature search included 238 mechanical prosthetic valves with obstruction with a reliable reference standard. Thromboses were characterized by leaflet restriction identified by fluoroscopy and mass detection by transoesophageal echo (TOE). When prosthetic valve obstruction related to a pannus, mass detection was absent in the majority of cases. The authors provided a diagnostic algorithm for correctly identifying patients with non-thrombotic prosthetic valve obstruction in whom thrombolysis is contraindicated.<sup>33</sup>

MitraClip implantation is increasingly used in high-risk patients with secondary MR. A study from Pisa included 35 patients who underwent percutaneous mitral valve repair. The procedure resulted in significantly reduced MR, improvement in LV size, and function at discharge. A further improvement at 6 months was observed. There was also a significant improvement in RV function: tricuspid annulus plane systolic excursion and systolic velocity at the tricuspid annulus increased significantly; the systolic pulmonary pressures were significantly reduced before discharge and at follow-up.<sup>34</sup>

Tricuspid regurgitation (TR) is frequently observed in patients with secondary MR. Percutaneous mitral valve repair was performed in 146 consecutive patients with secondary MR. The population was separated into two groups according to the degree of TR. The MitraClip implantation was associated with improvement in MR, TR, and functional class. However, moderate or severe TR predicted independently death and hospitalization for heart failure at 1 year.<sup>35</sup>

Although TOE is usually performed to guide septal puncture during percutaneous mitral commissurotomy, intracardiac echocardiography is another possible approach. TOE, aortic, and venous intracardiac echo were performed in 50 patients with mitral stenosis. It was shown that both the fossa ovalis and the tip of the needle were better visualized with aortic intracardiac echo which appears to be more reliable than venous intracardiac echo to facilitate transseptal puncture in patients with mitral stenosis.<sup>36</sup>

Transvenous lead extraction is increasingly required. It is a relatively safe procedure, although intractable haemodynamic instability can occur rarely. TOE was required in 26 patients. In 14 patients, life threatening cardiovascular injury was excluded by TOE. In 10 patients, pericardial effusion was diagnosed and 2 patients developed haemorrhagic shock. Rescue TOE helps to identify the aetiology of haemodynamic instability leading to appropriate intervention.<sup>37</sup>

Transcatheter aortic-valve implantation (TAVI) improves prognosis of high-risk patients with severe aortic stenosis. The effects of TAVI on LA and LV mechanics were studied in 54 consecutive patients. LV global and regional longitudinal deformation and LA function were determined by speckle tracking echocardiography. Global and regional LV and LA mechanics were improved; the effects were most pronounced in the patients with paradoxical low-flow.<sup>38</sup>

Calcium in the aortic-valve complex is predictive of paravalvular leak after TAVI. Jilaihawi et al.<sup>39</sup> optimized methodology for quantification of the aortic-valve calcium in 198 preoperative CT scans for the prediction of significant paravalvular leak after TAVI. Both leaflet and LVOT calcium were significant predictors of paravalvular leak, even in appropriately sized valves. However, the ability of calcium quantification to predict paravalvular leak after TAVI depends heavily on the thresholds set to detect calcium. With careful attention to these thresholds, clinically relevant leaflet calcium volumes can be identified with either non-contrast or contrast CT scans.

## Heart failure

It is well known that LA size provides prognostic information in various cardiovascular diseases. In a large series of CARDIA participants, LA size predicted clinical outcome, including myocardial infarction, heart failure, cerebrovascular disease, peripheral arterial disease, and atrial fibrillation. It was found that indexing LA size by height is at least as robust as by body surface area. LA size improves modestly discrimination over clinical parameters without altering risk classification.<sup>40</sup>

Non-longitudinal LV function can be assessed by mitral annular displacement or systolic velocity using M-mode, colour tissue Doppler imaging, and 2D strain imaging. A series of 168 patients with various cardiac anomalies were studied. Tissue Doppler imaging had the lowest observed variability and the authors concluded that this method seems to be the most robust tool.<sup>41</sup>

Non-invasive assessment of LV filling pressure is increasingly used in daily clinical practice by the ratio between trans-mitral E velocity and early diastolic velocities ( $e'$ ) usually by averaging of septal and lateral velocities. However, the  $E/e'$  ratio has limitations and has been challenged in patients with MR, preserved LV function, or advanced heart failure. Therefore, the EURO-FILLING study aims to compare simultaneous assessment of invasive and non-invasive measurements of LV filling pressure. This study will contribute to the standardization of this assessment.<sup>42</sup>

**Conflict of interest:** None declared.

## Funding

J.K. and A.S. have been financially supported by the Academy of Finland Centre of Excellence on Cardiovascular and Metabolic Diseases.

## References

- Borgquist R, Haugaa KH, Gilljam T, Bundgaard H, Hansen J, Eschen O et al. The diagnostic performance of imaging methods in ARVC using the 2010 Task Force criteria. *Eur Heart J Cardiovasc Imaging* 2014;**15**:1219–25.
- Madonna R, Cevik C, Cocco N. Multimodality imaging for pre-clinical assessment of Fabry's cardiomyopathy. *Eur Heart J Cardiovasc Imaging* 2014;**15**:1094–100.
- Di Bella G, Pizzino F, Minutoli F, Zito C, Donato R, Dattilo G et al. The mosaic of the cardiac amyloidosis diagnosis: role of imaging in subtypes and stages of the disease. *Eur Heart J Cardiovasc Imaging* 2014;**15**:1307–15.
- Bossone E, Lyon A, Citro R, Athanasiadis A, Meimoun P, Parodi G et al. Takotsubo cardiomyopathy: an integrated multi-imaging approach. *Eur Heart J Cardiovasc Imaging* 2014;**15**:366–77.
- Florian A, Ludwig A, Rösch S, Yildiz H, Sechtem U, Yilmaz A. Myocardial fibrosis imaging based on T1-mapping and extracellular volume fraction (ECV) measurement in muscular dystrophy patients: diagnostic value compared with conventional late gadolinium enhancement (LGE) imaging. *Eur Heart J Cardiovasc Imaging* 2014;**15**:1004–12.

6. Ellims AH, Illes LM, Ling L, Chong B, Macciocia I, Slavina GS *et al*. A comprehensive evaluation of myocardial fibrosis in hypertrophic cardiomyopathy with cardiac magnetic resonance imaging: linking genotype with fibrotic phenotype. *Eur Heart J Cardiovasc Imaging* 2014;**15**:1108–16.
7. Geske JB, Bos JM, Gersh BJ, Ommen SR, Eidem BW, Ackerman MJ. Deformation patterns in genotyped patients with hypertrophic cardiomyopathy. *Eur Heart J Cardiovasc Imaging* 2014;**15**:456–65.
8. Gyllenhammar T, Fernlund E, Jablonowski R, Jögi J, Engblom H, Liuba P *et al*. Young patients with hypertrophic cardiomyopathy, but not subjects at risk, show decreased myocardial perfusion reserve quantified with CMR. *Eur Heart J Cardiovasc Imaging* 2014;**15**:1350–7.
9. Khan JN, Wilmot EG, Leggate M, Singh A, Yates T, Nimmo M *et al*. Subclinical diastolic dysfunction in young adults with Type 2 diabetes mellitus: a multiparametric contrast-enhanced cardiovascular magnetic resonance pilot study assessing potential mechanisms. *Eur Heart J Cardiovasc Imaging* 2014;**15**:1263–9.
10. Jellis CL, Sacre JW, Wright J, Jenkins C, Haluska B, Jeffriess L *et al*. Biomarker and imaging responses to spironolactone in subclinical diabetic cardiomyopathy. *Eur Heart J Cardiovasc Imaging* 2014;**15**:776–86.
11. Redfors B, Shao Y, Wikström J, Lyon AR, Oldfors A, Gan L-M *et al*. Contrast echocardiography reveals apparently normal coronary perfusion in a rat model of stress-induced (Takotsubo) cardiomyopathy. *Eur Heart J Cardiovasc Imaging* 2014;**15**:152–7.
12. Ahtarovski KA, Iversen KK, Christensen TE, Andersson H, Grande P, Holmvang L *et al*. Takotsubo cardiomyopathy, a two-stage recovery of left ventricular systolic and diastolic function as determined by cardiac magnetic resonance imaging. *Eur Heart J Cardiovasc Imaging* 2014;**15**:855–62.
13. Peters F, Khandheria BK, Libhaber E, Maharaj N, Dos Santos C, Matioda H *et al*. Left ventricular twist in left ventricular noncompaction. *Eur Heart J Cardiovasc Imaging* 2014;**15**:48–55.
14. Bakos Z, Markstad H, Ostenfeld E, Carlsson M, Roijer A, Borgquist R. Combined preoperative information using a bullseye plot from speckle tracking echocardiography, cardiac CT scan, and MRI scan: targeted left ventricular lead implantation in patients receiving cardiac resynchronization therapy. *Eur Heart J Cardiovasc Imaging* 2014;**15**:523–31.
15. Djordjevic Dikic A, Nikcevic G, Raspopovic S, Jovanovic V, Tesic M, Beleslin B *et al*. Prognostic role of coronary flow reserve for left ventricular functional improvement after cardiac resynchronization therapy in patients with dilated cardiomyopathy. *Eur Heart J Cardiovasc Imaging* 2014;**15**:1344–9.
16. Lurz P, Eitel I, Klieme B, Luecke C, de Waha S, Desch S *et al*. The potential additional diagnostic value of assessing for pericardial effusion on cardiac magnetic resonance imaging in patients with suspected myocarditis. *Eur Heart J Cardiovasc Imaging* 2014;**15**:643–50.
17. Vermes E, Childs H, Faris P, Friedrich MG. Predictive value of CMR criteria for LV functional improvement in patients with acute myocarditis. *Eur Heart J Cardiovasc Imaging* 2014;**15**:1140–4.
18. Clayton B, Roobottom C, Morgan-Hughes G. Assessment of the myocardium with cardiac computed tomography. *Eur Heart J Cardiovasc Imaging* 2014;**15**:603–9.
19. Orwat S, Diller G-P, Baumgartner H. Imaging of congenital heart disease in adults: choice of modalities. *Eur Heart J Cardiovasc Imaging* 2014;**15**:6–17.
20. Tatebe S, Fukumoto Y, Oikawa-Wakayama M, Sugimura K, Satoh K, Miura Y *et al*. Enhanced [18F]fluorodeoxyglucose accumulation in the right ventricular free wall predicts long-term prognosis of patients with pulmonary hypertension: a preliminary observational study. *Eur Heart J Cardiovasc Imaging* 2014;**15**:666–72.
21. Menting ME, Eindhoven JA, van den Bosch AE, Cuyppers JAAE, Ruys TPE, van Dalen BM *et al*. Abnormal left ventricular rotation and twist in adult patients with corrected tetralogy of Fallot. *Eur Heart J Cardiovasc Imaging* 2014;**15**:566–74.
22. Jing L, Haggerty CM, Suever JD, Alhadad S, Prakash A, Cecchin F *et al*. Patients with repaired tetralogy of Fallot suffer from intra- and inter-ventricular cardiac dyssynchrony: a cardiac magnetic resonance study. *Eur Heart J Cardiovasc Imaging* 2014;**15**:1333–43.
23. Bell A, Rawlins D, Bellsham-Revell H, Miller O, Razavi R, Simpson J. Assessment of right ventricular volumes in hypoplastic left heart syndrome by real-time three-dimensional echocardiography: comparison with cardiac magnetic resonance imaging. *Eur Heart J Cardiovasc Imaging* 2014;**15**:257–66.
24. Jimenez-Juan L, Krieger EV, Valente AM, Geva T, Wintersperger BJ, Moshonov H *et al*. Cardiovascular magnetic resonance imaging predictors of pregnancy outcomes in women with coarctation of the aorta. *Eur Heart J Cardiovasc Imaging* 2014;**15**:299–306.
25. Manganaro R, Zito C, Khandheria BK, Cusmà-Piccione M, Chiara Todaro M, Oreto G *et al*. Accessory mitral valve tissue: an updated review of the literature. *Eur Heart J Cardiovasc Imaging* 2014;**15**:489–97.
26. Labombarda F, Coutance G, Pellissier A, Mery-Alexandre C, Roule V, Maragnes P *et al*. Major congenital coronary artery anomalies in a paediatric and adult population: a prospective echocardiographic study. *Eur Heart J Cardiovasc Imaging* 2014;**15**:761–8.
27. Aslan M, Erturk M, Turen S, Uzun F, Surgit O, Ozbay Ozyilmaz S *et al*. Effects of percutaneous closure of atrial septal defect on left atrial mechanical and conduction functions. *Eur Heart J Cardiovasc Imaging* 2014;**15**:1117–24.
28. Rossi A, Dandale R, Nistri S, Faggiano P, Cicoira M, Benfari G *et al*. Functional mitral regurgitation in patients with aortic stenosis: prevalence, clinical correlates and pathophysiological determinants: a quantitative prospective study. *Eur Heart J Cardiovasc Imaging* 2014;**15**:631–6.
29. Skaug TR, Amundsen BH, Hergum T, Urheim S, Torp H, Haugen BO. Quantification of aortic regurgitation using high-pulse repetition frequency three-dimensional colour Doppler. *Eur Heart J Cardiovasc Imaging* 2014;**15**:615–22.
30. Helvacioğlu F, Yildirimtürk O, Duran C, Yurdakul S, Tayyareci Y, Ulusoy OL *et al*. The evaluation of mitral valve stenosis: comparison of transthoracic echocardiography and cardiac magnetic resonance. *Eur Heart J Cardiovasc Imaging* 2014;**15**:164–9.
31. Maréchaux S, Le Goffic C, Ennezat P-V, Semichon M, Castel A-L, Delelis F *et al*. Quantitative assessment of primary mitral regurgitation using left ventricular volumes: a three-dimensional transthoracic echocardiographic pilot study. *Eur Heart J Cardiovasc Imaging* 2014;**15**:1133–9.
32. Ring L, Dutka DP, Wells FC, Fynn SP, Shapiro LM, Rana BS. Mechanisms of atrial mitral regurgitation: insights using 3D transoesophageal echo. *Eur Heart J Cardiovasc Imaging* 2014;**15**:500–8.
33. Tanis W, Habets J, van den Brink RBA, Symersky P, Budde RPJ, Chamuleau SAJ. Differentiation of thrombus from pannus as the cause of acquired mechanical prosthetic heart valve obstruction by non-invasive imaging: a review of the literature. *Eur Heart J Cardiovasc Imaging* 2014;**15**:119–29.
34. Giannini C, Petronio AS, De Carlo M, Guarracino F, Conte L, Fiorelli F *et al*. Integrated reverse left and right ventricular remodelling after MitraClip implantation in functional mitral regurgitation: an echocardiographic study. *Eur Heart J Cardiovasc Imaging* 2014;**15**:95–103.
35. Ohno Y, Attizzani GF, Capodanno D, Cannata S, Dipasqua F, Immé S *et al*. Association of tricuspid regurgitation with clinical and echocardiographic outcomes after percutaneous mitral valve repair with the MitraClip System: 30-day and 12-month follow-up from the GRASP Registry. *Eur Heart J Cardiovasc Imaging* 2014;**15**:1246–55.
36. Akkaya E, Vuruskan E, Zorlu A, Sincer I, Kucukosmanoglu M, Ardic I *et al*. Aortic intracardiac echocardiography-guided septal puncture during mitral valvuloplasty. *Eur Heart J Cardiovasc Imaging* 2014;**15**:70–6.
37. Hilberath JN, Burrage PS, Sherman SK, Varelmann DJ, Wilusz K, Fox JA *et al*. Rescue transoesophageal echocardiography for refractory haemodynamic instability during transvenous lead extraction. *Eur Heart J Cardiovasc Imaging* 2014;**15**:926–32.
38. Spethmann S, Baldenhofer G, Dreger H, Stüer K, Sanad W, Saghabalyan D *et al*. Recovery of left ventricular and left atrial mechanics in various entities of aortic stenosis 12 months after TAVI. *Eur Heart J Cardiovasc Imaging* 2014;**15**:389–98.
39. Jilaihawi H, Makkar RR, Kashif M, Okuyama K, Chakravarty T, Shiota T *et al*. A revised methodology for aortic-valvar complex calcium quantification for transcatheter aortic valve implantation. *Eur Heart J Cardiovasc Imaging* 2014;**15**:1324–32.
40. Armstrong AC, Liu K, Lewis CE, Sidney S, Colangelo LA, Kishi S *et al*. Left atrial dimension and traditional cardiovascular risk factors predict 20-year clinical cardiovascular events in young healthy adults: the CARDIA study. *Eur Heart J Cardiovasc Imaging* 2014;**15**:893–9.
41. De Kneegt MC, Biering-Sorensen T, Sogaard P, Sivertsen J, Jensen JS, Mogelvang R. Concordance and reproducibility between M-mode, tissue Doppler imaging, and two-dimensional strain imaging in the assessment of mitral annular displacement and velocity in patients with various heart conditions. *Eur Heart J Cardiovasc Imaging* 2014;**15**:62–9.
42. Galderisi M, Lancellotti P, Donal E, Cardim N, Edvardsen T, Habib G *et al*. European multicentre validation study of the accuracy of E/e' ratio in estimating invasive left ventricular filling pressure: EURO-FILLING study. *Eur Heart J Cardiovasc Imaging* 2014;**15**:810–6.