

## Aggressive tumor growth and clinical evolution in a patient with X-linked acro-gigantism syndrome

Luciana A. Naves<sup>1</sup> · Adrian F. Daly<sup>3</sup> · Luiz Augusto Dias<sup>9</sup> · Bo Yuan<sup>7</sup> · Juliano Coelho Oliveira Zakir<sup>1</sup> · Gustavo Barcellos Barra<sup>4</sup> · Leonor Palmeira<sup>3</sup> · Chiara Villa<sup>3,5</sup> · Giampaolo Trivellin<sup>10</sup> · Armindo Jreige Júnior<sup>1</sup> · Florêncio Figueiredo Cavalcante Neto<sup>2</sup> · Pengfei Liu<sup>7</sup> · Natalia S. Pellegata<sup>6</sup> · Constantine A. Stratakis<sup>10</sup> · James R. Lupski<sup>7,8,11,12</sup> · Albert Beckers<sup>3</sup>

Received: 28 August 2015 / Accepted: 6 November 2015  
© Springer Science+Business Media New York 2015

**Abstract** X-linked acro-gigantism (X-LAG) syndrome is a newly described disease caused by microduplications on chromosome Xq26.3 leading to copy number gain of *GPR101*. We describe the clinical progress of a sporadic male X-LAG syndrome patient with an Xq26.3 microduplication, highlighting the aggressive natural history of pituitary tumor growth in the absence of treatment. The patient first presented elsewhere aged 5 years 8 months with a history of excessive growth for >2 years. His height was 163 cm, his weight was 36 kg, and he had markedly elevated GH and IGF-1. MRI showed a non-invasive sellar mass measuring 32.5 × 23.9 × 29.1 mm. Treatment was declined and the family was lost to follow-up. At the age of 10 years and 7 months, he presented again with headaches, seizures, and visual disturbance. His height had increased to 197 cm. MRI showed an invasive mass measuring

56.2 × 58.1 × 45.0 mm, with compression of optic chiasma, bilateral cavernous sinus invasion, and hydrocephalus. His thyrotrope, corticotrope, and gonadotrope axes were deficient. Surgery, somatostatin analogs, and cabergoline did not control vertical growth and pegvisomant was added, although vertical growth continues (currently 207 cm at 11 years 7 months of age). X-LAG syndrome is a new genomic disorder in which early-onset pituitary tumorigenesis can lead to marked overgrowth and gigantism. This case illustrates the aggressive nature of tumor evolution and the challenging clinical management in X-LAG syndrome.

**Keywords** Giant · Pituitary adenoma · X-linked acro-gigantism syndrome · FIPA · GPR101

✉ Albert Beckers  
albert.beckers@chu.ulg.ac.be

Luciana A. Naves  
draluciananaves@gmail.com

<sup>1</sup> Department of Endocrinology, Faculty of Medicine, University of Brasilia, Brasilia, Brazil

<sup>2</sup> Department of Pathology, Faculty of Medicine, University of Brasilia, Brasilia, Brazil

<sup>3</sup> Departments of Endocrinology, Centre Hospitalier Universitaire de Liège, University of Liège, Domaine Universitaire du Sart-Tilman, 4000 Liège, Belgium

<sup>4</sup> Laboratorio Sabin de Análises Clínicas Brasilia, Brasilia, Brazil

<sup>5</sup> Department of Pathology, Hopital Foch, Suresnes Cedex, France

<sup>6</sup> Helmholtz Zentrum Munchen, Institute of Pathology, Neuherberg, Germany

<sup>7</sup> Departments of Molecular and Human Genetics, Baylor College of Medicine, Houston, TX, USA

<sup>8</sup> Department of Pediatrics, Baylor College of Medicine, Houston, TX, USA

<sup>9</sup> Department of Neurosurgery, Federal District Base Hospital, Brasilia, Brazil

<sup>10</sup> Section on Endocrinology and Genetics, Program on Developmental Endocrinology & Genetics & Pediatric Endocrinology Inter-Institute Training Program, Eunice Kennedy Shriver National Institute of Child Health & Human Development, National Institutes of Health (NIH), Bethesda, MD 20892, USA

<sup>11</sup> Texas Children's Hospital, Houston, TX, USA

<sup>12</sup> Human Genome Sequencing Center, Baylor College of Medicine, Houston, TX, USA

## Introduction

Increased stature in children is a complex clinical problem, running the gamut from the extremes of normal to a group of heterogeneous genetic disorders that require expert investigation [1, 2]. Some genetic overgrowth syndromes occur with features involving other organ systems (e.g., Beckwith-Wiedemann, Sotos, and Simpson-Golabi-Behmel syndromes). Classical pituitary gigantism due to GH hypersecretion occurs either as an isolated condition, or in familial isolated pituitary adenomas (FIPA), often in association with *AIP* gene mutations [3–7]. Gigantism also occurs as a component of endocrine tumor syndromes [3, 4, 8, 9].

Recently, we reported a novel early-childhood onset form of pituitary gigantism, X-linked acro-gigantism (X-LAG) syndrome (MIM#300942) [10]. X-LAG syndrome is associated with a microduplication on chromosome Xq26.3 that includes *GPR101* and can occur either sporadically or in the setting of FIPA (MIM#102200) [10, 11]. These cases become apparent usually within the first 12 months of life, when dramatically excessive physical growth is usually the first sign. Their management is complex as the anterior pituitary can be widely affected by adenomatous and hyperplastic changes and responses to traditional somatostatin analogs (e.g., octreotide) are poor [10, 11]. Hence, significant resection of the anterior pituitary is often undertaken, or debulking is combined with drugs such as pegvisomant [11].

The natural history of pituitary tumor evolution in X-LAG syndrome is not clear as patients are usually identified and operated on early. We report here a boy with pituitary gigantism due to X-LAG syndrome in whom treatment was refused by his family for a period of years, with dramatic consequences for his tumor progression.

## Methods

Clinical, hormonal, and radiological data were collected from first symptoms to the most recent presentation. Brief details of the patient were reported in [11]. Height and weight z-scores were calculated from normative data from [www.cdc.gov/growth](http://www.cdc.gov/growth) charts/z-scores. Informed consent for clinical and genetic studies was provided by the patient's legal guardian. The study was conducted in accordance with the guidelines of the Declaration of Helsinki and was approved by the Ethics Committee of the University of Brasilia.

### Array comparative genomic hybridization

Array comparative genome hybridization (aCGH) was performed using a standard clinical array, with further investigation using a customized, high-density  $8 \times 60$  K

array CGH (HD-aCGH) (Agilent Technologies) with high-density probes tiling the critical region inside Xq26.3 (ChrX: 135001882-136499429, hg19) to precisely determine the sizes, genomic boundaries, and gene contents of the rearrangements in the patient's genomic DNA, as previously described [10].

### Whole exome sequencing

Genomic DNA samples were fragmented, ligated to Illumina multiplexing paired-end adapters, amplified by a polymerase-chain-reaction assay with the use of primers, and hybridized to biotin-labeled VCRome, a solution-based exome capture reagent (Roche NimbleGen). Hybridization was performed at 7 °C for 64 to 72 h, and paired-end sequencing was performed on the Illumina NextSeq 500.

### Data analysis and interpretation

The output data from the Illumina NextSeq 500 were converted from a bcl to a FastQ file, by means of Illumina Consensus Assessment of Sequence and Variation software, version 1.8, and mapped into the reference haploid human-genome sequence (Genome Reference Consortium Human Genome), with the BWA program.

### Immunohistochemistry (IHC)

Specimens were fixed in 10 % formalin, and submitted to embedding in paraffin according to standard histological procedures. Hematoxylin and eosin staining was performed in all sections. Immunohistochemical evaluation (using Streptavidin–Biotin systems) included hormonal (GH, PRL, FSH, LH, TSH, ACTH), as well as prognostic marker profiles (Ki67, p53, c-erb). The antibodies used were anti-GH (polyclonal 1:2000), anti-PRL (polyclonal 1:2000), p-53 (DO7 1:100), Ki-67 (Mib 1 1:100), and c-erb B2 (oncoprotein C 1:400). Reactions were developed with diaminobenzidine and counter-stained with hematoxylin. Stainings for somatostatin receptor (SSTR) 2 and 5, GHRH-receptor, and AIP were performed as described previously [11].

## Results

### Clinical case

The patient was born by elective Caesarian section at 38 weeks; his birth length and weight were 2250 g and 48 cm, respectively. His family history was negative for growth disorders or pituitary disease. His mid-parental height was 176.5 cm. On chart review, overgrowth was

already established by the age of 2 years 7 months (Fig. 1a). The patient first presented symptomatically at another center aged 5 years and 8 months, at a height of 163 cm (+10.0 SD), and he was Tanner stage G<sub>1</sub> P<sub>1</sub>. At that time his bone age was 4 years, and hormonal testing revealed a random GH of 835 ng/ml (normal range <7) and an IGF-1 of 1035 ng/ml (normal range 84–235). MRI showed a heterogeneous intra- and suprasellar mass measuring 32.5 × 23.9 × 29.1 mm, with compression of the chiasma but no cavernous sinus invasion (Fig. 2a, b). The diagnosis of pituitary gigantism was made and the treatment recommendations were outlined, but the family declined treatment and was then lost to follow-up.

He presented again at the age of 10 years and 6 months. His growth had continued unabated and in the interim no medical attention was sought. He complained of headaches, seizures, and visual disturbance. On examination, his height had increased to 197 cm (+8.3 SD); he had kyphosis and evidence of intervertebral disc disease (Fig. 1b, c). His weight had, in contrast, fallen to the 90th percentile in association with malnutrition. His Tanner stage was G<sub>1</sub> P<sub>2</sub>, and there was no axillary hair. On examination he had excessive perspiration, acral enlargement, and facial changes (an enlarged, widened nose but no prognathism). Non-specific intellectual impairment had been noted in school. Visual examination showed bitemporal hemianopsia. Laboratory investigation confirmed GH/IGF-1 hypersecretion, and marked hyperprolactinemia was present. In addition, he had hypopituitarism of his thyrotrope, corticotrope, and gonadotrope axes. A repeat MRI showed an invasive intra- and suprasellar mass that had grown markedly to measure 56.2 × 58.1 × 45.0 mm, with compression of optic chiasma, cystic degeneration of suprasellar portion, bilateral cavernous sinus invasion, and encasement of internal carotids, with hydrocephalus (Fig. 2c, d).

The patient underwent transsphenoidal surgery to debulk his tumor mass (Fig. 2e, f). Postoperatively, he developed diabetes insipidus and his hypopituitarism persisted but the GH levels fell to 185 ng/ml; IGF-1 was 301.5 % of the upper limit of normal. In the post-operative period he continued to grow and he received lanreotide Autogel 120 mg/month, in combination with cabergoline. After 5 months of treatment, however, his GH levels remained elevated. Although his IGF-1 had decreased to nearly 79 % of the upper limit of normal, his vertical growth continued (205 cm; +8.7 SD). For this reason, it was determined that more profound IGF-1 suppression would be needed, and pegvisomant was added. This led to a further reduction in IGF-1 to <70 % of the upper limit of normal but by early October 2015 his height had continued to increase to 207 cm and again neither GH nor IGF-1 were controlled. As strict compliance with current medical

therapy (lanreotide Autogel 120 mg/month; cabergoline 2 mg/week; and pegvisomant 10 mg/day) could not be assured; further debulking surgery and radiotherapy are planned.

### Immunohistochemistry

Immunohistochemistry confirmed strong (+++) staining of the adenoma for GH and prolactin, and negative staining for FSH, LH, GH, TSH, and ACTH (Fig. 3). The Ki-67 labeling index was 3.5 %. p53 staining was positive in 10 % of cells and no membrane immunoreactivity for c-erbB2 was observed; AIP staining was strongly positive (data not shown). GHRH-R staining was also strongly positive, as was SSTR2 and SSTR5 immunostaining (immunoreactive score 10/10 for both; Fig. 3).

### Genetic analyses

The karyotype was normal (46XY). Using HD-aCGH, a copy number gain at Xq26.3 spanning approximately 0.656 Mb was observed. The genes included within the duplication copy number variant (CNV) include *VGLL1*, *MIR934*, *LOC100128420*, *CD40LG*, *ARHGEF6*, *RBMX*, *SNORD61*, and *GPR101*. On HD-aCGH and breakpoint junction sequencing, the microduplication was refined to chrX:135602028–136259908 (Fig. 4).

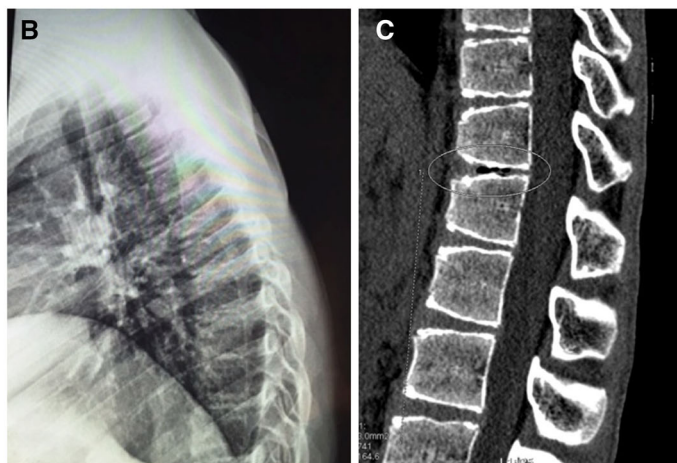
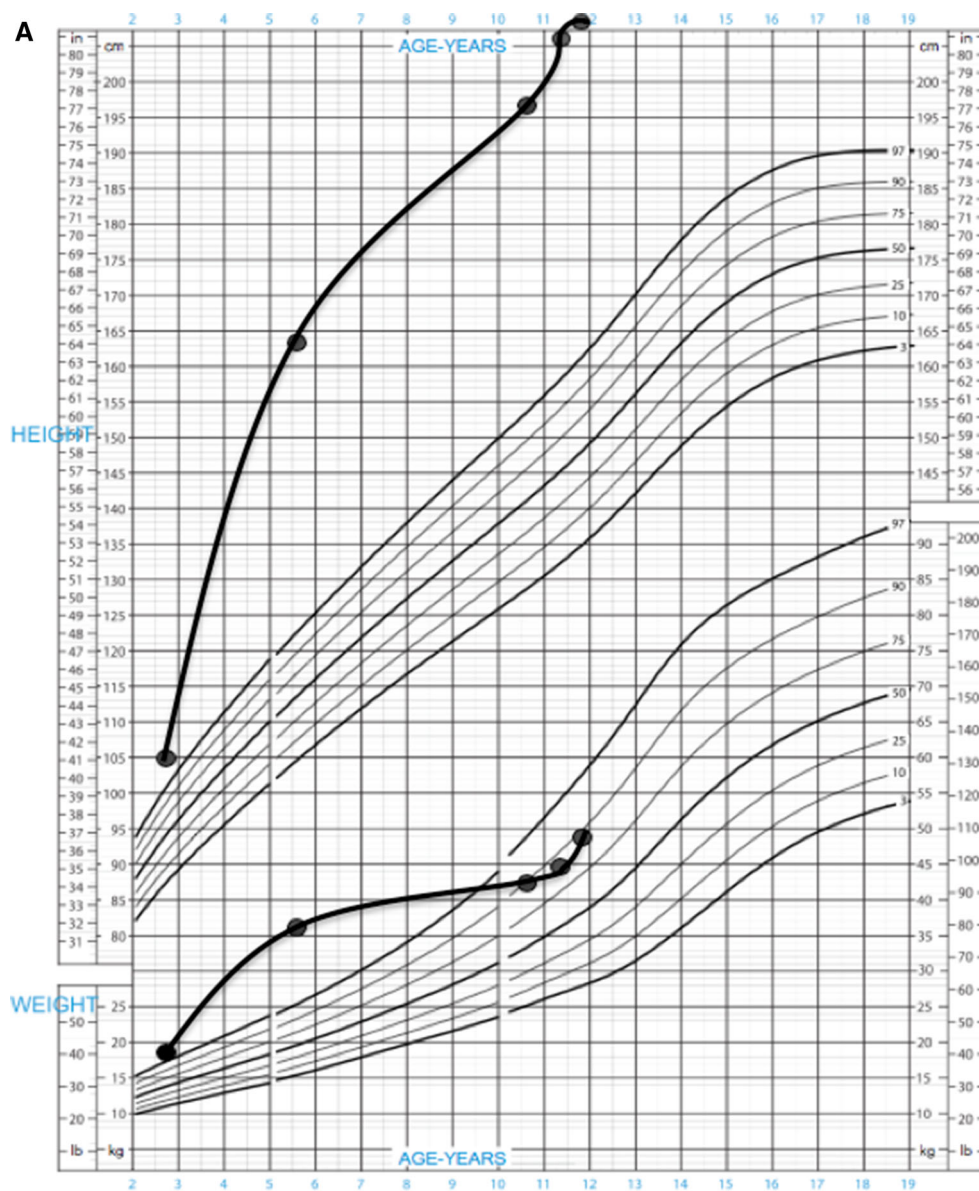
Whole exome capture using leukocyte DNA did not demonstrate relevant germline mutations in genes related to familial tumor pituitary syndromes (*MEN1*, *CDKN1B*, *AIP*, or *PRKARIA*) or of genes in the GH/IGF-1 signaling pathways. A heterozygous missense change in the *RET* gene and heterozygous missense variant in the *SSTR5* gene were observed.

### Discussion

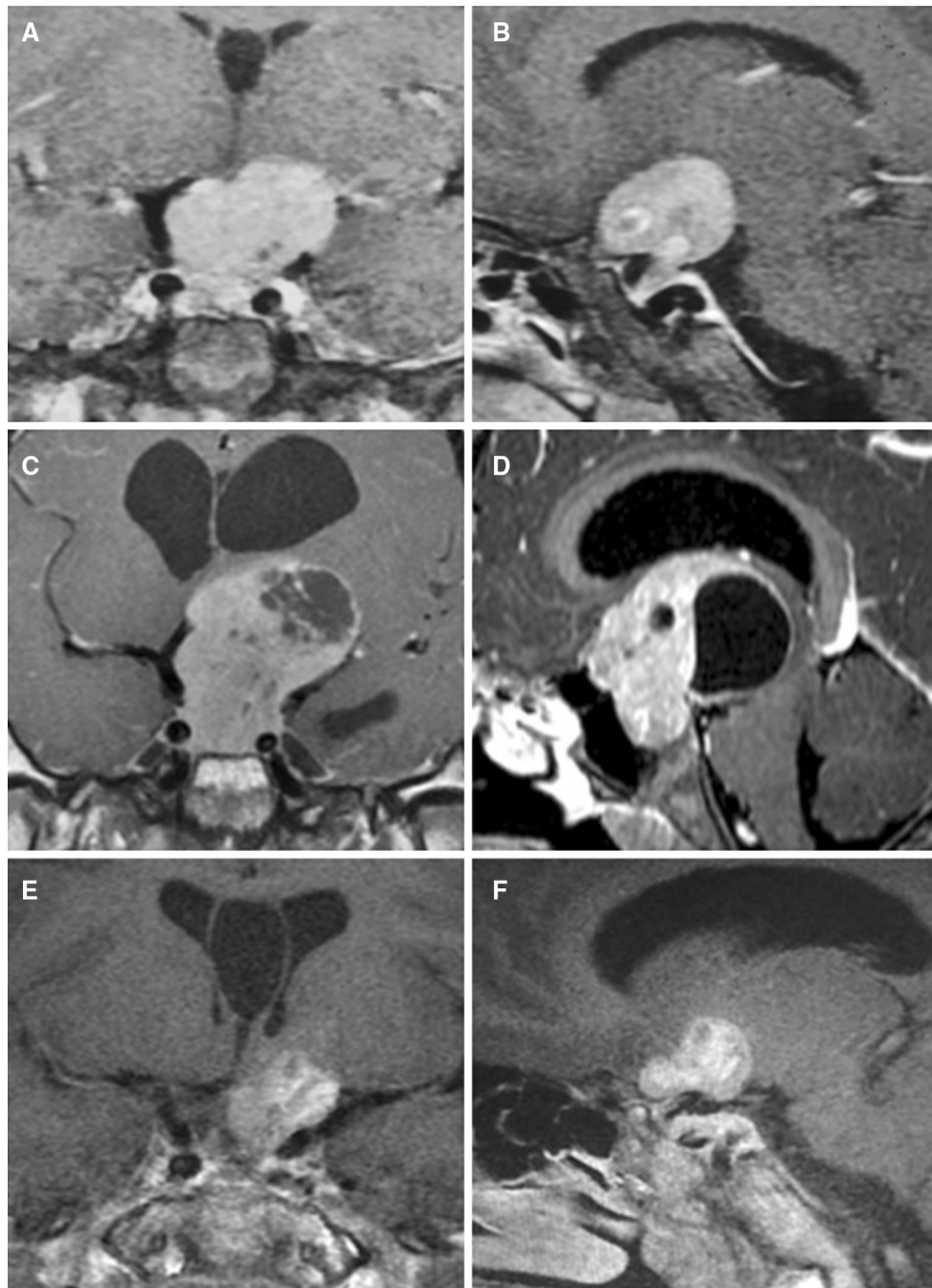Pituitary gigantism is a rare condition associated with excessive stature for age according to population normative values and is usually caused by GH excess from a pituitary GH secreting adenoma occurring during childhood and adolescence. A number of gene mutations have been shown to cause pituitary adenomas in childhood and pituitary gigantism [1]. *AIP* mutations are the most common known genetic cause in pituitary gigantism [4]. Gigantism patients with *AIP* mutations can present sporadically or within the setting of FIPA [5, 6, 12–16].

Recently, we described a new cause of pituitary gigantism, X-LAG syndrome, due to microduplications on chromosome Xq26.3 including the *GPR101* gene [10]. X-LAG syndrome has a well-defined phenotype of early-onset overgrowth due to mixed GH and prolactin-secreting

**Fig. 1 a** Growth chart of the patient, with excess height and weight already being established at the age of 2 years 7 months. The patient's height has remained excessive throughout this period, but his weight fell back into the normal range (90th percentile) due to poor nutrition, which has been addressed. **b** Lateral radiograph of the thoracic spine illustrating kyphosis. **c** Helical CT scan of the thoraco-lumbar region illustrating irregularities of the vertebral plateau and an intervertebral vacuum phenomenon (*circled*). Such vacuum phenomena are due to gas (nitrogen) accumulation from sources such as Schmorl node formation in juvenile kyphosis or osteoarthritis [19]





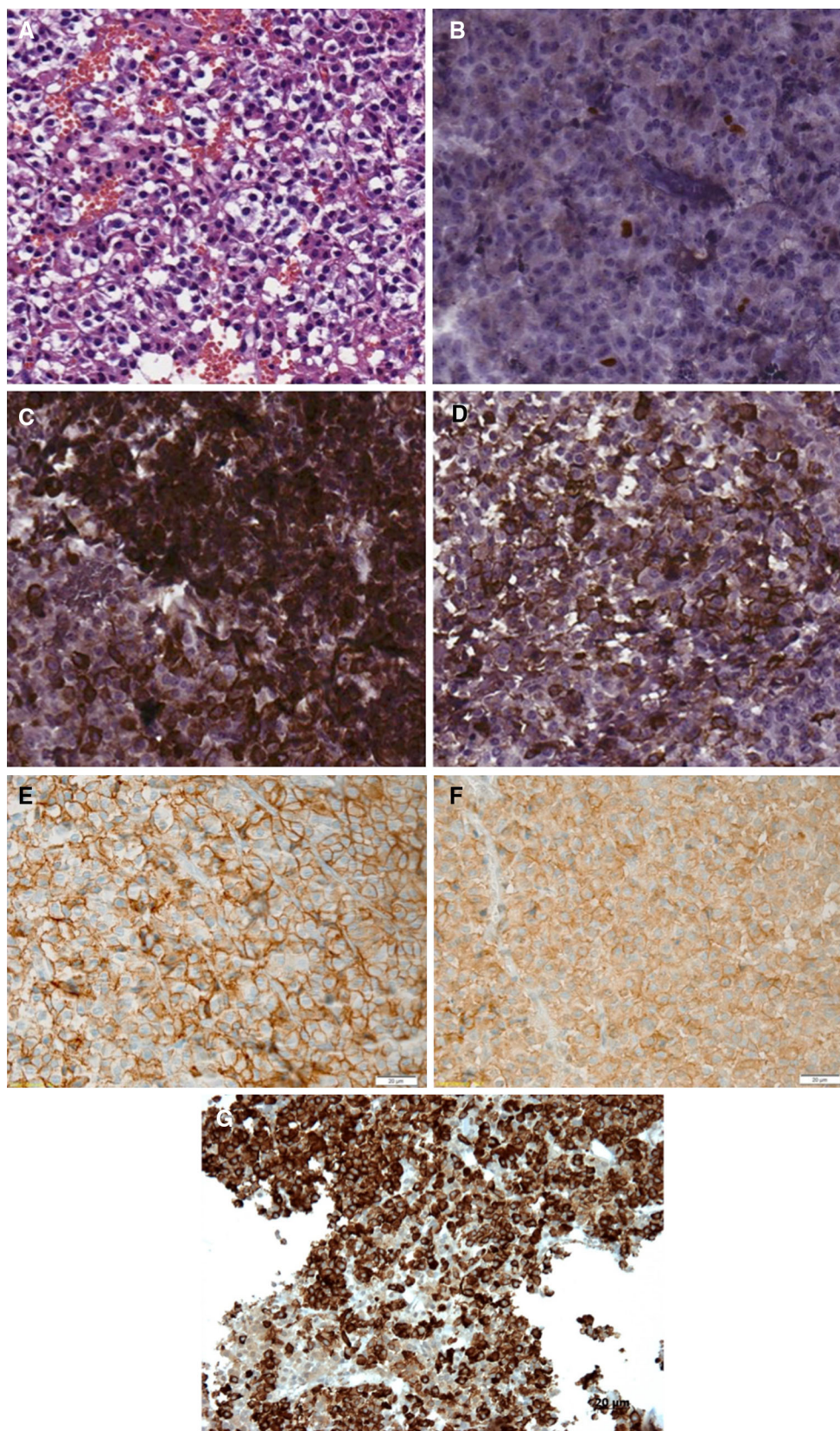


**Fig. 2** **a, b** Coronal and sagittal T1-weighted MRI taken at the first presentation (age of 5 years and 8 months) images showing large homogeneously enhanced pituitary macroadenoma, without cavernous sinus invasion or encasement of internal carotids. Coronal and sagittal T1-weighted MRI taken at age of 10 years. **c, d** Showing a marked increase in the size of the pituitary mass. The top of the tumor reaches the floor of the lateral ventricles, which are dilated. A

heterogeneous region of necrotic/degenerative change is seen principally in the upper part of the tumor. Coronal and sagittal T1-weighted MRI with contrast taken three months after surgical debulking. **e, f** Showing pituitary macroadenoma remnant with cystic degeneration and resolution of the hydrocephalus. An incidental cyst of the septum pellucidum is seen on multiple images

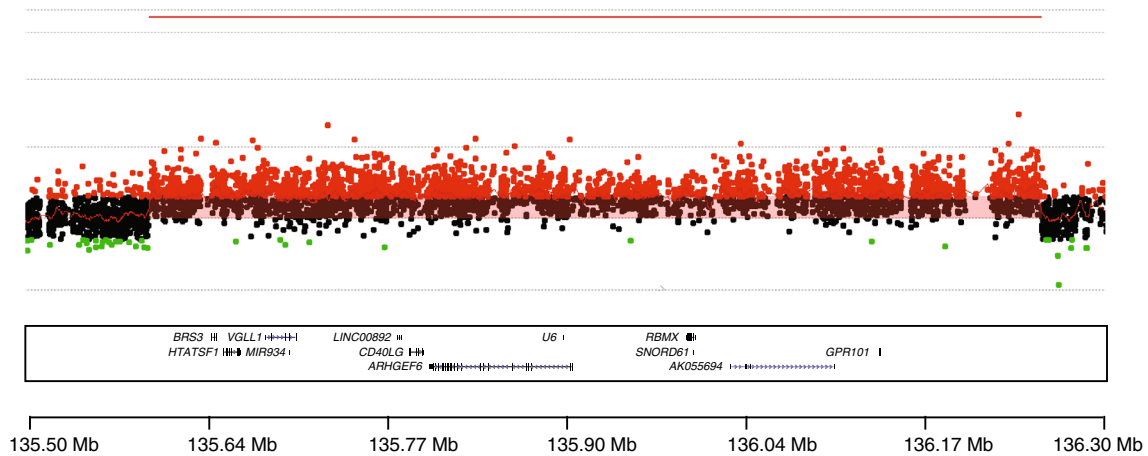
pituitary adenomas/hyperplasia that have a median age of diagnosis of about 36 months [11]. Up until now, the behavior of such tumors has been uncertain, as patients frequently underwent gross total resection or anterior

hypophysectomy at an early age. In the current report, due to an initial refusal of the recommended treatment options by the patient's family, we can confirm that tumor growth in X-LAG syndrome is aggressive and relentless.



**Fig. 3** Immunohistochemical (IHC) analysis showing a pituitary adenoma (a) with a Ki-67 index of 3.5 % (b) and with strong positivity for both GH (c) and prolactin (d). There was positivity for SSTR2 (e) and SSTR5 (f). The tumor was also strongly positive for the GHRH-receptor (g)





**Fig. 4** Chromosome Xq26.3 microduplication of the X-LAG syndrome patient. The region with the microduplication is shown by red probes and indicated by a continuous red line above the area denoting

increased copy number. The duplicated genes are shown at the bottom of the image alongside the location indicator

The patient had a very large macroadenoma by the time of the first MRI, when overgrowth had been documented since before the age of 3 years. The overgrowth as shown in Fig. 1 to the current height of 207 cm at the age of 11 years and 7 months was fuelled by the aggressive growth of underlying pituitary disease that secreted increasing levels of GH and IGF-1 over time. Immunohistochemical analyses confirmed the case as a mixed GH and PRL secreting adenoma (no hyperplasia was reported), as is typical in X-LAG syndrome. However, the Ki-67 was 3.5 % and >2 mitoses/high-power field were seen, both indicative of higher proliferation than in other X-LAG syndrome cases [11]. Despite the incomplete GH response to lanreotide, the SSTR2 staining was intact. The tumor was strongly positive for SSTR5 at a higher level than that seen previously in X-LAG syndrome cases. The high affinity of pasireotide for the SSTR5 receptor suggests that it might have clinical utility in such cases.

The behavior of the tumor and its profound effect on growth in this case underlines the importance of early intervention in X-LAG syndrome. Early effective treatment using surgery either alone or with pegvisomant can reduce GH/IGF-1 hypersecretion and arrest overgrowth in X-LAG syndrome and other forms of gigantism [11, 17, 18]. In this case, halting more vertical growth is vital given the history of unrestrained GH action on the skeleton allied with the fact that the patient is pre-pubertal and has panhypopituitarism. The increased stature is accompanied by a postural kyphosis and on helical CT scanning of the spine an intervertebral vacuum phenomenon was seen at the level of T11/T12. This finding, which is due to gas around the intervertebral discs and surroundings, is infrequently seen in children and can

indicate underlying pathology such as osteoarthritis or spinal deformity formation [19]. The current combination medical therapy has not proven effective in halting vertical growth and treatment is complicated by poor adherence to daily pegvisomant injections and cabergoline. A further neurosurgical intervention to grossly resect accessible tumor (in combination with radiotherapy) is envisaged, which may permit greater hormonal reductions and growth control with subsequent medical therapy. At that stage, efforts to induce epiphyseal closure could halt further worsening of his gigantism.

We studied the exome of the subject's germline DNA to screen for other genetic variants that could modify the phenotype (analogous work has been recently been shown for neuropathies [20]). Three variants were seen, one a heterozygotic missense change in *RET* (p.V648I; dbSNP rs77711105), which has been reported accompanying a pathological mutation (p.634R) in a MEN2A kindred [21]. This change is classified as benign using standard in silico software (e.g., SIFT), but as it is very rare (ExAC browser allele frequency:  $9.076 \times 10^{-05}$ ) and has been reported in various MEN2 cases, its status remains uncertain. The patient and family had no evidence of MEN2. However, he had suffered from lifelong severe constipation and subacute large intestine obstruction and has a working diagnosis of Hirschsprung disease (MIM#142623). There was a probably benign heterozygous missense variant (p.T9 M) in the *SSTR5* gene (rs143790659; ExAC browser allele frequency: 0.001259) that did not alter *SSTR5* protein expression in the pituitary adenoma. Finally, a rare heterozygotic missense variant in the *PEPD* gene (p.G448R; dbSNP rs121917724) that encodes peptidase D could have contributed to his intellectual disability [22].

In conclusion, X-LAG syndrome is a novel disorder of early-childhood pituitary gigantism due to duplications on chromosome Xq26.3 involving the *GPR101* gene. This case describes for the first time the natural aggressive behavior of pituitary disease in a patient with X-LAG syndrome, underlining the importance of early, effective diagnosis, and intervention.

**Acknowledgments** We thank Núcleo de Apoio a Pesquisa and Instituto Sabin in Brasilia-Brazil, for sample preparations and for performing hormonal studies; Drs. Luiz Augusto Casulari and Dr. Roberpaulo Barboza Filho, for clinical assistance; Ms Doralice Rabello from Pathology Department of University of Brasilia, for preparing tissue samples; Prof Jean Francois Bonneville for discussions on the neuroradiological findings; Dr. Misu Lee for discussion and analysis of somatostatin receptor studies. We thank the CNPq for support. This study was assisted in part by a grant from Fonds d'Investissement de Recherche Scientifique (FIRS) of the Centre Hospitalier Universitaire de Liège to Prof. Albert Beckers. This work was supported in part by grants from the US National Institute of Neurological Disorders and Stroke (NINDS; R01NS058529) to JRL and National Human Genome Research Institute (NHGRI)/National Heart Lung and Blood Institute (NHLBI) (U54 HG006542) to the Baylor-Hopkins Center for Mendelian Genomics.

#### Compliance with ethical standards

**Conflicts of interest** No potential conflict of interest relevant to this article was reported.

#### References

1. J.H. Davies, T. Cheetham, Investigation and management of tall stature. *Arch. Dis. Child.* **99**(8), 772–777 (2014). doi:[10.1136/archdischild-2013-304830](https://doi.org/10.1136/archdischild-2013-304830)
2. C.F. Verge, D. Mowat, Overgrowth. *Arch. Dis. Child.* **95**(6), 458–463 (2010). doi:[10.1136/adc.2009.157693](https://doi.org/10.1136/adc.2009.157693)
3. C.A. Stratakis, A giant? Think of genetics: growth hormone-producing adenomas in the young are almost always the result of genetic defects. *Endocrine* (2015). doi:[10.1007/s12020-015-0645-3](https://doi.org/10.1007/s12020-015-0645-3)
4. L. Rostomyan, A.F. Daly, P. Petrossians, E. Nachev, A.R. Lila, A.L. Lecoq, B. Lecumberri, G. Trivellin, R. Salvatori, A.G. Moraitis, I. Holdaway, D.J. Kranenburg-van Klaveren, M. Chiara Zatelli, N. Palacios, C. Nozieres, M. Zacharin, T. Ebeling, M. Ojaniemi, L. Rozhinskaya, E. Verrua, M.L. Jaffrain-Rea, S. Filipponi, D. Gusakov, V. Pronin, J. Bertherat, Z. Belaya, I. Ilovayskaya, M. Sahnoun-Fathallah, C. Sievers, G.K. Stalla, E. Castermans, J.H. Caberg, E. Sorkina, R.S. Auriemma, S. Mittal, M. Kareva, P.A. Lysy, P. Emy, E. De Menis, C.S. Choong, G. Mantovani, V. Bours, W. De Herder, T. Brue, A. Barlier, S.J. Neggers, S. Zacharieva, P. Chanson, N.S. Shah, C.A. Stratakis, L.A. Naves, A. Beckers, Clinical and genetic characterization of pituitary gigantism: an international collaborative study in 208 patients. *Endocr. Relat. Cancer* **22**(5), 745–757 (2015). doi:[10.1530/ERC-15-0320](https://doi.org/10.1530/ERC-15-0320)
5. A.F. Daly, A. Beckers, Familial isolated pituitary adenomas (FIPA) and mutations in the aryl hydrocarbon receptor interacting protein (AIP) gene. *Endocrinol. Metab. Clin. North Am.* **44**(1), 19–25 (2015). doi:[10.1016/j.ecl.2014.10.002](https://doi.org/10.1016/j.ecl.2014.10.002)
6. L.C. Hernandez, P. Gabrovskaya, J. Denes, K. Stals, G. Trivellin, D. Tilley, F. Ferrau, J. Evanson, S. Ellard, A.B. Grossman, F. Roncaroli, M.R. Gadelha, International FIPA Consortium, M. Korbonits, Landscape of familial isolated and young-onset pituitary adenomas: prospective diagnosis in AIP mutation carriers. *J. Clin. Endocrinol. Metab.* (2015). doi:[10.1210/jc.2015-1869](https://doi.org/10.1210/jc.2015-1869)
7. H.S. Chahal, K. Stals, M. Unterlander, D.J. Balding, M.G. Thomas, A.V. Kumar, G.M. Besser, A.B. Atkinson, P.J. Morrison, T.A. Howlett, M.J. Levy, S.M. Orme, S.A. Akker, R.L. Abel, A.B. Grossman, J. Burger, S. Ellard, M. Korbonits, AIP mutation in pituitary adenomas in the 18th century and today. *New Engl. J. Med.* **364**(1), 43–50 (2011). doi:[10.1056/NEJMoa1008020](https://doi.org/10.1056/NEJMoa1008020)
8. S. Sambugaro, M. Di Ruvo, M.R. Ambrosio, N.S. Pellegata, M. Bellio, A. Guerra, M. Buratto, M.P. Foschini, F. Tagliati, E. DegliUberti, M.C. Zatelli, Early onset acromegaly associated with a novel deletion in CDKN1B 5'UTR region. *Endocrine* **49**(1), 58–64 (2015). doi:[10.1007/s12020-015-0540-y](https://doi.org/10.1007/s12020-015-0540-y)
9. V. Vasilev, A.F. Daly, A. Thiry, P. Petrossians, F. Fina, L. Rostomyan, M. Silvy, A. Enjalbert, A. Barlier, A. Beckers, McCune-Albright syndrome: a detailed pathological and genetic analysis of disease effects in an adult patient. *J. Clin. Endocrinol. Metab.* **99**(10), E2029–E2038 (2014). doi:[10.1210/jc.2014-1291](https://doi.org/10.1210/jc.2014-1291)
10. G. Trivellin, A.F. Daly, F.R. Fauz, B. Yuan, L. Rostomyan, D.O. Larco, M.H. Scherthaner-Reiter, E. Szarek, L.F. Leal, J.H. Caberg, E. Castermans, C. Villa, A. Dimopoulos, P. Chittiboina, P. Xekouki, N. Shah, D. Metzger, P.A. Lysy, E. Ferrante, N. Strebkova, N. Mazerkina, M.C. Zatelli, M. Lodish, A. Horvath, R.B. de Alexandre, A.D. Manning, I. Levy, M.F. Keil, L. SierraMde, L. Palmeira, W. Coppieters, M. Georges, L.A. Naves, M. Jamar, V. Bours, T.J. Wu, C.S. Choong, J. Bertherat, P. Chanson, P. Kamenicky, W.E. Farrell, A. Barlier, M. Quezado, I. Bjelobaba, S.S. Stojilkovic, J. Wess, S. Costanzi, P. Liu, J.R. Lupski, A. Beckers, C.A. Stratakis, Gigantism and acromegaly due to Xq26 microduplications and GPR101 mutation. *N. Engl. J. Med.* **371**(25), 2363–2374 (2014)
11. A. Beckers, M.B. Lodish, G. Trivellin, L. Rostomyan, M. Lee, F.R. Fauz, B. Yuan, C.S. Choong, J.H. Caberg, E. Verrua, L.A. Naves, T.D. Cheetham, J. Young, P.A. Lysy, P. Petrossians, A. Cotterill, N.S. Shah, D. Metzger, E. Castermans, M.R. Ambrosio, C. Villa, N. Strebkova, N. Mazerkina, S. Gaillard, G.B. Barra, L.A. Casulari, S.J. Neggers, R. Salvatori, M.L. Jaffrain-Rea, M. Zacharin, B.L. Santamaria, S. Zacharieva, E.M. Lim, G. Mantovani, M.C. Zatelli, M.T. Collins, J.F. Bonneville, M. Quezado, P. Chittiboina, E.H. Oldfield, V. Bours, P. Liu, W. WdH, N. Pellegata, J.R. Lupski, A.F. Daly, C.A. Stratakis, X-linked acro-gigantism syndrome: clinical profile and therapeutic responses. *Endocr. Relat. Cancer* **22**(3), 353–367 (2015). doi:[10.1530/ERC-15-0038](https://doi.org/10.1530/ERC-15-0038)
12. A.F. Daly, M.A. Tichomirowa, P. Petrossians, E. Heliovaara, M.L. Jaffrain-Rea, A. Barlier, L.A. Naves, T. Ebeling, A. Karhu, A. Raappana, L. Cazabat, E. De Menis, C.F. Montanana, G. Raverot, R.J. Weil, T. Sane, D. Maiter, S. Neggers, M. Yaneva, A. Tabarin, E. Verrua, E. Eloranta, A. Murat, O. Vierimaa, P.I. Salmela, P. Emy, R.A. Toledo, M.I. Sabate, C. Villa, M. Popelier, R. Salvatori, J. Jennings, A.F. Longas, J.I. LabartaAizpun, M. Georgitsi, R. Paschke, C. Ronchi, M. Valimaki, C. Saloranta, W. De Herder, R. Cozzi, M. Guitelman, F. Magri, M.S. Lagonigro, G. Halaby, V. Corman, M.T. Hagelstein, J.F. Vanbellighen, G.B. Barra, A.P. Gimenez-Roqueplo, F.J. Cameron, F. Borson-Chazot, I. Holdaway, S.P. Toledo, G.K. Stalla, A. Spada, S. Zacharieva, J. Bertherat, T. Brue, V. Bours, P. Chanson, L.A. Aaltonen, a Beckers, Clinical characteristics and therapeutic responses in patients with germ-line AIP mutations and pituitary adenomas: an international collaborative study. *J. Clin. Endocrinol. Metab.* **95**(11), E373–E383 (2010). doi:[10.1210/jc.2009-2556](https://doi.org/10.1210/jc.2009-2556)
13. J.E. Jennings, M. Georgitsi, I. Holdaway, A.F. Daly, M. Tichomirowa, A. Beckers, L.A. Aaltonen, A. Karhu, F.J. Cameron, Aggressive pituitary adenomas occurring in young patients in a large Polynesian kindred with a germline R271 W mutation in



- the AIP gene. *Eur. J. Endocrinol./Eur. Fed. Endocr. Soc.* **161**(5), 799–804 (2009). doi:[10.1530/EJE-09-0406](https://doi.org/10.1530/EJE-09-0406)
14. L.A. Naves, A.F. Daly, J.F. Vanbellinthen, L.A. Casulari, C. Spilioti, A.V. Magalhaes, M.F. Azevedo, L.A. Giacomini, P.P. Nascimento, R.O. Nunes, J.W. Rosa, M.L. Jaffrain-Rea, V. Bours, A. Beckers, Variable pathological and clinical features of a large Brazilian family harboring a mutation in the aryl hydrocarbon receptor-interacting protein gene. *Eur. J. Endocrinol./Eur. Fed. Endocr. Soc.* **157**(4), 383–391 (2007). doi:[10.1530/EJE-07-0533](https://doi.org/10.1530/EJE-07-0533)
  15. C. Personnier, L. Cazabat, J. Bertherat, S. Gaillard, J.C. Souberbielle, J.L. Habrand, C. Dufour, E. Clauser, C. SainteRose, M. Polak, Clinical features and treatment of pediatric somatotropinoma: case study of an aggressive tumor due to a new AIP mutation and extensive literature review. *Horm. Res. paediatr.* **75**(6), 392–402 (2011). doi:[10.1159/000327831](https://doi.org/10.1159/000327831)
  16. F. Williams, S. Hunter, L. Bradley, H.S. Chahal, H.L. Storr, S.A. Akker, A.V. Kumar, S.M. Orme, J. Evanson, N. Abid, P.J. Morrison, M. Korbonits, A.B. Atkinson, Clinical experience in the screening and management of a large kindred with familial isolated pituitary adenoma due to an aryl hydrocarbon receptor interacting protein (AIP) mutation. *J. Clin. Endocrinol. Metab.* **99**(4), 1122–1131 (2014). doi:[10.1210/jc.2013-2868](https://doi.org/10.1210/jc.2013-2868)
  17. M. Rix, P. Laurberg, A.S. Hoejberg, B. Brock-Jacobsen, Pegvisomant therapy in pituitary gigantism: successful treatment in a 12-year-old girl. *Eur. J. Endocrinol./Eur. Fed. Endocr. Soc.* **153**(2), 195–201 (2005). doi:[10.1530/eje.1.01956](https://doi.org/10.1530/eje.1.01956)
  18. K. Mussig, B. Gallwitz, J. Honegger, C.J. Strasburger, M. Bidlingmaier, F. Machicao, A. Bornemann, M.B. Ranke, H.U. Haring, S. Petersenn, Pegvisomant treatment in gigantism caused by a growth hormone-secreting giant pituitary adenoma. *Exp. Clin. Endocrinol. Diabet.* **115**(3), 198–202 (2007). doi:[10.1055/s-2007-956172](https://doi.org/10.1055/s-2007-956172)
  19. B. Coulier, The spectrum of vacuum phenomenon and gas in spine. *JBR-BTR* **87**(1), 9–16 (2004)
  20. C. Gonzaga-Jauregui, T. Harel, T. Gambin, M. Kousi, L.B. Griffin, L. Francescato, B. Ozes, E. Karaca, S.N. Jhangiani, M.N. Bainbridge, K.S. Lawson, D. Pehlivan, Y. Okamoto, M. Withers, P. Mancias, A. Slavotinek, P.J. Reitnauer, M.T. Goksungur, M. Shy, T.O. Crawford, M. Koenig, J. Willer, B.N. Flores, I. Padiatrakis, O. Us, W. Wiszniewski, Y. Parman, A. Antonellis, D.M. Muzny, Baylor-Hopkins Center for Mendelian Genomics, N. Katsanis, E. Battaloglu, E. Boerwinkle, R.A. Gibbs, J.R. Lupski, Exome sequence analysis suggests that genetic burden contributes to phenotypic variability and complex neuropathy. *Cell Rep.* **12**, 1169–1183 (2015)
  21. A.B. Nunes, M.C. Ezabella, A.C. Pereira, J.E. Krieger, S.P. Toledo, A novel Val648Ile substitution in RET protooncogene observed in a Cys634Arg multiple endocrine neoplasia type 2A kindred presenting with an adrenocorticotropin-producing pheochromocytoma. *J. Clin. Endocrinol. Metab.* **87**(12), 5658–5661 (2002). doi:[10.1210/jc.2002-020345](https://doi.org/10.1210/jc.2002-020345)
  22. C. Ferreira, H. Wang, Prolidase deficiency, ed. by R.A. Pagon, M.P. Adam, H.H. Ardinger, S.E. Wallace, A. Amemiya, L.J.H. Bean, T.D. Bird, C.T. Fong, R.J.H. Smith, K. Stephens GeneReviews(R) (University of Washington, Seattle, 1993)