

The year 2014 in the *European Heart Journal – Cardiovascular Imaging*. Part I

Thor Edvardsen^{1,2}, Chiara Bucciarelli-Ducci³, Antti Saraste⁴, Luc A. Pierard⁵, Juhani Knuuti⁴, Gerald Maurer⁶, Gilbert Habib^{7,8}, and Patrizio Lancellotti^{5,9*}

¹Department of Cardiology, Oslo University Hospital, Rikshospitalet and University of Oslo, Oslo, Norway; ²Centre of Cardiological Innovation, Oslo, Norway; ³Bristol Heart Institute, NIHR Bristol Cardiovascular Biomedical Research Unit, University of Bristol, Bristol, UK; ⁴Turku PET Centre and Heart Center, Turku University Hospital and University of Turku, Kiinmyllykatu 4-8, 20520 Turku, Finland; ⁵Department of Cardiology, University of Liege Hospital, GIGA Cardiovascular Sciences, Heart Valve Clinic, Imaging Cardiology, CHU du Sart Tilman, Liege 4000, Belgium; ⁶Division of Cardiology, Department of Internal Medicine II, Medical University of Vienna, Vienna, Austria; ⁷Aix-Marseille Université, Marseille 13284, France; ⁸Department of Cardiology, La Timone Hospital, Bd Jean Moulin, Marseille 13005, France; and ⁹GVM Care and Research, E.S. Health Science Foundation, Lugo (RA), Italy

Received 13 May 2015; accepted after revision 15 May 2015

The new multimodality cardiovascular imaging journal, *European Heart Journal – Cardiovascular Imaging*, was created in 2012. It has already gained an impressive impact factor of 3.669 during its first 2 years. In two articles, we will summarize the most important studies from the journal's third year. Part I of the review will focus on studies in myocardial function, myocardial ischaemia, and emerging techniques in cardiovascular imaging, and Part II will focus on valvular heart diseases, heart failure, cardiomyopathies, and congenital heart diseases.

Keywords

echocardiography • single-photon emission computed tomography • myocardial ischaemia • cardiac magnetic resonance • myocardial function • computed tomography

Introduction

The multimodality *European Heart Journal – Cardiovascular Imaging* has successfully transitioned from an exclusive echocardiographic journal 3 years ago. The journal now serves as an important resource for general cardiologists, specialists in all imaging modalities, and other physicians working in the field of cardiovascular imaging. The tradition of highlighting the most important studies that were published in the last year editions is continued.^{1–3} In two articles, we will summarize the most important papers from the journal in 2014. Part I is focused on studies in myocardial function, myocardial ischaemia, and emerging techniques in cardiovascular imaging.

Recommendations from the European Association of Cardiovascular Imaging

The main task of *European Heart Journal – Cardiovascular Imaging* is to publish scientific articles. Another important assignment for the journal is to publish position papers, recommendations, and expert consensus papers from the European Association of Cardiovascular Imaging (EACVI). The journal published three recommendations in the field of multimodality imaging.^{4–6}

Cancer therapeutics have for long time been known to potentially cause Cancer therapeutics-related cardiac dysfunction. The EACVI and the American Society of Echocardiography have published for the first time in 2014 an expert consensus article about multimodality imaging evaluation of adult patients during and after cancer therapy.⁶ A position paper on multimodality imaging in pericardial diseases highlighted the respective role of each technique according to the clinical context in the diagnosis and management of pericardial diseases.⁵ A dedicated Taskforce has been appointed by the European Society of Cardiology and the EACVI to develop appropriateness criteria for cardiovascular imaging use in clinical practice in Europe.⁴ The published paper in 2014 described the development process of these appropriateness criteria in Europe.⁷

In 2014, the EACVI has also published three recommendation articles on echocardiographic topics.^{8–10} The collection of echocardiographic recommendation papers published in 2014 consists of an update of the use transoesophageal echocardiography (TOE) with particular focus on areas of interventional TOE, including transcatheter aortic, mitral, and left atrial (LA) appendage interventions, as well as on the role of TOE in infective endocarditis, adult congenital heart disease, and aortic disease.⁸ One article addressed the EACVI's viewpoint on the concept of point-of-care, problem-oriented focus cardiac ultrasound examination.⁹ The last echocardiographic paper updated the EACVI standards and processes for accreditation of echocardiographic laboratories.¹⁰

* Corresponding author. Tel: +32 4 366 71 94; Fax: +32 4 366 71 95, E-mail address: plancellotti@chu.ulg.ac.be

Published on behalf of the European Society of Cardiology. All rights reserved. © The Author 2015. For permissions please email: journals.permissions@oup.com.

The official EACVI Core Syllabus for the European Cardiovascular Magnetic Resonance Certification Exam was also published in 2014.¹¹

A highly valued editorial written by the deceased former editor-in-chief of the *European Journal of Echocardiography*, Professor Jos R.T.C. Roelandt, asked if echocardiography was to blame for the decline of our physical examination skills.¹² He concluded that future generations of doctors would find it hard to believe that, in 2013, many clinicians were still relying on the vague findings of a 200-year-old traditional physical examination and were compromising clinical efficacy when direct information was available from point-of-care echocardiography. History will undoubtedly show that point-of-care echocardiography is the beginning of a 'new glorious age' of the physical examination.

Myocardial function

During the last 2 years, a significant number of articles have been published, which described the normal reference ranges for echocardiographic studies.^{13–17} We might wonder why all these reports are necessary, but the definition of normal ranges differ according to age, gender, body surface area (BSA), and ethnicity.¹⁸ Newer ultrasound techniques also affect our measurements. Large studies on normal ranges in different types of patients are therefore welcome and will be critical to make correct diagnostic conclusions in our patients.

Assessment of myocardial function has always been one of the most important goals of every cardiac imaging study in most patients. Left ventricular ejection fraction (LVEF) has traditionally been the single most important parameter of LV performance, but a lot of newer and important echocardiographic parameters are now into clinical use. Assessment of LV longitudinal function has been demonstrated to give incremental and additional information to LVEF and can, for example, be done by the evaluation mitral annular displacement (MAD). MAD can be calculated from M-mode, colour tissue Doppler imaging (TDI), and two-dimensional (2D) strain echocardiography. The article from de Knecht *et al.*¹⁹ has tested the agreement and reproducibility of MAD assessed by these various echocardiographic modalities. They found that MAD could be assessed by all three methods, but they were not interchangeable. *Figure 1* shows the different echocardiographic methods to assess LV systolic function by MAD.

Questions remain about the variability among different vendors about strain values and tissue velocity measurements. An EACVI driven initiative aims to get the vendors and experts together in order to standardize the way the assessments are done.²⁰ Another interesting study from Dhutia *et al.* presented differences and a simple method for calibrating tissue Doppler velocity measurements to make them more consistent.^{21,22}

Assessment of all chamber function by speckle tracking echocardiography (STE) has been included in many echocardiographic laboratories in the recent years. The 2D technique has been accepted to give additional and superior information to assessment of LVEF alone. A number of reports about 3D strain have also been published the past years, but so far the results are discordant with regard to superiority of the 2D method.²³ A recent report by Altman *et al.*²⁴ concluded that 3D STE allowed accurate and faster

analysis of deformation when compared with 2D STE and might represent a viable alternative in the evaluation of global LV function. They studied 166 patients with different types of pathology and found that area strain and longitudinal strain from the 3D technique were best, but that further improvements were needed to firmly establish this technology as superior to 2D in the assessment of deformation.

A multicentre study from USA and Australia tested the ability of global longitudinal strain (GLS) to identify systolic dysfunction in 159 patients receiving anthracyclines, trastuzumab and or not cardioprotective β -blockers.²⁵ Their results showed that GLS could be used to document impairment of cardiac function in patients treated with anthracyclines, trastuzumab, or both. In addition, this was the first study to evaluate the echocardiographic (strain and LVEF) responses to treatment initiated in response to a reduction in myocardial deformation engendered by chemotherapy-induced cardiotoxicity. Their results suggested that β -blocker therapy might facilitate the recovery of cardiotoxicity.

Studies by STE have revealed LV dysfunction in many groups of patients in whom LVEF remains normal. Roos *et al.*²⁶ studied 112 asymptomatic patients with type 2 diabetes mellitus with an interval of 2 years. They had normal LVEF and were 53 ± 10 years (59% men) at inclusion. The patients remained clinically stable between baseline and follow-up echocardiography. After 2-year follow-up, the authors found a significant increase in the LV mass index and LVEF remained unchanged. In contrast, the article showed a significant impairment in circumferential and longitudinal strains. The authors concluded that also asymptomatic patients with type 2 diabetes mellitus and apparently normal LVEF might show mild progression of subclinical LV function assessed with 2D STE.

One substudy from the Coronary Artery Risk Development in Young Adults (CARDIA) investigated whether the addition of LA size determined by echocardiography improved cardiovascular risk prediction in 4082 young adults over and above the clinically established Framingham 10-year global CV risk score.²⁷ LA size was assessed from M-mode. LA diameter and 2D 4-chamber LA area were then indexed by height or BSA. The authors concluded that LA size measurements independently predicted clinical outcomes. However, it only improved discrimination over clinical parameters modestly without altering risk classification. The CARDIA study used more than 20-year-old echocardiographic studies and the technique has been improved significantly since that. LA size can now be assessed by 3D wall motion tracking, and Perez de Isla *et al.*²⁸ concluded that these measurements compared well with cardiac magnetic resonance (CMR). In addition, they concluded that the method was fast, accurate, and reproducible, and it allowed a better classification of LA enlargement severity compared with 2D echo.

The LA size has also been related to the success of radiofrequency catheter ablation (RFCA) for atrial fibrillation (AF), but potential predictors after a repeated procedure are still unknown. The study from Montserrat *et al.*²⁹ checked if a combination of LA analysis with 3D echo and clinical data predicted elimination of AF after a first ablation procedure for AF, beyond LA size. They showed that although larger LA size was moderately associated with worse success rates of RFCA in patients with AF, the analysis of LA function by 3D echocardiography added an independent predictive value to

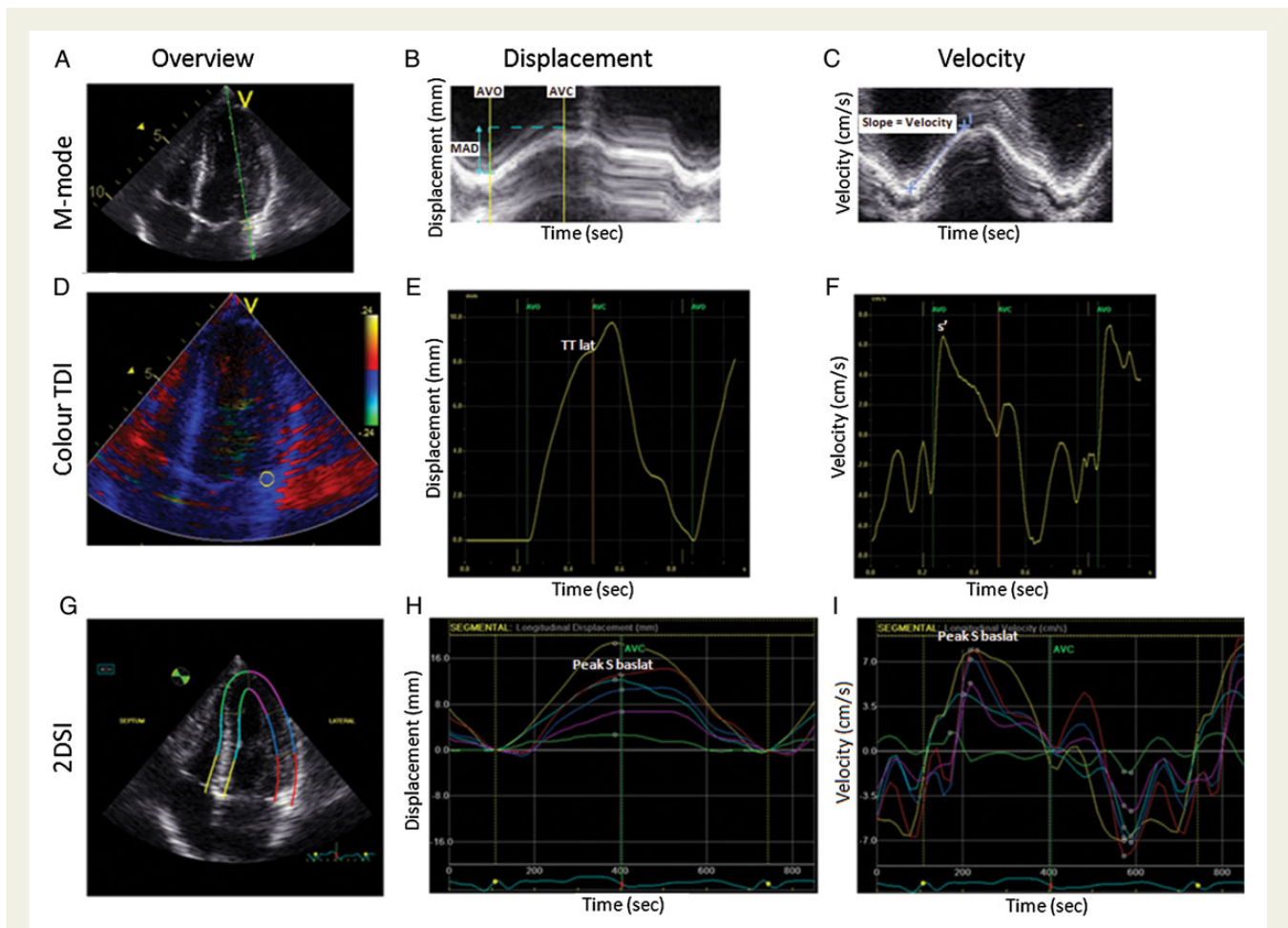


Figure 1 (A) Lateral mitral annulus displacement (MAD) using conventional M-mode measured in the 4-chamber view. (B) By placing the M-mode cursor at the lateral border in the mitral annulus plane, an image of lateral MAD was obtained. The total MAD was measured from the lowest to the highest point of contraction, excluding post-systolic contractions (between AVO and AVC times, respectively). (C) Systolic velocity was determined by measuring the gradient between the highest and lowest points. (D) Sample areas used to determine lateral MAD by colour TDI were placed in the lateral basal segment just proximal to the mitral annulus. (E) Integration of colour TDI velocity curves allowed for the assessment of systolic longitudinal displacement. Post-systolic contraction was not included in total MA displacement measurements. (F) The determination of left ventricular longitudinal velocity (s') in the lateral wall in the apical 4-chamber view. (G) 2DSI in the apical 4-chamber view. (H) By tracking a speckle from frame-to-frame, myocardial motion was assessed and total lateral displacement was determined. (I) Systolic tissue velocity determined by 2DSI. Modified from de Knecht *et al.*¹⁹

identify candidates for successful ablation. LA expansion index, which is a ratio of maximum and minimum volumes, was one of the best parameters to predict successful therapy.

The value of assessing E/e' ratio for estimation of LV filling pressures is debated. The design of a new large EACVI initiated European study that compares invasive pressures to E/e' is described in the last year of the journal.³⁰ The EURO-FILLING study will be performed at leading European centres and is expected to provide important information on non-invasive assessment of LV filling pressure and to contribute to the standardization of this assessment in clinical practice.

Obesity has significant impact on morbidity and mortality. The paper from Kaier *et al.*³¹ reported, for the first time, that bariatric surgery has favourable cardiac effects in these patients. Both LV and right ventricular function 6 months past surgery showed evidence

of improvement by 3D echocardiography. There were no differences with regard to ventricular remodelling when comparing sleeve gastrectomy and gastric bypass.

Myocardial ischaemia

Ischaemic myocardium often stretches, before it contracts, in early systole when the intraventricular pressure rises steeply during the isovolemic contraction phase.³² This stretch can easily be identified by strain through the speckle tracking technique. Zahid *et al.* found that the duration of this early stretch could identify coronary occlusion and even patients with minimal myocardial damage.

The assessment of coronary flow velocity reserve (CFVR) by Doppler is a promising non-invasive method for detecting myocardial ischaemia. However, the relationship to fractional flow reserve

(FFR) was unknown before the study from Wada *et al.*³³ was published. The study showed close relationships between the two methods and thus encouraged the hope for the Doppler method.

The detection of coronary atherosclerosis for the detection of subclinical coronary artery disease (CAD) remains challenging. Coronary lumen integrity is of limited value, and intravascular ultrasound (IVUS) is an invasive method to assess vessel wall remodelling and characterization of plaque composition. Jahnke *et al.*³⁴ tested a comprehensive CMR imaging protocol (3D vessel wall imaging and flow measurement of the proximal right coronary artery, myocardial T2*, and first-pass perfusion imaging) demonstrating a non-invasive approach for direct assessment of coronary vessel wall remodelling.

The non-invasive detection of inducible myocardial ischaemia in patients with angiographic three-vessel disease remains challenging. Motwani *et al.*³⁵ demonstrated that in patients with angiographic three-vessel disease, the ischaemic burden detected by perfusion CMR is greater with high-resolution acquisition (1.6 mm in-plane) compared with standard-resolution (2.5 mm in-plane), due to better detection of subendocardial ischaemia. High-resolution perfusion CMR may therefore be preferred for risk stratification and management of this high-risk patient group.

Recent studies have demonstrated that chronic obstructive pulmonary disease (COPD) is associated with cardiovascular disease. However, the association between COPD and coronary microcirculatory dysfunction is unknown. Nakamori *et al.*³⁶ showed that myocardial perfusion reserve by quantitative myocardial perfusion CMR was impaired in patients with COPD, and independently associated with systemic inflammation and airflow limitation.

Vasodilator stress agents un-selectively bind to adenosine receptors (A₁, A_{2A,2B}, and A₃), which are located in multiple tissue types. Regadenoson is a new stress agent with higher selectivity for the A_{2A} receptors than adenosine, with potentially reduced side effects. In nuclear imaging trials, regadenoson has been shown to be safe, non-inferior to adenosine and with fewer side effects. Nguyen *et al.*³⁷ demonstrated that regadenoson CMR is also well tolerated and can be performed safely with a few adverse events.

Infarct size, traditionally measured by Tc99m-Sestamibi Single-photon emission computed tomography (SPECT), is an important predictor of cardiac risk after acute myocardial infarction (AMI). In patients with AMI, CMR can also assess the presence and extent of infarct size, as well as of microvascular obstruction (MVO). Hadamitzky *et al.*³⁸ demonstrated that the extent of MVO and infarct size by CMR have an excellent prognostic value in predicting cardiac events following AMI and may be used as an alternative to infarct size assessment by Tc99m-Sestamibi-SPECT. They also observed that when analysing the images with 6 SD signal intensity thresholds, infarct size by CMR had a stronger relationship with clinical outcomes compared with infarct size by other CMR methods or SPECT.

Cardiac computed tomography (CT) offers useful information for risk stratification through the detection of obstructive CAD as well as the extent and distribution of non-obstructive atherosclerosis. A study compared the prognostic value of coronary calcium imaging and coronary CTA findings, including stenosis severity, extent, and distribution in 8627 symptomatic patients with suspected CAD who

had both coronary calcium imaging and coronary CTA.³⁹ Coronary CTA findings add incremental discriminatory value over coronary artery calcium imaging for the identification of individuals at high risk of death or MI. The presence of either obstructive or non-obstructive CAD by coronary CTA had independent predictive value for the risk of major adverse cardiac events, including death, MI, and late revascularization in 15 187 individuals without previously known CAD.⁴⁰ The large patient population allowed stratification of risk associated with CTA findings in different age groups. When stratified by age, individuals ≥ 65 years experienced higher event risk for non-obstructive, one- and two-vessel disease than younger individuals. Normal CTA was associated with low risk irrespective of age.

Morphological characteristics, such as positive remodelling, low attenuation, or ring-like sign, have been associated with coronary atherosclerotic plaques that are at high risk of rupture and subsequent acute coronary syndrome (ACS). One study evaluated the prognostic value of these vulnerable plaque features by coronary CTA in 543 cardiac stable patients with normal SPECT perfusion study.⁴¹ Approximately one-third of patients had high-risk plaque features that were a strong predictor (hazard ratio 9.4) of cardiac death, ACS, or late revascularization. Interestingly, another study showed that individuals with non-calcified atherosclerotic plaques corresponding to the low attenuation plaques by CTA had distinct features in their plasma lipid profile by lipidomic analysis.⁴² Patients with recent ACS present a particularly high-risk group as shown in another study demonstrating that almost one quartile of patients with an ACS will have new major cardiovascular event (cardiac death, ACS, or late revascularization) unrelated to the initial culprit plaque during 5-years follow-up.⁴³

CTA is an accurate non-invasive method for the detection of and especially ruling out obstructive CAD in appropriately selected patients. A systematic meta-analysis compared the up-front diagnostic use of coronary CTA vs. exercise ECG or SPECT perfusion imaging-based strategies.⁴⁴ The diagnostic accuracy of CTA-based strategy is higher than that of ECG or SPECT. However, coronary CTA-based strategy results in higher number of downstream test utilization and higher number of revascularizations. Yerramasu *et al.*⁴⁵ prospectively tested the use of coronary artery calcium imaging by unenhanced CT alone as an initial diagnostic test for patients in 300 consecutive patients with stable chest pain syndrome. Notably, none of the 57 patients with both low pre-test probability of CAD and zero calcium score had obstructive CAD or suffered a cardiovascular event during the follow-up of 17 months.

One possible explanation to this is that the anatomical criteria for evaluating haemodynamic significance of intermediate coronary artery stenosis may differ between non-invasive and invasive methods. In a study of 181 intermediate coronary lesions, it was shown that compared with invasive angiography or IVUS, coronary CTA overestimated lesion severity (minimal lumen diameter or minimal lumen area) and hence had lower diagnostic performance in the detection of haemodynamically significant stenosis defined as FFR value ≤ 0.8 .⁴⁰ Layritz *et al.*⁴⁶ studied diagnostic accuracy of very low-dose (on average 0.6 mSv) coronary CTA in patients with suspected CAD. Although iterative reconstruction algorithm reduced image noise, it did not improve diagnostic accuracy over standard filtered back projection algorithm in this study.

Epicardial adipose tissue (EAT) can be measured from cardiac CT scans. Tran *et al.*⁴⁷ showed that a practical EAT measurement in a single axial slice at the level of the left main coronary artery ostium correlated well with the measurement of total EAT from the same non-contrast CT scan and was associated with the presence of obstructive CAD. Mahabadi and coworkers⁴⁸ studied CT scans of 3467 participants of the Neinz Nixdorff Recall study and found that the LA size on CT scans is a strong predictor of incident AF, whereas EAT did not improve prediction of AF over LA size or traditional risk factors.

The current trends in nuclear perfusion imaging include the use of novel rapid SPECT scanners and the growing use of positron emission tomography (PET) and quantitation. Joutsiniemi *et al.*⁴⁹ investigated whether absolute stress flow alone is sufficient in detecting CAD. The authors found that absolute stress perfusion alone was superior to perfusion reserve in the detection of haemodynamically significant CAD. This allows shorter stress-only imaging protocols with smaller radiation dose as it has been suggested for SPECT. In a multicentre registry study of 953 patients with previous CABG, Rb-82 PET perfusion imaging provided independent and incremental prognostic value to clinical variables for both all-cause mortality and cardiac death.⁵⁰

Another trend is to use hybrid imaging. Kim *et al.*⁵¹ found that sequential imaging of SPECT and CTA has incremental prognostic value in patients with suspected CAD. Correspondingly, Schaap *et al.*⁵² showed that hybrid SPECT/CTA imaging has a substantially higher yield than standalone SPECT or CTA in the diagnostic work-up of patients suspected of significant CAD. Furthermore, Danad *et al.*⁵³ found that cardiac hybrid PET/CT imaging had clear impact on downstream referral for invasive coronary angiography and revascularization. Especially with an equivocal CT study myocardial perfusion imaging had clear impact on referral rates for ICA and revascularization.

Molecular imaging

The most common molecular imaging tracer for cardiac diseases is 18F-FDG. Asmar *et al.*⁵⁴ assessed the clinical importance of 18F-FDG PET/CT in the extra-cardiac findings in 72 patients with infective endocarditis. PET/CT detected 114 lesions and 64 were true positive, of which 25 were new findings and detected in 17 patients. In 11 patients, the lesions were considered to have a clinical importance. Thus, 18F-FDG imaging may have impact not only for cardiac diagnosis of endocarditis but also for detecting peripheral infection foci in these patients.

Innervation imaging using myocardial 123I-MIBG scintigraphy has been shown to have prognostic value in patients with chronic heart failure. In a pooled individual patient data meta-analysis of 636 patients, the late heart to mediastinum (H/M) ratios were compared against the incidence of all-cause mortality, cardiac mortality, arrhythmic events, and heart transplantation. In multivariate analysis, late H/M was an independent predictor for all event categories, except for arrhythmias.⁵⁵

99mTc-DPD is better known as bone scintigraphy tracer. Hutt *et al.*⁵⁶ investigated the potential of 99mTc-DPD scintigraphy in 321 patients with suspected cardiac amyloidosis. 99mTc-DPD was very sensitive method for imaging cardiac transthyretin amyloid. The authors found that 99mTc-DPD scintigraphy is a sensitive technique

for imaging cardiac amyloidosis but further studies are warranted to understand better the behaviour of the tracer in different subtypes of amyloidosis.

Emerging techniques in cardiovascular imaging

Myocardial parametric mapping, namely native T1 and extracellular volume fraction (ECV, derived from T1 mapping pre and post contrast), is new cardiac MRI methods that have brought a new dimension to non-invasive myocardial tissue characterization. Although alteration in native T1 may result from processes affecting the myocardium, the interstitium, or both, ECV mapping specifically quantifies expansion of the interstitial space.

H-Ici reviews the role of T1 mapping in both acute and chronic myocardial infarction, an unprecedented opportunity to non-invasively quantify changes in the myocardial structure and interstitial compartment, with the potential to provide incremental information over late gadolinium enhancement imaging for the diagnosis and treatment of patients with ischaemic heart disease.

T2 mapping is also a new parametric imaging technique aiming at improving the detection of myocardial oedema, traditionally performed with the standard T2-weighted imaging. In the context of acute myocardial infarction, the oedematous area corresponds to the area at risk (AAR), which includes the infarcted area (detectable by late gadolinium enhancement imaging) and the salvaged myocardium. The study by Hammer-Hansen *et al.*⁵⁷ uses quantitative T2 maps to characterize and quantify the salvaged and infarcted myocardium within the AAR in a dog model of reperfused acute myocardial infarction. They demonstrated that differences in the T2 of infarcted and salvaged myocardium vs. remote myocardium were apparent after both 4 and 48 h of reperfusion. They also reported that reperfusion time seems to have an impact on the magnitude of the T2 abnormality in the salvaged area, decreasing substantially already in the early phases of healing. Further studies are warranted to determine the optimal timing for AAR imaging and progression of T2 abnormalities.

Oxygenation-sensitive cardiovascular magnetic resonance (OS-CMR) imaging is a potential interesting new technique to explore the impact of the functional severity of coronary artery stenosis on changes in myocardial oxygenation during pharmacological vasodilation. Luu *et al.*⁵⁸ demonstrated that an invasive FFR of 0.80 is associated with a lack of an adenosine-inducible increase in oxygenation of the dependent coronary territory, while a complete lack of such an increase was best predicted by an FFR of 0.54.

Further studies are warranted to identify clinically meaningful cut-off values for FFR measurements and to assess the utility of OS-CMR as an alternative clinical tool for assessing the functional relevance of coronary artery stenosis.

A steadily increasing use of imaging methods in cardiology is produced by invasive methods such as IVUS,^{59,60} optical coherence tomography (OCT), and recently serial optical frequency domain imaging (OFDI).⁶¹ OCT has in a short time become a useful tool for invasive cardiologists.⁶² The visual impression is obvious, but scientific studies will have to show the objective usefulness of this method. Our journal presented last year several studies that confirmed the exciting opportunities by OCT.^{63–66}

Dauwe *et al.*⁶⁷ studied a new software capable of fusing pre-procedural multimodal imaging of the heart with peri-procedural 3D rotational angiography during catheter intervention. In an experimental study in pigs, it was shown that the new software could help to guide endomyocardial injections into the infarct border zone area that is the target. This technology may have important implications for gene therapy trials.

In two studies, the new cadmium–zinc–telluride SPECT camera was tested. In a study by Gimelli *et al.*,⁶⁸ the relationships among regional adrenergic innervation heterogeneity, myocardial perfusion, and contractile function obtained by means of a low-dose imaging protocol with this novel camera were investigated in 28 patients. In another study by the same team, left ventricular diastolic function was measured and found that LV filling dynamics correlated well with echocardiographic parameters of diastolic function.⁶⁹ Chowdhury *et al.*⁷⁰ found reliable prognostic and diagnostic information with this new type of camera. These studies indicate that the novel SPECT scanner technology will further improve the versatility of SPECT, while significantly reducing image acquisition time and/or radiation dose for the patients.

Conflict of interest: none declared.

References

- Edvardsen T, Plein S, Saraste A, Pierard LA, Knuuti J, Maurer G *et al.* The year 2013 in the *European Heart Journal – Cardiovascular Imaging*. Part I. *Eur Heart J Cardiovasc Imaging* 2014;**15**:730–5.
- Plein S, Edvardsen T, Pierard LA, Saraste A, Knuuti J, Maurer G *et al.* The year 2013 in the *European Heart Journal – Cardiovascular Imaging*. Part II. *Eur Heart J Cardiovasc Imaging* 2014;**15**:837–41.
- Lancellotti P, Magne J, Cosyns B, Donal E, Kitsiou A, Miller O *et al.* EuroEcho-Imaging 2013: highlights. *Eur Heart J Cardiovasc Imaging* 2014;**15**:483–8.
- Garbi M, Habib G, Plein S, Neglia D, Kitsiou A, Donal E *et al.* Appropriateness criteria for cardiovascular imaging use in clinical practice: a position statement of the ESC/EACVI taskforce. *Eur Heart J Cardiovasc Imaging* 2014;**15**:477–82.
- Cosyns B, Plein S, Nihoyanopoulos P, Smiseth O, Achenbach S, Andrade MJ *et al.* On behalf of the European Association of Cardiovascular Imaging (EACVI) and European Society of Cardiology Working Group (ESC WG) on Myocardial and Pericardial diseases. European Association of Cardiovascular Imaging (EACVI) position paper: multimodality imaging in pericardial disease. *Eur Heart J Cardiovasc Imaging* 2015;**16**:12–31.
- Plana JC, Galderisi M, Barac A, Ewer MS, Ky B, Scherrer-Crosbie M *et al.* Expert consensus for multimodality imaging evaluation of adult patients during and after cancer therapy: a report from the American Society of Echocardiography and the European Association of Cardiovascular Imaging. *Eur Heart J Cardiovasc Imaging* 2014;**15**:1063–93.
- Gurzun M-M, Ionescu A. Appropriateness of use criteria for transthoracic echocardiography: are they relevant outside the USA? *Eur Heart J Cardiovasc Imaging* 2014;**15**:450–5.
- Flachskampf FA, Wouters PF, Edvardsen T, Evangelista A, Habib G, Hoffman P *et al.* European Association of Cardiovascular Imaging Document reviewers: Erwan Donal and Fausto Rigo. Recommendations for transoesophageal echocardiography: EACVI update 2014. *Eur Heart J Cardiovasc Imaging* 2014;**15**:353–65.
- Neskovic AN, Edvardsen T, Galderisi M, Garbi M, Gullace G, Jucut R *et al.* Focus cardiac ultrasound: the European Association of Cardiovascular Imaging viewpoint. *Eur Heart J Cardiovasc Imaging* 2014;**15**:956–60.
- Popescu BA, Stefanidis AG, Nihoyannopoulos P, Fox KF, Ray S, Cardim N *et al.* Updated standards and processes for accreditation of echocardiographic laboratories from The European Association of Cardiovascular Imaging. *Eur Heart J Cardiovasc Imaging* 2014;**15**:717–27.
- Petersen SE, Almeida AG, Alpendurada F, Boubertakh R, Bucciarelli-Ducci C, Cosyns B *et al.* Education Committee of European Association of Cardiovascular Imaging Association (EACVI). Update of the European Association of Cardiovascular Imaging (EACVI) Core Syllabus for the European Cardiovascular Magnetic Resonance Certification Exam. *Eur Heart J Cardiovasc Imaging* 2014;**15**:728–9.
- Roelandt JRTC. The decline of our physical examination skills: is echocardiography to blame? *Eur Heart J Cardiovasc Imaging* 2014;**15**:249–52.
- Peluso D, Badano LP, Muraru D, Dal Bianco L, Cucchini U, Kocabay G *et al.* Right atrial size and function assessed with three-dimensional and speckle-tracking echocardiography in 200 healthy volunteers. *Eur Heart J Cardiovasc Imaging* 2013;**14**:1106–14.
- Muraru D, Maffessanti F, Kocabay G, Peluso D, Dal Bianco L, Piasentini E *et al.* Ascending aorta diameters measured by echocardiography using both leading edge-to-leading edge and inner edge-to-inner edge conventions in healthy volunteers. *Eur Heart J Cardiovasc Imaging* 2014;**15**:415–22.
- Poppe KK, Doughty RN, Whalley GA. Redefining normal reference ranges for echocardiography: a major new individual person data meta-analysis. *Eur Heart J Cardiovasc Imaging* 2013;**14**:347–8.
- Lancellotti P, Badano LP, Lang RM, Akhmaladze N, Athanassopoulos GD, Barone D *et al.* Normal Reference Ranges for Echocardiography: rationale, study design, and methodology (NORRE Study). *Eur Heart J Cardiovasc Imaging* 2013;**14**:303–8.
- Kou S, Caballero L, Dulgheru R, Voilliot D, De Sousa C, Kacharava G *et al.* Echocardiographic reference ranges for normal cardiac chamber size: results from the NORRE study. *Eur Heart J Cardiovasc Imaging* 2014;**15**:680–90.
- Echocardiographic Normal Ranges Meta-Analysis of the Left heart (EchoNoRMAL) Collaboration. A meta-analysis of echocardiographic measurements of the left heart for the development of normative reference ranges in a large international cohort: the EchoNoRMAL study. *Eur Heart J Cardiovasc Imaging* 2014;**15**:341–8.
- de Kneegt MC, Biering-Sorensen T, Sogaard P, Sivertsen J, Jensen JS, Mogelvang R. Concordance and reproducibility between M-mode, tissue Doppler imaging, and two-dimensional strain imaging in the assessment of mitral annular displacement and velocity in patients with various heart conditions. *Eur Heart J Cardiovasc Imaging* 2014;**15**:62–9.
- Voigt JU, Pedrizzetti G, Lysyansky P, Marwick TH, Houle H, Baumann R *et al.* Definitions for a common standard for 2D speckle tracking echocardiography: consensus document of the EACVI/ASE/Industry Task Force to standardize deformation imaging. *Eur Heart J Cardiovasc Imaging* 2015;**16**:1–11.
- Dhulia NM, Zolgharni M, Willson K, Cole G, Nowbar AN, Dawson D *et al.* Guidance for accurate and consistent tissue Doppler velocity measurement: comparison of echocardiographic methods using a simple vendor-independent method for local validation. *Eur Heart J Cardiovasc Imaging* 2014;**15**:817–27.
- Flachskampf FA, Mårtensson M. How should tissue Doppler tracings be measured? *Eur Heart J Cardiovasc Imaging* 2014;**15**:828–9.
- Badano LP, Cucchini U, Muraru D, Al Nono O, Sarais C, Iliceto S. Use of three-dimensional speckle tracking to assess left ventricular myocardial mechanics: inter-vendor consistency and reproducibility of strain measurements. *Eur Heart J Cardiovasc Imaging* 2013;**14**:285–93.
- Altman M, Bergerot C, Aussoleil A, Davidsen ES, Sibellas F, Ovize M *et al.* Assessment of left ventricular systolic function by deformation imaging derived from speckle tracking: a comparison between 2D and 3D echo modalities. *Eur Heart J Cardiovasc Imaging* 2014;**15**:316–23.
- Negishi K, Negishi T, Haluska BA, Hare JL, Plana JC, Marwick TH. Use of speckle strain to assess left ventricular responses to cardiotoxic chemotherapy and cardioprotection. *Eur Heart J Cardiovasc Imaging* 2014;**15**:324–31.
- Roos CJ, Scholte AJ, Kharagitsingh AV, Bax JJ, Delgado V. Changes in multidirectional LV strain in asymptomatic patients with type 2 diabetes mellitus: a 2-year follow-up study. *Eur Heart J Cardiovasc Imaging* 2014;**15**:41–7.
- Armstrong AC, Liu K, Lewis CE, Sidney S, Colangelo LA, Kishi S *et al.* Left atrial dimension and traditional cardiovascular risk factors predict 20-year clinical cardiovascular events in young healthy adults: the CARDIA study. *Eur Heart J Cardiovasc Imaging* 2014;**15**:893–9.
- Perez de Isla L, Feltes G, Moreno J, Martinez W, Saltijeral A, de Agustin JA *et al.* Quantification of left atrial volumes using three-dimensional wall motion tracking echocardiographic technology: comparison with cardiac magnetic resonance. *Eur Heart J Cardiovasc Imaging* 2014;**15**:793–9.
- Montserrat S, Gabrielli L, Borrás R, Poyatos S, Berruzo A, Bijnsen B *et al.* Left atrial size and function by three-dimensional echocardiography to predict arrhythmia recurrence after first and repeated ablation of atrial fibrillation. *Eur Heart J Cardiovasc Imaging* 2014;**15**:515–22.
- Galderisi M, Lancellotti P, Donal E, Cardim N, Edvardsen T, Habib G *et al.* European multicentre validation study of the accuracy of E/e' ratio in estimating invasive left ventricular filling pressure: EURO-FILLING study. *Eur Heart J Cardiovasc Imaging* 2014;**15**:810–6.
- Kaier TE, Morgan D, Grapsa J, Demir OM, Paschou SA, Sundar S *et al.* Ventricular remodelling post-bariatric surgery: is the type of surgery relevant? A prospective study with 3D speckle tracking. *Eur Heart J Cardiovasc Imaging* 2014;**15**:1256–62.
- Zahid W, Eek CH, Remme EW, Skulstad H, Fosse E, Edvardsen T. Early systolic lengthening may identify minimal myocardial damage in patients with non-ST-elevation acute coronary syndrome. *Eur Heart J Cardiovasc Imaging* 2014;**15**:1152–60.
- Wada T, Hirata K, Shiono Y, Orii M, Shimamura K, Ishibashi K *et al.* Coronary flow velocity reserve in three major coronary arteries by transthoracic

- echocardiography for the functional assessment of coronary artery disease: a comparison with fractional flow reserve. *Eur Heart J Cardiovasc Imaging* 2014;**15**:399–408.
34. Jahnke C, Manka R, Kozerke S, Schnackenburg B, Gebker R, Marx N et al. Cardiovascular magnetic resonance profiling of coronary atherosclerosis: vessel wall remodelling and related myocardial blood flow alterations. *Eur Heart J Cardiovasc Imaging* 2014;**15**:1400–10.
 35. Motwani M, Maredia N, Fairbairn TA, Kozerke S, Greenwood JP, Plein S. Assessment of ischaemic burden in angiographic three-vessel coronary artery disease with high-resolution myocardial perfusion cardiovascular magnetic resonance imaging. *Eur Heart J Cardiovasc Imaging* 2014;**15**:701–8.
 36. Nakamori S, Onishi K, Ishida M, Nakajima H, Yamada T, Nagata M et al. Myocardial perfusion reserve is impaired in patients with chronic obstructive pulmonary disease: a comparison to current smokers. *Eur Heart J Cardiovasc Imaging* 2014;**15**:180–8.
 37. Nguyen KL, Bandettini WP, Shanbhag S, Leung SW, Wilson JR, Arai AE. Safety and tolerability of regadenoson CMR. *Eur Heart J Cardiovasc Imaging* 2014;**15**:753–60.
 38. Hadamitzky M, Langhans B, Hausleiter J, Sonne C, Byrne RA, Mehilil J et al. Prognostic value of late gadolinium enhancement in cardiovascular magnetic resonance imaging after acute ST-elevation myocardial infarction in comparison with single-photon emission tomography using Tc99m-Sestamibi. *Eur Heart J Cardiovasc Imaging* 2014;**15**:216–25.
 39. Al-Mallah MH, Qureshi W, Lin FY, Achenbach S, Berman DS, Budoff MJ et al. Does coronary CT angiography improve risk stratification over coronary calcium scoring in symptomatic patients with suspected coronary artery disease? Results from the prospective multicenter international CONFIRM registry. *Eur Heart J Cardiovasc Imaging* 2014;**15**:267–74.
 40. Doh JH, Koo BK, Nam CW, Kim JH, Min JK, Nakazato R et al. Diagnostic value of coronary CT angiography in comparison with invasive coronary angiography and intravascular ultrasound in patients with intermediate coronary artery stenosis: results from the prospective multicenter FIGURE-OUT (Functional Imaging criteria for GUIDing REview of invasive coronary angiOgraphy, intravascular Ultrasound, and coronary computed Tomographic angiography) study. *Eur Heart J Cardiovasc Imaging* 2014;**15**:870–7.
 41. Otsuka K, Fukuda S, Tanaka A, Nakanishi K, Taguchi H, Yoshiyama M et al. Prognosis of vulnerable plaque on computed tomographic coronary angiography with normal myocardial perfusion image. *Eur Heart J Cardiovasc Imaging* 2014;**15**:332–40.
 42. Ellims AH, Wong G, Weir JM, Lew P, Meikle PJ, Taylor AJ. Plasma lipidomic analysis predicts non-calcified coronary artery plaque in asymptomatic patients at intermediate risk of coronary artery disease. *Eur Heart J Cardiovasc Imaging* 2014;**15**:908–16.
 43. Dedic A, Kurata A, Lubbers M, Meijboom WB, van Dalen B, Snelder S et al. Prognostic implications of non-culprit plaques in acute coronary syndrome: non-invasive assessment with coronary CT angiography. *Eur Heart J Cardiovasc Imaging* 2014;**15**:1231–7.
 44. Nielsen LH, Ortnor N, Nørgaard BL, Achenbach S, Leipsic J, Abdulla J. The diagnostic accuracy and outcomes after coronary computed tomography angiography vs. conventional functional testing in patients with stable angina pectoris: a systematic review and meta-analysis. *Eur Heart J Cardiovasc Imaging* 2014;**15**:961–71.
 45. Yerramasu A, Lahiri A, Venuraju S, Dumo A, Lipkin D, Underwood SR et al. Diagnostic role of coronary calcium scoring in the rapid access chest pain clinic: prospective evaluation of NICE guidance. *Eur Heart J Cardiovasc Imaging* 2014;**15**:886–92.
 46. Layritz C, Schmid J, Achenbach S, Ulzheimer S, Wuest W, May M et al. Accuracy of prospectively ECG-triggered very low-dose coronary dual-source CT angiography using iterative reconstruction for the detection of coronary artery stenosis: comparison with invasive catheterization. *Eur Heart J Cardiovasc Imaging* 2014;**15**:1238–45.
 47. Tran T, Small G, Cocker M, Yam Y, Chow BJW. A single slice measure of epicardial adipose tissue can serve as an indirect measure of total epicardial adipose tissue burden and is associated with obstructive coronary artery disease. *Eur Heart J Cardiovasc Imaging* 2014;**15**:423–30.
 48. Hermann DM, Lehmann N, Gronewold J, Bauer M, Mahabadi AA, Weimar C et al., on behalf of the Heinz Nixdorf Recall Study Investigative Group. Thoracic aortic calcification is associated with incident stroke in the general population in addition to established risk factors. *Eur Heart J Cardiovasc Imaging* 2015;**16**:684–90.
 49. Joutsiniemi E, Saraste A, Pietilä M, Mäki M, Kajander S, Ukkonen H et al. Absolute flow or myocardial flow reserve for the detection of significant coronary artery disease? *Eur Heart J Cardiovasc Imaging* 2014;**15**:659–65.
 50. Pen A, Yam Y, Chen L, Dorbala S, Di Carli MF, Merhige ME et al. Prognostic value of Rb-82 positron emission tomography myocardial perfusion imaging in coronary artery bypass patients. *Eur Heart J Cardiovasc Imaging* 2014;**15**:787–92.
 51. Kim HL, Kim YJ, Lee SP, Park EA, Paeng JC, Kim HK et al. Incremental prognostic value of sequential imaging of single-photon emission computed tomography and coronary computed tomography angiography in patients with suspected coronary artery disease. *Eur Heart J Cardiovasc Imaging* 2014;**15**:878–85.
 52. Schaap J, de Groot JAH, Nieman K, Meijboom WB, Boekholdt SM, Kauling RM et al. Added value of hybrid myocardial perfusion SPECT and CT coronary angiography in the diagnosis of coronary artery disease. *Eur Heart J Cardiovasc Imaging* 2014;**15**:1281–8.
 53. Danad I, Rajmakers PG, Harms HJ, van Kuijk C, van Royen N, Diamant M et al. Effect of cardiac hybrid ¹⁵O-water PET/CT imaging on downstream referral for invasive coronary angiography and revascularization rate. *Eur Heart J Cardiovasc Imaging* 2014;**15**:170–9.
 54. Asmar A, Ozcan C, Diederichsen ACP, Thomassen A, Gill S. Clinical impact of 18F-FDG-PET/CT in the extra cardiac work-up of patients with infective endocarditis. *Eur Heart J Cardiovasc Imaging* 2014;**15**:1013–9.
 55. Verschure DO, Veltman CE, Manrique A, Somsen GA, Koutelou M, Katsikis A et al. For what endpoint does myocardial 123I-MIBG scintigraphy have the greatest prognostic value in patients with chronic heart failure? Results of a pooled individual patient data meta-analysis. *Eur Heart J Cardiovasc Imaging* 2014;**15**:996–1003.
 56. Hutt DF, Quigley A-M, Page J, Hall ML, Burniston M, Gopaul D et al. Utility and limitations of 3,3-diphosphono-1,2-propanodicarboxylic acid scintigraphy in systemic amyloidosis. *Eur Heart J Cardiovasc Imaging* 2014;**15**:1289–98.
 57. Hammer-Hansen S, Ugander M, Hsu LY, Taylor J, Thune JJ, Køber L et al. Distinction of salvaged and infarcted myocardium within the ischaemic area-at-risk with T2 mapping. *Eur Heart J Cardiovasc Imaging* 2014;**15**:1048–53.
 58. Luu JM, Friedrich MG, Harker J, Dwyer N, Guensch D, Mikami Y et al. Relationship of vasodilator-induced changes in myocardial oxygenation with the severity of coronary artery stenosis: a study using oxygenation-sensitive cardiovascular magnetic resonance. *Eur Heart J Cardiovasc Imaging* 2014;**15**:1358–67.
 59. Puri R, Libby P, Nissen SE, Wolksi K, Ballantyne CM, Barter PJ et al. Long-term effects of maximally intensive statin therapy on changes in coronary atheroma composition: insights from SATURN. *Eur Heart J Cardiovasc Imaging* 2014;**15**:380–8.
 60. Dangas GD, Maehara A, Evrard SM, Sartori S, Li JR, Chirumamilla AP et al. Coronary artery calcification is inversely related to body morphology in patients with significant coronary artery disease: a three-dimensional intravascular ultrasound study. *Eur Heart J Cardiovasc Imaging* 2014;**15**:201–9.
 61. García-García HM, Muramatsu T, Nakatani S, Lee IS, Holm NR, Thuesen L et al. Serial optical frequency domain imaging in STEMI patients: the follow-up report of TROFI study. *Eur Heart J Cardiovasc Imaging* 2014;**15**:987–95.
 62. Mintz GS. Beyond greyscale IVUS assessment of progression/regression: it should be simple, but it's not. *Eur Heart J Cardiovasc Imaging* 2014;**15**:378–9.
 63. De Cock D, Bennett J, Ughi GJ, Dubois C, Sinnaeve P, Dhooze J et al. Healing course of acute vessel wall injury after drug-eluting stent implantation assessed by optical coherence tomography. *Eur Heart J Cardiovasc Imaging* 2014;**15**:800–9.
 64. Tada T, Kadota K, Hosogi S, Miyake K, Amano H, Nakamura M et al. Association between tissue characteristics evaluated with optical coherence tomography and mid-term results after paclitaxel-coated balloon dilatation for in-stent restenosis lesions: a comparison with plain old balloon angioplasty. *Eur Heart J Cardiovasc Imaging* 2014;**15**:307–15.
 65. Iguchi T, Hasegawa T, Otsuka K, Matsumoto K, Yamazaki T, Nishimura S et al. Insulin resistance is associated with coronary plaque vulnerability: insight from optical coherence tomography analysis. *Eur Heart J Cardiovasc Imaging* 2014;**15**:284–91.
 66. Niccoli G, Dato I, Imavea AE, Antonazzo Panico R, Roberto M, Burzotta F et al. Association between inflammatory biomarkers and in-stent restenosis tissue features: an Optical Coherence Tomography Study. *Eur Heart J Cardiovasc Imaging* 2014;**15**:917–25.
 67. Dauwe DF, Nuyens D, De Buck S, Claus P, Gheysens O, Koole M et al. Three-dimensional rotational angiography fused with multimodal imaging modalities for targeted endomyocardial injections in the ischaemic heart. *Eur Heart J Cardiovasc Imaging* 2014;**15**:900–7.
 68. Gimelli A, Liga R, Pasanisi EM, Giorgetti A, Marras G, Favilli B et al. Evaluation of left ventricular diastolic function with a dedicated cadmium-zinc-telluride cardiac camera: comparison with Doppler echocardiography. *Eur Heart J Cardiovasc Imaging* 2014;**15**:972–9.
 69. Gimelli A, Liga R, Giorgetti A, Genovesi D, Marzullo P. Assessment of myocardial adrenergic innervation with a solid-state dedicated cardiac cadmium-zinc-telluride camera: first clinical experience. *Eur Heart J Cardiovasc Imaging* 2014;**15**:575–85.
 70. Chowdhury FU, Vaidyanathan S, Bould M, Marsh J, Trickett C, Dodds K et al. Rapid-acquisition myocardial perfusion scintigraphy (MPS) on a novel gamma camera using multipinhole collimation and miniaturized cadmium-zinc-telluride (CZT) detectors: prognostic value and diagnostic accuracy in a 'real-world' nuclear cardiology service. *Eur Heart J Cardiovasc Imaging* 2014;**15**:275–83.