

CASE REPORT

# Acute effects of Parlodel-LAR<sup>®</sup> and response to long-term treatment with bromocriptine in a patient with a follicle stimulating hormone-secreting pituitary adenoma

R. Abs\*, P.M. Parizel\*\*, and A. Beckers\*\*\*

Departments of \*Endocrinology and \*\*Radiology, University of Antwerp (UIA), Antwerpen and \*\*\*Department of Endocrinology, University of Liège, Liège, Belgium.

**ABSTRACT.** A 68-year-old male patient presented with visual impairment due to a large pituitary tumor. After transsphenoidal adenomectomy the elevated serum FSH levels were lowered but not normalized. Deterioration of the vision was detected five years later and tumor regrowth was evidenced. The patient was treated with the long-acting and repeatable form of bromocriptine (Parlodel-LAR<sup>®</sup>). Three days after the first intramuscular injection it already resulted in an important improvement of the visual field defects. Serum FSH concentration was suppressed during a prolonged period, but no

change in the size of the pituitary adenoma was recorded on CT scan. Long-term oral treatment with bromocriptine resulted in a sustained suppression of the serum FSH levels, without further visual improvement, but with a significant reduction of the volume of the adenoma. The rapid and prolonged effect of Parlodel-LAR<sup>®</sup> upon the FSH secretion, with a possible correction of the visual field defects and a reduction of the tumor mass, could make this medication appropriate as adjunctive treatment in some gonadotroph cell adenomas.

## INTRODUCTION

The existence of follicle-stimulating hormone (FSH)-secreting pituitary adenomas is now well accepted (1). The incidence remains uncertain, but they represent a substantial part of macroadenomas in men (2). They are characterized by their large size resulting in visual impairment which is the most commonly presenting symptom. Although transsphenoidal surgery is the treatment of choice, it is rarely curative (3). Regrowth of the adenoma can again cause optic nerve compression, necessitating the availability of an effective adjunctive medical therapy. A few reports mentioned the suppressive effects of octreotide upon LH and alpha-subunit secretion in glycoprotein hormone-secreting adenomas (4, 5). Bromocriptine was reported to decrease FSH secretion in three FSH-secreting adenomas (6-8). We report the hormonal, visual and radiological changes obtained in a patient with a FSH-secreting pituitary

adenoma, who has been treated with the long-acting and repeatable form of bromocriptine (Parlodel-LAR<sup>®</sup>, Sandoz Ltd, Basle, Switzerland) for 3 months and afterwards with the oral form of bromocriptine for 18 months.

## CASE REPORT

A male patient born in 1915 presented with bitemporal hemianopsia in 1983. He also complained of impotence since a few years. He was the father of three children. Basal serum testosterone, thyroid hormones, TSH and PRL concentrations were normal. Stimulation with TRH provoked a prolonged TSH secretion and a minimal PRL response. Plasma ACTH, serum cortisol and GH levels were hardly stimulated during insulin-induced hypoglycemia. Serum LH level was 9.6 IU/l, and FSH level was 42 IU/l. CT scanning revealed a large pituitary mass extending into the suprasellar region. The patient underwent a transsphenoidal adenomectomy. Postoperatively he developed panhypopituitarism and needed therapy with hydrocortison, thyroid hormones and androgen supplements. In 1988 the patient noticed a further visual impairment. After performing pituitary evaluation, treatment with bromocriptine was started.

*Key-words:* Pituitary neoplasms, FSH, bromocriptine, Parlodel-LAR.

*Correspondence:* Dr. Roger Abs, Department of Endocrinology, University of Antwerp, Universiteitsplein 1, B-2610 Wilrijk, Belgium.

Received July 2, 1990; accepted November 30, 1990.

## METHODS

All pituitary hormones were determined using commercial kits. Normal basal serum values were 2-10 IU/l for LH, 2-7 IU/l for FSH and 0-1.3 µg/l for alpha-subunit. Pituitary reserve of TSH and PRL and paradoxical release of LH, FSH, and alpha-subunit were assessed by a 200 µg TRH iv test. Serum FSH levels were followed hourly during 10 h after the administration of a 5 mg oral dose of bromocriptine and after a 50 mg im dose of long-acting and repeatable bromocriptine. Parlodel-LAR<sup>®</sup> was administered every four weeks for a total of three injections. Hormonal effect was evaluated by measuring weekly the serum FSH level as an average of four determinations. Effect upon the tumor volume was checked by performing a CT scan (General Electric, GE 9800) before and after one and three months of treatment. Visual fields were assessed with computerized perimetry before each injection and one, three and twenty-eight days after each injection. After three months the intramuscular administration of Parlodel-LAR<sup>®</sup> was replaced by an oral treatment consisting of 10 mg bromocriptine for a period of 18 months. Serum FSH determination, visual perimetry and CT scanning were performed every six months.

## RESULTS

The administration of TRH did not stimulate TSH and PRL secretion. Serum LH levels increased from 0.7 to 2.0 IU/l and serum FSH levels from 9.1 to 16.0 IU/l. Serum alpha-subunit levels rose from 0.9 to

2.3 µg/l. Oral bromocriptine suppressed serum FSH levels from 9.5 to maximally 7.8 IU/l after six hours. Parlodel-LAR<sup>®</sup> suppressed serum FSH levels from 8.5 to 5.5 IU/l after six hours. The inhibitory effect of Parlodel LAR<sup>®</sup> was maximal after two weeks, resulting in serum FSH levels less than 1.5 IU/l, and was still pronounced after four weeks (Fig. 1). Subsequent administration of Parlodel-LAR<sup>®</sup> resulted in further suppression of the FSH secretion. Long-term oral treatment with 10 mg bromocriptine daily during 18 months maintained the serum FSH concentration under 1.5 IU/l. Serum alpha-subunit levels were always suppressed whatever the treatment.

The patient showed a complete bitemporal hemianopsia before initiating the treatment with Parlodel-LAR<sup>®</sup>. Three days after the first administration of Parlodel-LAR<sup>®</sup> an important improvement of the visual field defects was recorded, which was even more pronounced after one month (Fig. 2). Correction of the central visual acuity was also detected after the second injection of Parlodel-LAR<sup>®</sup>. The right side improved from 10/10 to 20/10 and the left side from 4/10 to 12/10. No further changes were noticed afterwards.

CT scanning showed a pituitary adenoma with a maximal height of 27 mm expanding in the suprasellar cisterna and both sinus cavernosus. The chiasma opticum was shifted forward. No reduction in tumor volume was demonstrated during the administration of Parlodel-LAR<sup>®</sup>. However, 18 months after initiating the oral treatment with bromocriptine, the height of the adenoma was decreased to 23 mm.

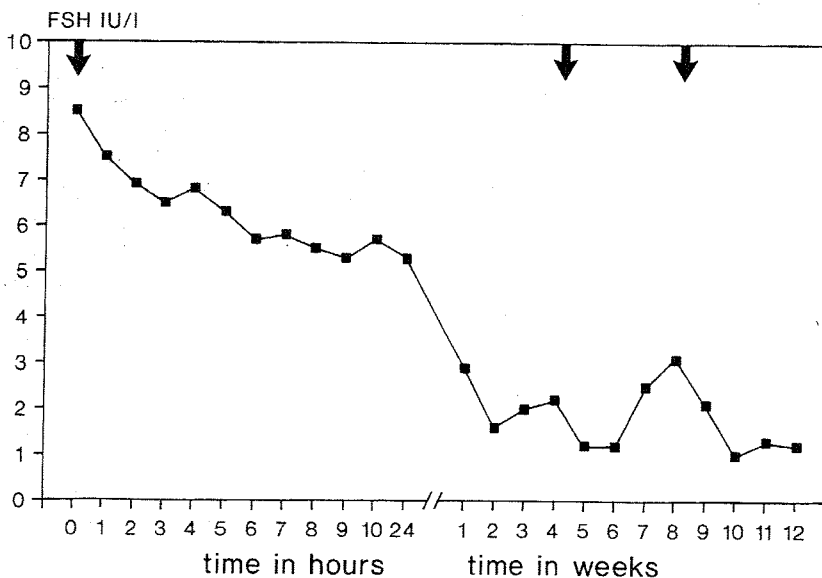


Fig 1 - Serum FSH levels during treatment with Parlodel-LAR<sup>®</sup>. Each intramuscular administration is indicated by an arrow.

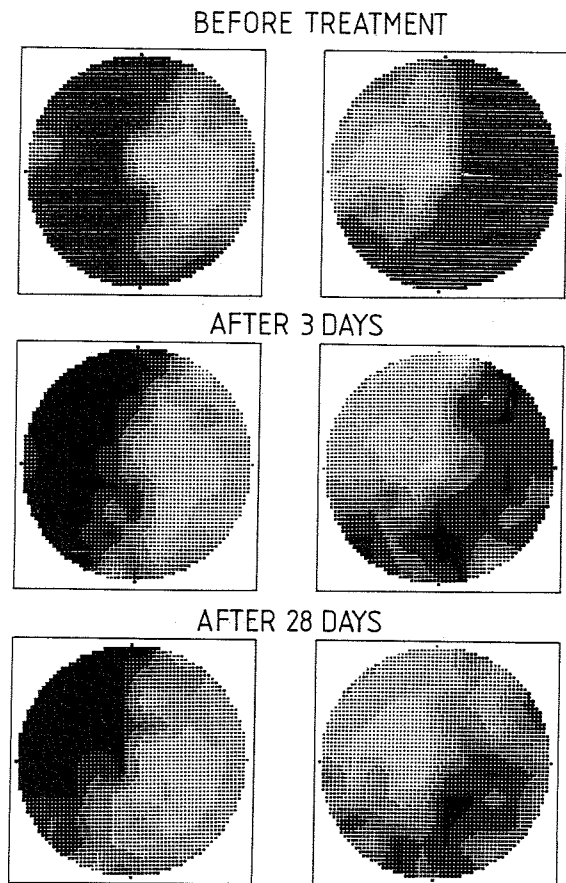


Fig 2 - Visual fields perimetry before and three and twenty-eight days after the first administration of Parlodel-LAR®.

## DISCUSSION

Due to the fact that FSH-secreting pituitary adenomas do not produce a clinical syndrome, diagnosis is frequently delayed, resulting in large tumors. Since neurosurgery is often not curative, medical therapy has to be considered to obtain a further shrinkage of the tumor. However, no systematic study that correlates the efficacy of such treatment with the hormonal status and the immunocytochemical characteristics of the adenoma is available. A review about the treatment of clinically non-functioning pituitary adenomas with bromocriptine concluded that no definitive therapeutic consequences can be drawn since the tumors were unselected and because of unavailable gonadotropin data (9). Only three reports mention the treatment of FSH-secreting adenomas with bromocriptine (6-8). It always resulted in an important suppression of the FSH secretion, but no reduction in the size of

the adenoma was seen on CT scan, even after 30 months of treatment (6). In one case an improvement of the visual field defects was demonstrated after a treatment with 7.5 mg bromocriptine for two weeks (8).

In our patient an extremely rapid amelioration of the visual field defects was recorded after administration of Parlodel-LAR®, paralleling the decrease in FSH secretion. It can only be explained by involution of the adenoma, although this could not be objectivated by CT scanning. This rapid effect is probably achieved by the high circulating serum level of bromocriptine obtained by intramuscular administration (10). In contrast to the other case reports (6-8), long-term treatment with oral bromocriptine finally resulted in a volume regression of the adenoma.

Although there is no actual evidence that Parlodel-LAR® gives better overall results than oral bromocriptine in the treatment of FSH-secreting adenomas, it offers an easy therapeutic scheme and is furthermore well-tolerated. Another possible advantage of Parlodel-LAR® lies in its fast and profound action, making it particularly interesting as a therapeutic tool when vision is impaired or when surgery is contraindicated. Serum FSH concentration obtained two weeks after the first injection could be the hormonal parameter of efficacy of treatment and visual improvement should be expected by that time. Whether a long-term treatment with Parlodel-LAR® is effective in producing the same response in most FSH-secreting adenomas remains to be established in larger series.

## ACKNOWLEDGMENTS

We thank Dr. I. Lancranjan and Dr. M. de Longueville, Sandoz Ltd., for the generous provision of Parlodel-LAR®.

## REFERENCES

1. Beckers A., Stevenaert A., Mashiter K., Hennen G. Follicle-stimulating hormone-secreting pituitary adenomas. *J. Clin. Endocrinol. Metab.* 61: 525, 1985.
2. Snyder P.J. Gonadotroph cell adenomas of the pituitary. *Endocr. Rev.* 6: 552, 1985.
3. Harris R.I., Schatz N.J., Gennarelli T., Savino P.J., Cobbs W.H., Snyder P.J. FSH-secreting pituitary adenomas: correlation of reduction of adenoma size with reduction of hormonal hypersecretion after transsphenoidal surgery. *J. Clin. Endocrinol. Metab.* 56: 1288, 1983.

R. Abs, P.M. Parizel, and A. Beckers

4. Vos P., Croughs R.J.M., Thijssen J.H.H., van't Verlaat J.W., van Ginkel L.A.  
Response of luteinizing hormone secreting pituitary adenoma to a long-acting somatostatin analogue.  
*Acta Endocrinol. (Copenh.)* 118: 587, 1988.
5. Sassolas G., Serusclat P., Claustrat B., Trouillas J., Merabet S., Cohen R., Souquet J.C.  
Plasma alpha-subunit levels during the treatment of pituitary adenomas with the somatostatin analogue SMS 201-995.  
*Horm. Res.* 29: 124, 1988.
6. Berezin M., Olchovsky D., Pines A., Tadmor R., Lunenfeld B.  
Reduction of follicle-stimulating hormone secretion in FSH-producing pituitary adenoma by bromocriptine.  
*J. Clin. Endocrinol. Metab.* 59: 1220, 1984.
7. Chapman A.J., MacFarlane I.A., Shalet S.M., Beardwell C.G., Dutton J. Sutton M.L.  
Discordant serum alpha-subunit and FSH concentrations in a woman with a pituitary tumour.  
*Clin. Endocrinol. (Oxf.)* 21: 123, 1984.
8. Vance M.L., Ridgway E.C., Thorer M.O.  
Follicle-stimulating hormone- and alpha-subunit-secreting pituitary tumor treated with bromocriptine.  
*J. Clin. Endocrinol. Metab.* 61: 580, 1985.
9. Oppenheim D.S., Klibanski A.  
Medical therapy of glycoprotein hormone-secreting pituitary tumors.  
*Endocrinol. Metab. Clin. North. Am.* 18: 339, 1989.
10. Del Pozo E., Schluter K., Nuesch E., Rosenthaler J., Kerp L.  
Pharmacokinetics of a long-acting bromocriptine preparation (Parlodel LA) and its effect on release of prolactin and growth hormone.  
*Eur. J. Clin. Pharmacol.* 29: 615, 1986.