

## Primary sarcoma of an abdominal aortic aneurysm

O. D. Defawe,<sup>1,3</sup> A. Thiry,<sup>2</sup> C. M. Lapiere,<sup>3</sup> R. Limet,<sup>1</sup> N. Sakalihan<sup>1</sup>

<sup>1</sup>*Department of Cardiovascular Surgery, University of Liège, CHU Sart-Tilman, B-4000 Sart-Tilman, Liège, Belgium*

<sup>2</sup>*Department of Pathology, University of Liège, CHU Sart-Tilman, B-4000 Sart-Tilman, Liège, Belgium*

<sup>3</sup>*Department of Connective Tissue Biology, University of Liège, CHU Sart-Tilman, B-4000 Sart-Tilman, Liège, Belgium*

### Abstract

Primary tumors of the aorta are extremely rare and the diagnosis is made most often after surgery or autopsy. Because clinical symptoms of abdominal sarcoma are similar to those of occlusive or aneurysmal disease, aortic sarcomas are frequently mistaken for these lesions. The imaging findings are frequently nonspecific and therefore do not allow a definitive preoperative diagnosis. We report a case of an epithelioid angiosarcoma in the vessel wall of an abdominal aortic aneurysm.

**Keywords :** abdominal aortic aneurysm ; Sarcoma ; Aortography ; Diagnosis

Primary tumors of the aorta are extremely rare and almost always malignant. Most aortic tumors are often confused for occlusive or aneurysmal atherosclerotic lesions and are diagnosed mainly after surgery or autopsy. We report a case of an epithelioid angiosarcoma in the vessel wall of an abdominal aortic aneurysm (AAA).

### Case report

A 50-year-old man was referred to our department with a known AAA that was 46 mm in diameter and a wall thrombus diagnosed by abdominal computed tomography (CT; Fig. 1A,B). The patient complained of left intermittent claudication, lumbar pain, sexual impotence, and significant weight loss (25 kg) in the preceding year. These physical problems were associated with psychological disorders. Aortography confirmed the diagnosis of a small aneurysm with subocclusion of the left common iliac artery (Fig. 1C). An irregular plaque of the infrarenal aorta was also observed. Aortic surgery was done to alleviate the occlusive lesions of the iliac artery and the small AAA. Aortotomy revealed an unusual cystic wall thrombus at the level of the terminal aorta and left common iliac artery. A sample of the thrombus including the aortic wall was excised for histologic analysis. An aortobiliac bifurcated graft was inserted.

The histologic investigation showed irregular, polymorphic large cells grouped in poorly cohesive sheets (Fig. 2). Atypical mitotic figures were observed. These cells showed positive immunohistologic staining for vimentin, CD31, CD34, and factor VIII but were negative for epithelial markers and smooth muscle actin. This pattern was suggestive of an epithelioid angiosarcoma.

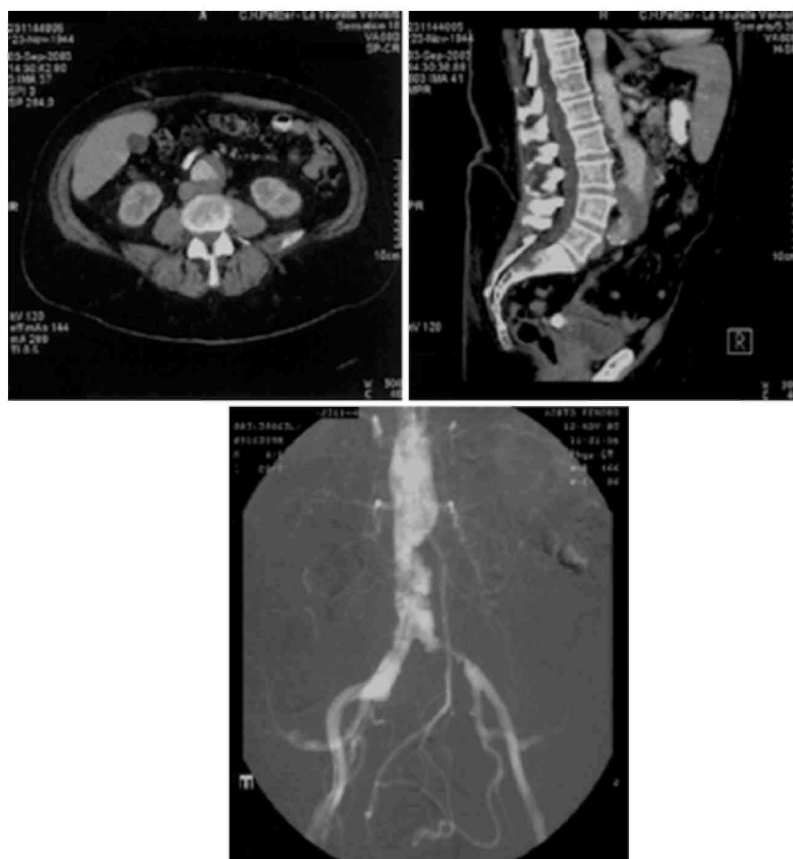Postoperatively, a whole-body positron emission tomography, scintigraphy and CT were performed to search for a primary lesion and potential metastasis. Intense fluorine 18 fluorodeoxyglucose (<sup>18</sup>F-FDG) uptake was observed at the level of the terminal aorta and at the level of right and left femurs, iliac artery, and vertebral body (Fig. 3). CT and scintigraphy demonstrated several lytic lesions in the bones of the lower part of the body (vertebral body L4, right and left iliac bones, sacrum, neck of the right femur, patella, and condyle of the left iliac bone). These osteoclastic lesions and some erosions were suggestive of metastases.

### Discussion

Fewer than 140 aortic sarcomas have been reported in the literature, with only 10 defined as angiosarcoma of the infrarenal aorta [1-3]. The median survival rate of patients with aortic sarcomas has been reported to be 7 months, which was explained by a late diagnosis combined with inadequate surgical resection [1]. The imaging findings are frequently nonspecific and in most published cases did not allow a definitive preoperative diagnosis. This requires immunohistologic examination of the tumor or peripheral emboli. These procedures help also to

establish a differential diagnosis between malignant and reactive processes. In our case, expression of CD31, CD34, and factor VIII confirmed the endothelial differentiation of the tumoral cells. Despite these techniques, histologic definition of large vessel tumors remains challenging. As a consequence, large vessel neoplasms have been classified according to their localization within the aortic wall [4]. Tumors of the media or adventitia, also called mural tumors, may appear like aneurysms or masses. Tumors involving the intima grow into the aortic lumen and are seen as vascular occlusions, whereas intraluminal tumors grow as polypoidal masses with embolic potential.

**Fig. 1.** Transverse (**Top left**) and sagittal (**Top right**) CT scans show an aneurysm of the infrarenal aorta with parietal thrombus. **Bottom** Aortogram displays a small aneurysm of the abdominal aorta with subocclusion of the left common iliac artery. An irregular stenotic plaque was also observed at the level of the terminal aorta and left common iliac artery.



Patients with abdominal aortic tumors may develop claudication, fatigue, back or abdominal pain, weight loss, or decreased peripheral pulses. Because some of these symptoms are similar to those of occlusive or aneurysmal disease, primary aortic tumors are frequently mistaken for these lesions [4, 5]. In our case, we related the intermittent claudication and sexual impotence to the iliac occlusion and the weight loss to the psychological problems related to sexual impotence. In retrospect, we realized that the AAA appearance on aortography was atypical. Intraluminal protrusive vegetations without signs of atherosclerotic plaque were observed at the level of the terminal aorta and left common iliac artery (Fig. 1C), but CT showed no calcification of the aortic wall (Fig. 1A,B). Angiographic distinction of an intraluminal malignancy from thrombus or atheroma can be difficult. We failed to recognize this rare entity preoperatively and intraoperatively, so our surgical approach was inappropriate. Ideally, adequate management is wide excision of the aortic wall and of the periaortic soft tissues. It should be kept in mind that, when a thrombus is inhomogeneous with protrusive vegetations and there is no atherosclerosis, a neoplastic lesion should be considered.

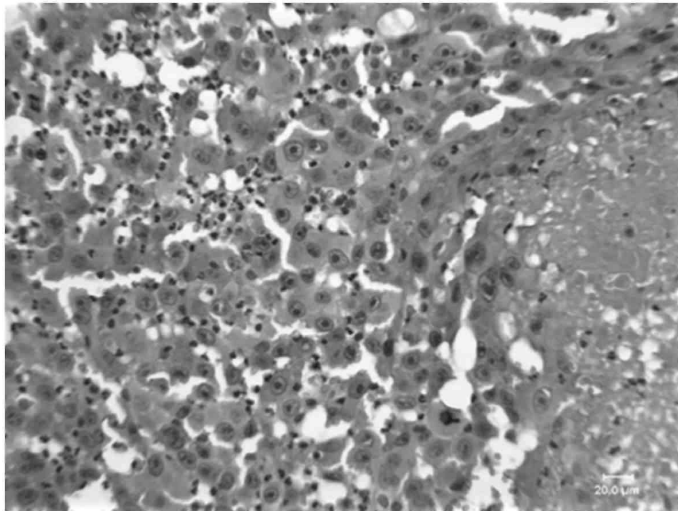
Ultrasound, CT, magnetic resonance imaging, and magnetic resonance angiography have been used to diagnose aortic sarcomas [1, 6-9]; however, the correct diagnosis has rarely been made. To our knowledge, this is the

second report to document the use of conventional aortography for diagnosing an intimal sarcoma of the aorta before autopsy. Silverman et al. [10] reported a case of primary intraluminal myxoma at the level of the ascending aorta. However, there was no reference to any protrusive vegetation in absence of atherosclerotic plaque. Recently, using contrast-enhanced CT angiography, Hagspiel et al. [3] described a primary intimal abdominal aorta sarcoma.

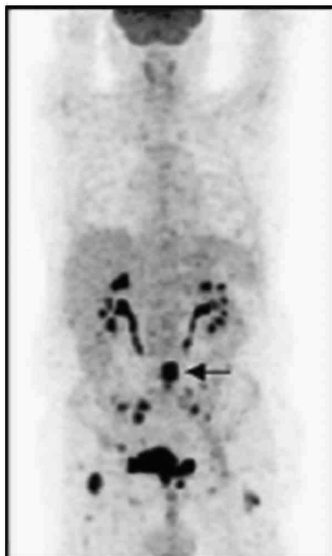Ideally, adequate management is wide excision of the aortic wall and of the periaortic soft tissues. Unfortunately, most aortic sarcoma have already metastasized at diagnosis.

Primary sarcoma in the wall of an AAA is extremely rare but the prognostic importance of this finding supports routine examination of vascular pathology. The finding, on conventional aortography, of an inhomogeneous thrombus with protrusive vegetations without signs of atherosclerotic plaque should raise suspicions as to the nature of the lesion. In selected cases, additional imaging, such as PET, may be helpful in the diagnosis of such neoplastic lesions of the aortic wall.

**Fig. 2.** Irregular polymorphic cells grouped in poorly cohesive sheets. Atypical mitotic figures are also observed. Hematoxylin and eosin, original magnification 250x.



**Fig. 3.** PET scan shows intense  $^{18}\text{F}$ -FDG uptake at the level of the terminal aorta (arrow) and at the level of the right and left femur and iliac artery.



## **Acknowledgments**

This study was supported by the Belgian Fonds Scientifique de la Recherche Médicale and Fondation L. Fredericq (FRSM 3.4566.99).

## **References**

1. Seelig MH, Klingler PJ, Oldenburg WA, Blackshear JL (1998) Angiosarcoma of the aorta: report of a case and review of the literature. *J Vasc Surg* 28:732-737
2. Chiche L, Mongredien B, Brocheriou I, Kieffer E (2003) Primary tumors of the thoracoabdominal aorta: surgical treatment of 5 patients and review of the literature. *Ann Vasc Surg* 17:354-364
3. Hagspiel KD, Hunter YR, Ahmed HK, et al. (2004) Primary sarcoma of the distal abdominal aorta: CT angiography findings. *Abdom Imaging* 29:507-510
4. Wright E, Viramini R, Glick A, Page D (1985) Aortic intimal sarcoma with embolic metastases. *Am J Surg Pathol* 9:890-897
5. Espada R, Iliopoulos D, Weilbaecher D (1966) Sarcoma presenting as thoracoabdominal aortic aneurysm: case reports and literature review. *Contemp Surg* 48:135-139
6. Bohner H, Luther B, Braunstein S, et al. (2003) Primary malignant tumors of the aorta: clinical presentation, treatment, and course of different entities. *J Vasc Surg* 38:1430-1433
7. Higgins R, Posner MC, Moosa HH, et al. (1991) Mesenteric infarction secondary to tumor emboli from primary aortic sarcoma. Guidelines for diagnosis and management. *Cancer* 68:1622-1627
8. Sekine S, Abe T, Seki K, et al. (1995) Primary aortic sarcoma: resection by total arch replacement. *J Thorac Cardiovasc Surg* 110:554-556
9. Pollock JG, Moody AR, Ludman CN, et al. (2000) Postirradiation aortic sarcoma demonstrated by magnetic resonance angiography. *J Vasc Surg* 31:798-801
10. Silverman JF, Wexler L (1972) Primary intraluminal tumor of the aorta. Case report with preoperative angiographic diagnosis. *Radiology* 102:581-582