

Endemic alveolar echinococcosis in Southern Belgium ?

O. Detry¹, C Honoré¹, J. Delwaide², J. Demonty³, A. De Roover¹, M. Vivario⁴, A. Thiry⁴, M.P. Hayette⁵, J. Belaïche², M. Meurisse¹, P. Honoré¹

(1) Dpt of Abdominal Surgery and Transplantation ; (2) Dpt of Hepatogastroenterology ; (3) Dpt of Internal Medicine, Immunodeficiency and Infectious Diseases ; (4). Dpt of Pathology ; (5) Dpt of Microbiology, University of Liège, CHU Sart Tilman B35, B-4000 Liège, Belgium.

Abstract

Until now, Belgium has been considered as a low-risk country for alveolar echinococcosis. However it was recently demonstrated by necropsy series that, in some parts of southern Belgium (Wallonia), up to 51% of the red foxes (*Vulpes vulpes*) may be infected by *E. multilocaris*. The authors, working in a university hospital in southern Belgium, described in 2002 the first autochthonous Belgian case of hepatic alveolar echinococcosis. More importantly, in 2004, they diagnosed three other patients with alveolar echinococcosis. One underwent surgical resection, but two others had bilateral pulmonary involvement at time of definite diagnosis. Palliative albendazole therapy was initiated. These patients had been diagnosed with hepatic mass from unknown origin for several months. The previous experience with the first case allowed the authors to consider and to confirm alveolar echinococcosis diagnosis, made by pathology and/or serological tests and imaging. These four patients with alveolar echinococcosis were living either in the Liege or the Luxembourg province. Considering the high prevalence of *E. multilocaris* infection of red foxes and the recent increase of the fox population due to rabies vaccination in southern Belgium, and also the presence of *E. multilocaris* infection of red foxes in northern Belgium, it is likely that not only Wallonia, but also maybe the whole Belgium, may face endemic alveolar echinococcosis in the next years. (*Acta gastroenterol. belg.*, 2005, 68, 1-4).

Key words : echinococcosis, zoonosis, liver surgery, alveolar echinococcosis.

Introduction

Alveolar echinococcosis is a life-threatening zoonosis caused by the larval stages of *Echinococcus multilocaris* (1). It has to be differentiated from infection by *E. granulosus* that develops in human in form of hydatid cysts. Until now, Belgium has been considered as a low-risk country for *E. multilocaris* infection in humans. However it was recently demonstrated by necropsy series that, in some parts of southern Belgium (Wallonia), up to 51% of the red foxes (*Vulpes vulpes*) may be infected by *E. multilocaris* (2,3), a level that should be considered as a high prevalence (4). The authors, working in a university hospital in southern Belgium, reported the first autochthonous Belgian case of hepatic alveolar echinococcosis in this journal in 2002 (5). More importantly, in 2004, they diagnosed three other patients with alveolar echinococcosis. The aim of this report is to summarize these cases to better inform the medical community on this possible diagnosis in Belgium. The authors also shortly review the pathology and the treatment of this disease.

Case reports

Case 1

A 61-year old man living in the Luxembourg province was suffering from emphysema and underwent a thoracic computed tomography (CT). This exam showed a 45 mm lesion in the right liver lobe, considered as a malignant secondary liver mass. Complete exploration was undertaken, including research for the primary lesion (gastroscopy, colonoscopy), abdominal CT (Fig. 1), positron emission tomography. This exploration was not contributive. Explorative laparoscopy demonstrated a segment IV liver mass. Biopsies were not conclusive and the patient was sent for partial liver resection. Pathology of resected segments demonstrated alveolar echinococcosis (Fig. 2 and Fig. 3). Post-operative echinococcus serology was positive. Adjuvant albendazole (Zentel) therapy was initiated.

Case 2

A 70-year old man living in the Liege province with past history of chronic myeloid leukaemia was diagnosed with a left liver mass in 2003. Serology for filaria and strongyloidiasis was positive and mebendazole (Vermox, Janssen, Belgium) treatment was initiated. In July 2004 a liver CT showed progression of the disease with invasion of the right part of the liver. Thoracic CT demonstrated bilateral metastases. *Echinococcus* serology became positive, although it was negative in 2003. Alveolar echinococcosis was diagnosed and palliative albendazole therapy was initiated.

Case 3

A 76-year old man living in the Luxembourg province had past history of chronic myelomonocytic leukaemia. In 2002 an abdominal CT showed a large right liver lesion. Follow-up showed slow size increase (Fig. 4). *Echinococcus* serology was slightly positive in August 2004 and alveolar echinococcosis was diagnosed. Albendazole therapy was initiated. In September

Correspondence : Dr Olivier Detry, Dpt of Abdominal Surgery and Transplantation, University of Liège, CHU Sart Tilman B35, B-4000 Liège, Belgium. E-mail : Oli.Detry@chu.ulg.ac.be.

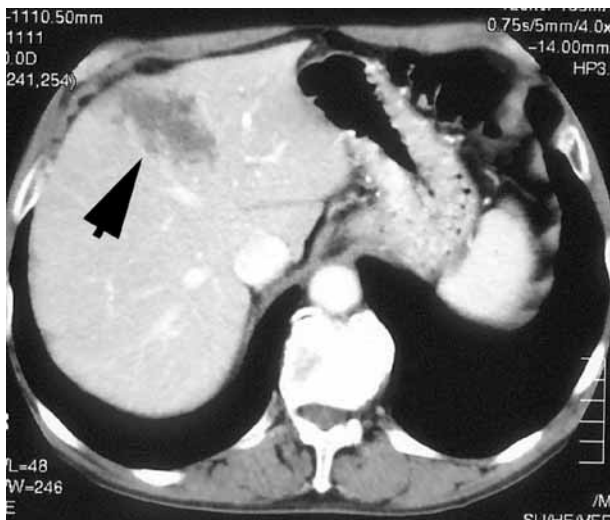


Fig. 1. — Computed tomography of the liver (case 1) ; showing hepatic segment IV infection by *E. multilocaris*.

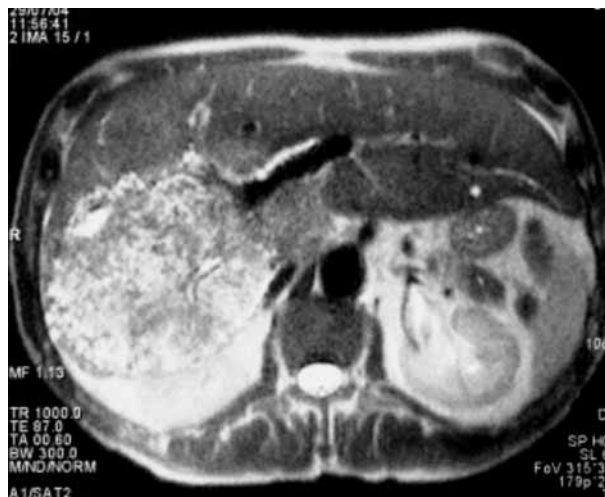

Fig. 4. — Magnetic resonance imaging of the liver (case 3), showing a large, polycystic mass of the right liver.

EN COULEUR ?



Fig. 2. — Gross photography of the resected liver section (case 1), showing a solid, white mass with irregular multilocular, necrotic and cystic cavities containing thick pasty material ; absence of fibrous rim.

EN COULEUR ?

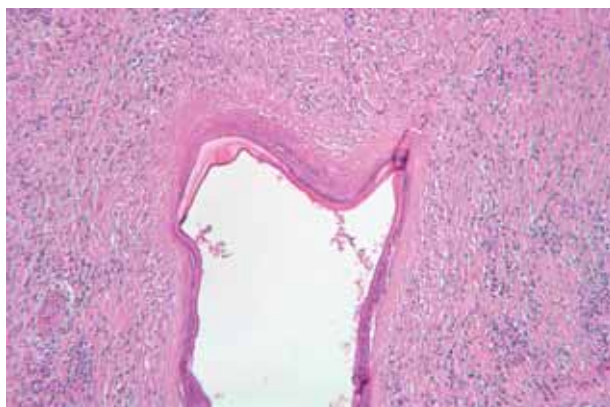


Fig. 3. — Pathology of the resected tissue (hematoxylin-eosin, 25 ×) showing a cystic formation surrounded by a laminar ringed membrane ; protoscolices are limited by necrosis, fibrosis and inflammatory reaction (case 1).

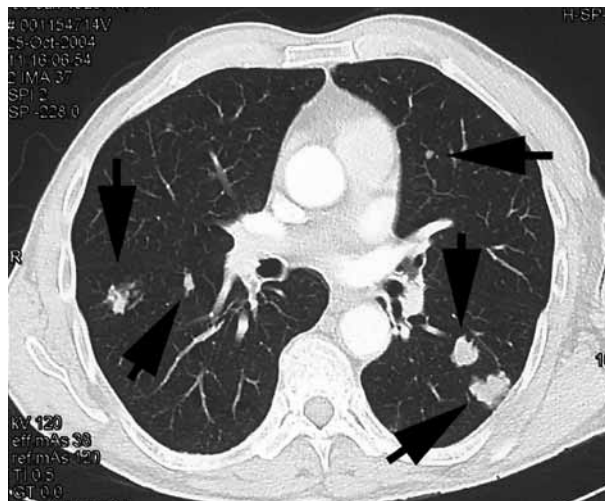


Fig. 5. — Computed tomography of the chest (case 3) showing pulmonary *E. multilocaris* metastases.

2004 a thoracic CT showed several pulmonary lesions without pleural effusion or adenopathy (Fig. 5).

Discussion

These three patients, added to the case described in 2002 (5), were the first patients suffering from alveolar echinococcosis encountered in the authors' experience, and the first patients published in Belgium to date, despite the evocation of up to 6 Belgian contaminated patients (6). All our patients were over 60 years of age, and none had a particular history of journey in endemic regions for alveolar echinococcosis. Another interesting evidence is that three of these patients had some degree of decreased immunity (corticosteroid therapy or chronic leukaemia). In the four cases, the diagnosis of alveolar echinococcosis was late, either on the hepatectomy

specimen, or after extra hepatic involvement contraindicating radical surgical procedure. These late diagnoses may be linked to the fact that until recently Belgium has been considered as a low-risk country for alveolar echinococcosis. However it was recently demonstrated by necropsy series that, in some parts of southern Belgium, up to 51% of the red foxes may be infected by *E. multilocaris* (2,3). Considering this high prevalence of *E. multilocaris* infection of red foxes and the recent increase of fox population due to rabies vaccination in southern Belgium, added to the first reports of human cases, it is likely that this region will face endemic alveolar echinococcosis in the next years. In addition, other necropsy studies showed that in northern Belgium, red foxes might also be infected by *E. multilocaris* (6), although at a lower rate than in southern Belgium. Therefore, for these reasons added to the small size of Belgium, the authors considered that cases of alveolar echinococcosis might be diagnosed in the whole country in the next future.

E. multilocularis cycle

The adult *E. multilocularis* is a tapeworm living attached to the small intestine of the definitive host, mainly the red fox, but dogs and cats are also vulnerable (1). When the gravid proglottis arrives to maturity, it is released in the faeces with 400 to 800 eggs. The eggs contain the oncospheres, which have six hooks surrounded by protective envelopes. The cycle continues if field rodents (intermediate carriers) ingest the eggs. Reaching the stomach of an intermediate host, the oncospheres are released from their protective coat, and by means of its larval hooks, penetrate the intestinal wall. The oncospheres migrate via the portal circulation to the liver, where most are deposited and develop. When the intermediate host dies and his vital organs are devoured, each consumed scolex may transform in an adult larva in the small intestine of the definitive host. Human beings are accidental intermediate hosts in this cycle, and may be contaminated mainly by eating wild berries such as wood strawberries, blackberries, blueberries or many other vegetables that could be soiled with foxes excrements, or by contacts with contaminated foxes or domestic animals (1).

Clinical features

Asymptomatic incubation may last 5 to 15 years. Immunosuppression is believed to favour more rapid disease progression. The peak age group for infection is from 50 to 70 years (1). The metacestode develops almost exclusively primarily in the liver (99% of cases). Thirteen percent of cases present as multiorgan disease where metacestodes involve the lungs, spleen or brain in addition to the liver (1). Alveolar echinococcosis symptoms are due to progressive hepatic invasion. One-third of cases present with cholestatic jaundice, one-third with epigastric pain, and the remainder present with vague

symptoms like weight loss or fatigue, or are noted to have incidental hepatomegaly. Untreated or inadequately managed cases have high fatality rates (1).

Diagnosis

Definite diagnosis may be made by physical imaging methods, as ultrasonography, CT, and magnetic resonance imaging (7), in addition to serology (1). Immunodiagnosis is useful not only in primary diagnosis but also for follow-up of patients after surgical or pharmacological treatment (1). Antibody detection by Em2plus ELISA has proved especially valuable. As there are some antigen similarities between *E. granulosus* and *multilocaris*, ELISA tests for *E. granulosus* may be positive in alveolar echinococcosis. Percutaneous or laparoscopic biopsies are most often non-contributive and are not necessary for the diagnosis of *E. multilocaris* infection if imaging and serology are positive.

Treatment

Radical surgical resection – as for hepatic malignancy – is the only curative method for alveolar echinococcosis, stressing the importance of early diagnosis (1). Perioperative and long-term adjuvant therapy with albendazole (doses up to 20 mg/kg/day) has been associated with improved results. Albendazole is only parasitostatic against *E. multilocaris*, and should be continued for two years after surgery (1). In palliative management, long-term albendazole therapy is advocated. Amphotericin B was recently proposed in cases of resistance to albendazole (8). The role of life-long chemosuppression is being explored. Liver transplantation has been undertaken in patients with alveolar echinococcosis (9,10) but the immunosuppression linked to transplantation may favour increased development of extra hepatic disease.

Prevention and control

Primary prevention could be to treat all definitive hosts, foxes and dogs, with praziquantel (Biltricide) (11). However, this chemotherapy is difficult to apply at a large scale. Vaccination of definite or intermediate hosts is subject to research (1). For human, primary prevention consists of avoiding eating fresh vegetables or fruits that grow at less than 50 cm from the ground, and avoiding contact with wild foxes and dogs. Vegetable cooking (at least 10 min at 60°C, 5 min at 70°C, or 1 min at 100°C), but not freezing, is efficient to inactivate the eggs (oncospheres).

In summary, these cases demonstrated that in southern Belgium, alveolar echinococcosis should be considered as a potential diagnosis of any liver mass. Appropriate information of the Belgian medical doctors is crucial as only early diagnosis may allow surgical curative treatment. Considering the infection of *E. multilocaris* of red foxes and the recent increase of fox population due to rabies vaccination, it is likely that

southern Belgium, but also maybe the whole Belgium, may face endemic alveolar echinococcosis in the next future.

References

1. MCMANUS D.P., ZHANG W., LI J., BARTLEY P.B. Echinococcosis. *Lancet*, 2003, **362** (9392) : 1295-304.
2. LOSSON B., KERVYN T., DETRY J., PASTORET P.P., MIGNON B., BROCHIER B. Prevalence of Echinococcus multilocularis in the red fox (*Vulpes vulpes*) in southern Belgium. *Vet. Parasitol.*, 2003, **117** (1-2) : 23-8.
3. LOSSON B.J., MIGNON B., BROCHIER B., BAUDUIN B., PASTORET P. Infestation du renard roux (*Vulpes vulpes*) par Echinococcus multilocularis dans la province de Luxembourg (Belgique) : résultats de l'enquête effectuée entre 1993 et 1995. *Ann. Med. Vet.*, 1997, **141** : 149-153.
4. KERN P., BARDONNET K., RENNER E. *et al.* European echinococcosis registry : human alveolar echinococcosis, Europe, 1982-2000. *Emerg. Infect. Dis.*, 2003, **9** (3) : 343-9.
5. DELBECQUE K., DETRY O., HAYETTE M.P. *et al.* A case of hepatic alveolar echinococcosis contracted in Belgium. *Acta Gastroenterol. Belg.*, 2002, **65** (1) : 55-60.
6. VERVAEKE M., DORNY P., VERCAMMEN F. *et al.* Echinococcus multilocularis (Cestoda, Taeniidae) in Red foxes (*Vulpes vulpes*) in northern Belgium. *Vet. Parasitol.*, 2003, **115** (3) : 257-63.
7. COSKUN A., OZTURK M., KARAHAN O.I., ERDOGAN N., ISIN S., GULEC M. Alveolar echinococcosis of the liver : correlative color dopler US, CT, and MRI study. *Acta Radiol.*, 2004, **2004** (45) : 492-498.
8. REUTER S., BUCK A., GREBE O., NUSSLE-KUGELE K., KERN P., MANFRAS B.J. Salvage treatment with amphotericin B in progressive human alveolar echinococcosis. *Antimicrob. Agents Chemother.*, 2003, **47** (11) : 3586-3591.
9. KOCH S., BRESSON-HADNI S., MIGUET J.P. *et al.* Experience of liver transplantation for incurable alveolar echinococcosis : a 45-case European collaborative report. *Transplantation*, 2003, **75** (6) : 856-863.
10. MBOTI B., VAN DE STADT J., CARLIER Y. *et al.* Long-term disease-free survival after liver transplantation for alveolar echinococcosis. *Acta Chir. Belg.*, 1996, **96** (5) : 229-232.
11. DEPLAZES P., HEGGLIN D., GLOOR S., ROMING T. Wilderness in the city : the urbanization of Echinococcus multilocularis. *Trends Parasitol.*, 2004, **20** : 77-84.