

Laparoscopic myolysis

Jacques Donnez*, Jean Squifflet, Roland Polet and Michelle Nisolle

Département de Gynécologie, Université Catholique de Louvain, Cliniques Universitaires St Luc–UCL, Avenue Hippocrate 10, B-1200 Brussels, Belgium

This review will focus on the different techniques and the long-term effects of the technique called myolysis on myoma growth. Indications for myolysis are essentially pelvic pain, compression symptoms and global uterine volume in order to avoid hysterectomy. In the late 1980s, myolysis was performed laparoscopically with the help of the neodymium: yttrium aluminium garnet (Nd:YAG) laser. Later, bipolar needles were developed as an alternative to the Nd:YAG laser. Diathermy and cryomyolysis were also proposed but series are small in the literature. Very recently, myoma interstitial thermo-therapy (MITT) was performed using the diode laser and a specific optical light diffuser that is designed to transmit laser light in all directions. Laparoscopic myolysis was proved to be effective in provoking myoma shrinkage, with a dramatic decrease in size and a marked devascularization of the myoma and this technique can be proposed as an alternative to myomectomy in selected patients: only those aged >40 years or those not desiring to bear any more children.

Key words: cryomyolysis/laser surgery/myolysis/myomata/thermo-therapy

TABLE OF CONTENTS

Introduction
Indications
The first series of myolysis with Nd:YAG laser
Myolysis with bipolar needles
Myolysis with diathermy
Cryomyolysis
Myoma interstitial thermo-therapy (MITT)
Reoperation and pregnancy
Discussion
References

Introduction

Uterine fibroids are common, benign, solid tumours of the genital tract and, depending on their size and location, can lead to hysterectomy. In the early 1990s, advanced operative laparoscopy techniques have been developed and large uterine fibroids can now be removed laparoscopically in patients wishing to avoid hysterectomy (Daniell and Gurley, 1991; Dubuisson *et al.*, 1991). On the other hand, laparoscopic myolysis has been proposed in cases of subserous or intramural myomata as an alternative to myomectomy or hysterectomy. This technique was first performed in the late 1980s in Europe. In fact, the concept of myolysis was firstly initiated by Donnez *et al.* (1989, 1990) for hysteroscopic myolysis and then applied to laparoscopic myolysis (Nisolle *et al.*, 1993). Initially, myoma coagulation was viewed as

an alternative to myomectomy for women interested in preserving fertility. Using the energy of the neodymium:yttrium aluminium garnet (Nd:YAG) laser, leiomyomata were coagulated around the point of laser penetration, necrosing the myometrium, denaturing protein and destroying vascularity. No reports on the procedure appeared in the USA until Goldfarb reported his first series (Goldfarb, 1992). As an alternative to myomectomy and hysterectomy, the author performed myoma coagulation on leiomyomata up to 10 cm in diameter, but limited the procedure to post-reproductive and perimenopausal women.

Here, we evaluate the different techniques and the long-term effects of the technique called myolysis on myoma growth. Indications for myolysis are: (i) pelvic pain; (ii) compression symptoms; and (iii) global uterine volume (in comparison with pregnancy) at 9–12 weeks, in order to avoid hysterectomy (Nisolle *et al.*, 1993).

Myolysis was also considered as an alternative to laparoscopic myomectomy if myomectomy was judged to be too difficult or not mandatory, or in cases of multiple intramural myomata to avoid a time-consuming laparoscopic myomectomy.

The first series of myolysis with Nd:YAG laser

In the late 1980s, myolysis was proposed to 48 women who were aged >35 years of age with intramural myomata up to 8 cm in diameter who did not wish to bear any more children (Nisolle *et al.*, 1993, 1994). The mean age of the women was 42 years (range 35–48 years). Myomata were diagnosed by pelvic examination.

*To whom correspondence should be addressed at: Département de Gynécologie, Université Catholique de Louvain, Cliniques Universitaires St Luc–UCL, Avenue Hippocrate 10, B-1200 Brussels, Belgium. Tel: +32-2-764 95 01; Fax: +32-2-764 95 07; E-mail: donnez@gyne.ucl.ac.be

Their size and location were confirmed by ultrasonography. Vascularization was evaluated using Doppler ultrasound with colour flow imaging. No previous laparoscopy had been performed in these women.

Technique

Laparoscopy was performed transumbilically using a 10 mm endoscope adapted to a video camera. The instruments were introduced through three suprapubic puncture sites (5 mm in diameter). The bare laser fibre was introduced as perpendicularly as possible into the fibroid through a second puncture trocar to a depth depending on the myoma diameter. During the application of laser energy, the fibre was introduced, reaching the central part of the fibroid, and was then removed slowly in order to provoke a 'strong coagulation'. The power used was 80 W. The procedure was repeated on the entire surface of the myoma in order to coagulate most of the myoma volume. The surface of the myoma was rinsed with 0.9% saline solution during the laser application to reduce thermal conduction through the uterine wall. The distance between holes was ~5–7 mm.

Vasopressin (POR8; Sandoz, Brussels, Belgium) was never used to infiltrate the myometrium adjacent to the fibroid to induce temporary myometrial ischaemia, reducing blood loss. However, in one case, diluted vasopressin was required to obtain complete uterine haemostasis: 5 IU of vasopressin in 20 ml of saline solution was injected just around the haemorrhagic site at the end of the procedure.

Immediately following myolysis, many laser scars can be seen on the myoma, which appears paler than normal. In the last 10 cases, an Interceed graft (Johnson and Johnson, New Brunswick, NJ, USA) was used to cover the coagulated area after haemostatic control was obtained, in order to decrease the risk of adhesions. Careful aspiration of peritoneal fluid was then carried out and a suction catheter was left in the Pouch of Douglas.

In the first series of 48 patients, none required laparotomy for bleeding, and no bladder or bowel injury was reported. During surgery, some problems arose because of difficult accessibility to posterior myomata by the laser fibre, introduced through a second puncture. In such cases, the laser fibre can be introduced directly through the laparoscope to achieve better accessibility.

The estimated blood loss was minimal (<50 ml) in all cases but one. The operating time varied from 20 to 45 min, depending on the myoma diameter and number. All patients were released in good physical condition the following day; none experienced any post-operative infection or haemorrhage.

Evaluation of myoma size

The number, size and location of the myomata were evaluated by vaginal echography before laparoscopic myolysis. The size of the myomata, measured by ultrasound, were 3–8 cm in diameter. Post-operatively, myoma evaluation was echographically performed at weeks 3, 6 and 12, after 6 months and after 1 year, 15 patients were evaluated after 3 years. Changes in the myoma structure and size were analysed by echography. In the first 3 weeks, areas of necrosis were suspected by the presence of numerous anechogenic areas in the myoma. Subsequently, a more echogenic structure appeared.

Fibroids treated by myolysis ranged from 3 to 8 cm in diameter. The mean decrease in the myoma diameter after myolysis was 4%

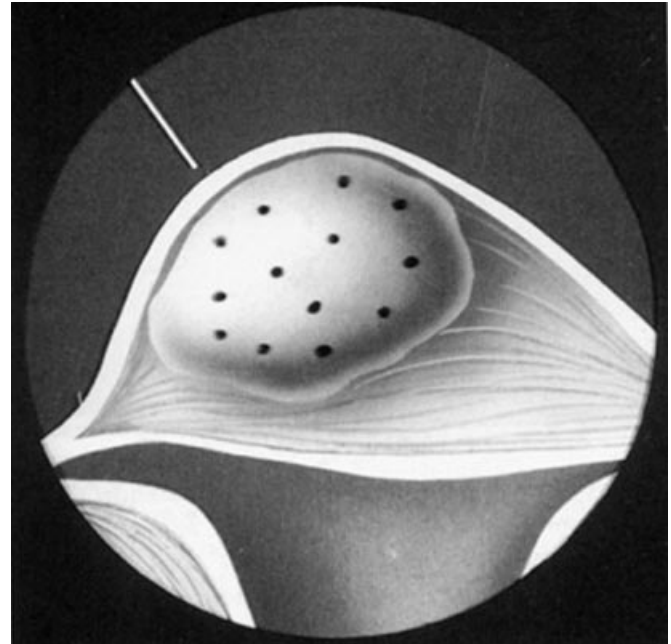


Figure 1. Under laparoscopic view, the bare fibre is introduced into the myoma, creating areas (holes) of coagulation.

(range 0–6%) at week 6, 12% (range 2–18%) at week 12 and 41% (range 18–62%) after 6 months. The echostructure of the coagulated myoma was such that only experienced echographers could really distinguish the limits of the myoma.

The results observed after 1 year were similar to those seen after 6 months; there was neither any further decrease in size nor a regrowth of the myoma.

After 3 years, 15 patients were evaluated by echography. In 10 of them who had two to three myomata (3–5 cm in diameter), echography revealed only small areas (<1 cm in diameter) whose echographic structure was slightly different from the normal myometrium. Among the five remaining patients, three were stable and two showed a reappearance of myomata in other sites. The two last patients underwent laparoscopic subtotal hysterectomy. Only a few adhesions were present. Failure of the treatment, indicated by an absence of any significant decrease in the myoma diameter, was never observed.

Complications: adhesions confirmed by second-look laparoscopy

In fifteen patients, a second-look laparoscopy was carried out >6 months after myolysis for other reasons (ovarian cyst, sterilization, etc). The appearance of the myoma was made. In eight cases, dense and fibrous adhesions were observed between the myoma and, most frequently, the small bowel and/or epiploon. After adhesiolysis, the myoma appeared white without any apparent vessels. In two cases, we decided to remove the myoma. Dissection of the myoma from the normal myometrium was surprisingly easy and the myomata were removed in order to evaluate histologically the efficacy of myolysis. There was necrosis in most myoma areas, characterized by oedema and an absence of viable cells. In other areas, giant cells and macrophages containing carbonized particles very close to the necrotic sites suggested that necrosis was really induced by the laser coagulation.

Myolysis with bipolar needles

Use of the Nd:YAG laser for myoma coagulation has certain disadvantages: the laser creates a large amount of smoke, which can obscure visibility. Inexpensive bipolar needles were developed as an alternative to the Nd:YAG laser. First used in Hamburg in 1993 by Adolphe Gallinat (Gallinat and Lueken, 1993), the bipolar needles were short (1.5 cm) and appropriate only for smaller myomata. Two years later, another bipolar needle instrument was designed by Goldfarb in the USA (Goldfarb, 1995). There are two forms of the bipolar instruments: (i) a 30 cm instrument with a 5 cm probe and (ii) a 45 cm probe that can be passed through the operating laparoscope. The 45 cm bipolar needles passed through the operating laparoscope enabled the surgeon to coagulate a posterior myoma. Using the bipolar instrument, thorough coagulation of a 7 cm leiomyoma could be achieved in 20 min.

In 150 procedures performed laparoscopically, no serious complications were reported as a result of using this instrument; however, one patient developed pelvic abscess and subsequently underwent hysterectomy. Another patient developed bacteraemia and made an uneventful recovery after antibiotic therapy (Goldfarb, 1992).

The coagulating of the myoma with the bipolar needles devascularized the leiomyoma, resulting in leiomyoma shrinkage of 30–50% beyond the effect attributable to gonadotrophin-releasing hormone (GnRH) therapy.

Recent results in a series performed by Phillips (1995, 1997) has confirmed the efficacy of myoma coagulation. Prior to myoma coagulation, patients were pretreated with depot leuprolide. Leiomyomata were measured using a formula for the volume of an ellipsoid to achieve a volumetric evaluation of the leiomyoma before and after reduction. Within 6 months of surgery satisfactory results were achieved in 97.4% of patients. At 3–6 months after the operation, there was an 83.1% decrease in mean total uterine volume, an 88.5% reduction in mean total leiomyoma volume, and a 60% reduction in the mean longest leiomyoma diameter (compared with premedication measurements).

Myolysis with diathermy

One author (Chapman, 1993) reported on 18 patients with leiomyomata treated by myoma coagulation who were not ruled out if they wished to preserve fertility. Treatment involved exposing the myoma via laparotomy and then drilling holes with a carbon dioxide laser. To achieve coagulation, a diathermy electrode was inserted into each hole and the surrounding myoma was heated to achieve protein denaturation. Four of the 18 women subsequently became pregnant. Diathermy thus may be another promising method of treating myomata while minimizing adhesion formation.

Cryomyolysis

According to Zreik, cryomyolysis maintains at or slightly reduces myomata to post-GnRH agonist size, and all other uterine tissue returns to pretreatment size (Zreik *et al.*, 1998). The cryoprobe track was begun as a small hole through the uterine serosa with a monopolar needle.

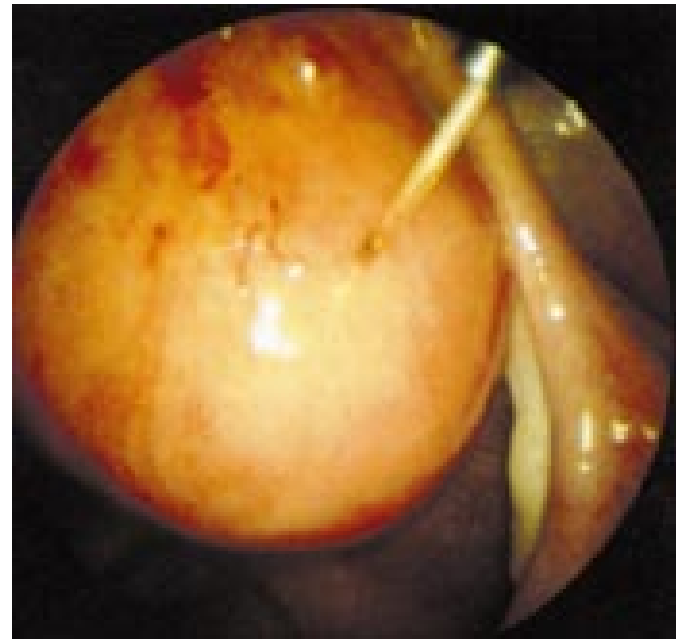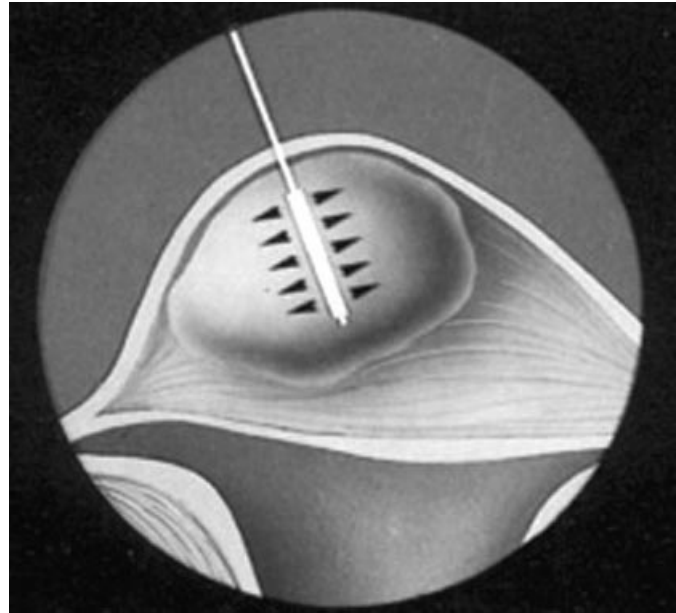


Figure 2. (a) Under laparoscopic control, the new fibre for interstitial thermo-therapy (ITT) is introduced into the myoma (b) endoscopic view: Myolysis is carried out using the bare fibre. The size of the myoma is 4.5cm.

The experience with cryomyolysis was limited to a prospective pilot study (Zreik *et al.*, 1998). A total of 14 patients were treated with a GnRH analogue for ≥ 2 months to decrease myoma size, with magnetic resonance imaging (MRI) being performed initially to determine shrinkage of the uterus. A second MRI was carried out 4 months after surgery and discontinuation of the GnRH analogue therapy, when regrowth of the uterus to its original size would be expected.

Myoma volume decreased by 6% over 4 months post-operatively in all 14 patients, with several patients having a decrease of >50%. Thus, it appears that reduction in myoma size by GnRH agonists can be prolonged or even enhanced by cryomyolysis, despite a return to the pretreatment size of normal

uterine tissue. Four of the six women undergoing second-look office laparoscopy had adhesion formation at freezing sites. Most were filmy and easily lysed at laparoscopy, but they were severe in one patient.

Myoma interstitial thermo-therapy (MITT)

Recently, Donnez *et al.* presented in Stockholm the first cases of myoma treated by interstitial thermo-therapy using one specific laser fibre, as has been described in endometrial laser intrauterine thermo-therapy (ELITT) procedure (Donnez *et al.*, 1999a,b). After having made a hole in the myoma serosa with the help of a trocar (1.5 mm), the laser fibre was introduced in the myoma. The fibre consists of an optical light diffuser that is designed to transmit laser light in all directions to effect the destruction of the myoma by hyperthermia. Although this new method seems to be very promising to avoid adhesions, long-term results on myoma growth are necessary before proposing this method for myolysis. The procedure employs a laser light to destroy the myoma by thermal therapy, increasing the temperature of the myoma to induce coagulation. The laser light is diffused inside the myoma in all directions. The 830 nm wavelength laser light penetrates the myoma wall to a precise depth, and it is absorbed by the haemoglobin. The absorbed light is then transformed to heat, it warms the myoma and causes controlled coagulation. The inherent light scattering inside the myoma contributes positively to the uniformity of the light distribution and resultant coagulation. A compact tabletop 20 W, 830 nm diode laser is available for this kind of surgery.

Reoperation and pregnancy

In the different studies published in the literature, the reoperation rate (hysterectomy) was found varying from 3–5% (Goldfarb, 1995) to 10% after 5 years (Donnez *et al.*, 1999b). Some authors have proposed this techniques in order to reduce the myoma size before pregnancy. In our group, we have always considered myolysis as a contra-indication. Although other authors (Chapman, 1993; Phillips, 1995) are in favour of pregnancy after myolysis, recent papers reporting cases of uterine rupture during pregnancy (Arcangeli and Pasquarrette, 1997; Vilos *et al.*, 1998) strongly suggest that myolysis is indicated only in women who do not desire further pregnancy.

Discussion

Myomata are very common in women of reproductive age and may be responsible for menorrhagia, anaemia, pelvic pain, compression, infertility or miscarriage. However, myomata are often asymptomatic and may not require treatment. In such asymptomatic patients, indications for myomectomy are debatable; therapy may be considered in some cases to prevent complications related to the growth of the myoma. Since the early 1990s, uterine fibroids can be treated endoscopically (Donnez *et al.*, 1989, 1990; Daniell and Gurley, 1991; Dubuisson *et al.*, 1991; Nezhat *et al.*, 1991).

As previously described, in cases of submucosal uterine fibroids, hysteroscopic myomectomy (Donnez *et al.*, 1989, 1990) is carried out if the greater diameter of the leiomyoma is

inside the uterine cavity. In cases of very large fibroids whose largest diameter is not inside the uterine cavity, the protruding portion is removed and the intramural portion is devascularized by introducing the laser fibre into the myoma, at a length depending on the depth of the remaining intramural portion (Donnez *et al.*, 1990, 1993). This technique proved to be effective in provoking myoma shrinkage, with a dramatic decrease in size and a marked devascularization of the myoma. This concept of myolysis was thus firstly described in hysteroscopic techniques in the late 1980s and then applied to the laparoscopic approach in the treatment of intramural myomas in women who do not desire further pregnancy (Nisolle *et al.*, 1993).

In cases of subserosal and intramural fibroids, myomectomy can also be carried out laparoscopically by an incision through the uterine serosa with a needle tip or knife electrode unipolar cautery, a potassium titanyl phosphate (KTP)/YAG laser in KTP mode, or hook scissors. The exposed fibroid is separated from the myometrium and removed by the combination of traction, twisting and cutting (Dubuisson *et al.*, 1991). Serosal reapproximation can be accomplished with a bipolar coagulator in cases of small fibroids (<3 cm), sutures or fibrin glue (Tissucol[®] fibrin sealant; Immuno AG, Vienna, Austria). The excised fibroids are removed from the abdominal cavity via a posterior colpotomy, through suprapubic anterior wall incisions or through the operating channel of the laparoscope after fragmentation, depending on the size of the tumour.

Sometimes, in cases of large intramural fibroids or multiple myomata, laparoscopic myomectomy can be difficult or time-consuming (Nezhat *et al.*, 1991). Laparoscopic myolysis can be proposed as an alternative to myomectomy, performed by laparoscopy or laparotomy in cases of large or multiple intramural fibroids (Nisolle *et al.*, 1993). The fibroids are not removed but coagulated with the help of the YAG laser (Nisolle *et al.*, 1993), bipolar coagulation (Goldfarb, 1995, 2000), cryoprobe (Zreik *et al.*, 1998), monopolar coagulation (Chapman, 1993) and very recently diode laser (MITT) (Donnez *et al.*, 1999 b). The myoma coagulation is followed by necrosis and the size of the myoma decreases dramatically. The success of myolysis to treat myomata has been reported by many investigators (Goldfarb, 1992, 1995a,b, 2000; Chapman, 1993; Gallinat and Lueken, 1993; Nisolle *et al.*, 1993, 1994; Wood *et al.*, 1994; Phillips, 1995). The Nd:YAG laser was used for the first time by Nisolle *et al.* (1993) and a decrease of 50% was found without regrowth of the myomata after 12 months. Since the first report, all authors reported large series which have confirmed the leiomyoma shrinkage of 30–50%.

With regard to cost-effectiveness, myolysis has the obvious economic benefits of outpatient surgery and rapid recovery and return to a normal life-style. Moreover, the subsequent reoperation rates for recurrence or persistence of symptoms are quite low.

The final question is whether myolysis can be offered to women who wish to bear children. According to the literature, the issue is controversial. Published data have clearly demonstrated that viable pregnancies are possible after laparoscopic myolysis (Chapman, 1993; Wood *et al.*, 1994; Phillips *et al.*, 1995), but the possibility of coagulation and devascularization of the myometrium exists, as does (at least theoretically), the possibility of uterine rupture in cases of pregnancy (Arcangeli and Pasquarrette, 1997; Vilos *et al.*, 1998). The patients must thus be selected

carefully: only those aged >40 years or those not desiring to bear any more children but wishing to avoid a future hysterectomy can undergo a myolysis.

Long-term follow-up has shown that there is no regrowth of the myoma (Nisolle *et al.*, 1993, 1994). Histology proved the complete devascularization of the myoma with subsequent necrosis. However, when performed, second-look laparoscopy demonstrated the presence of very dense adhesions in ~10–50% of cases. In order to reduce the risk of adhesions, Interceed was placed on the coagulated area (Nisolle *et al.*, 1993; Chapman, 1993; Phillips *et al.*, 1995). Randomized studies must be carried out in the future in order to prove the efficacy of Interceed in this situation.

In order to reduce adhesions, new laser fibres, Interstitial Thermo-Therapy (ITT) fibres (ESC Sharplan, Tel Aviv, Israel) are now being evaluated. In this type of fibre, diffusion of the heat inducing the necrosis occurs along the terminal part of the fibre. Only one hole is required and this reduces the lesion of the myoma serosa.

In conclusion, myolysis is effective in the reduction of myoma size and can be proposed as an alternative to myomectomy, but only in selected patients. Because of the risk of bowel adhesions and of coagulation of the myometrium, this type of surgery must be reserved for large, intramural, symptomatic myomata when endoscopic myomectomy is considered to be too difficult or time-consuming.

References

- Arcangeli, S. and Pasquarrette, M. (1997) Gravid uterine rupture after myolysis. *Obstet. Gynecol.*, **89**, 857.
- Chapman, R. (1993) Treatment of uterine myomas by interstitial hyperthermia. *Gynecol. Endoscopy.*, **2**, 227.
- Daniell, J.F. and Gurley, L.D. (1991) Laparoscopic treatment of clinically significant symptomatic uterine fibroids. *J. Gynecol. Surg.*, **7**, 37–39.
- Donnez, J. (1993) Nd:YAG laser hysteroscopic myomectomy. In Sutton, C. and Diamond, M. (eds), *Endoscopic Surgery for Gynecology*. W.B.Saunders Company Ltd, London, UK, pp. 331–337.
- Donnez, J., Schrurs, B., Gillerot, S. *et al.* (1989) Treatment of uterine fibroids with implants of gonadotropin releasing-hormone agonist: assessment by hystero-graphy. *Fertil. Steril.*, **51**, 947–950.
- Donnez, J., Gillerot, S., Bourgonjon, D. *et al.* (1990) Neodymium:YAG laser hysteroscopy in large submucous fibroids. *Fertil. Steril.*, **54**, 999–1003.
- Donnez, J., Polet, R., Squifflet, J. *et al.* (1999a) Endometrial laser intrauterine thermo-therapy (ELITT): a revolutionary new approach to the elimination of menorrhagia. *Curr. Opin. Obstet. Gynecol.*, **11**, 363–370.
- Donnez, J., Polet, R., Squifflet, J. *et al.* (1999b) Laparoscopic myolysis. *Gynecol. Endoscopy* (Proceedings of the ESGE meeting, Stockholm).
- Dubuisson, J.B., Lecuru, F., Foulot, H. *et al.* (1991) Myomectomy by laparoscopy: a preliminary report of 43 cases. *Fertil. Steril.*, **56**, 827–830.
- Dubuisson, J.B., Chapron, C., Fauconnier, A. *et al.* (1997) Laparoscopic myomectomy and myolysis. *Curr. Opin. Obstet. Gynecol.*, **9**, 233–238.
- Gallinat, A. and Lueken, R.P. (1993) Current trends in the therapy of myomata. In Leuken, R.P. and Gallinat, A. (eds) *Endoscopic Surgery in Gynecology*. Demeter Verlag GmbH, Berlin, Germany, pp. 88–71.
- Goldfarb, H.A. (1992) Nd:YAG laser laparoscopic coagulation of symptomatic myomas. *J. Reprod. Med.*, **37**, 636.
- Goldfarb, H.A. (1995a) Laparoscopic coagulation of myoma (myolysis). *Obstet. Gynecol. Clin. North Am.*, **22**, 807–819.
- Goldfarb, H.A. (1995b) Bipolar laparoscopic needles for myoma coagulation. *J. Am. Assoc. Gynecol. Laparosc.*, **2**, 175–179.
- Goldfarb, H.A. (2000) Myoma coagulation (myolysis). *Obstet. Gynecol. Clinics North Am.*, **27**, 421–430.
- Nezhat, C., Nezhat, F., Silfen, S.L. *et al.* (1991) Laparoscopic myomectomy. *Int. J. Fertil.*, **36**, 275–280.
- Nisolle, M., Smets, M., Gillerot, S. *et al.* (1993) Laparoscopic myolysis with the Nd:YAG laser. *J. Gynecol. Surg.*, **9**, 95–99.
- Nisolle, M., Smets, M., Gillerot, S. *et al.* (1994) Laparoscopic myolysis with the Nd:YAG laser. In Donnez, J. and Nisolle, M. (eds), *Atlas of Laser Operative Laparoscopy and Hysteroscopy*. Parthenon Publishing Group, Carnforth, UK, pp. 187–193.
- Phillips, D. (1995) Laparoscopic leiomyoma coagulation – myolysis. *Gynecol. Endoscopy.*, **4**, 5–11.
- Phillips, D.R., Nathanson, H.G., Milim, S.J. *et al.* (1997) Experience with laparoscopic leiomyoma coagulation and concomittant operative hysteroscopy. *J. Am. Assoc. Gynecol. Laparosc.*, **4**, 425–433.
- Vilos, G., Daly, L. and Tse, B. (1998) Pregnancy outcome after laparoscopic electromyolysis. *J. Am. Assoc. Gynecol. Laparosc.*, **5**, 289–292.
- Wood, C., Maher, P. and Hill, D. (1994) Myoma reduction by electrocautery. *Gynecol. Endosc.*, **3**, 163–165.
- Zreik, T., Rutherford, T., Palter, S. *et al.* (1998) Cryomyolysis, a new procedure for the conservative treatment of uterine fibroids. *J. Am. Assoc. Gynecol. Laparosc.*, **1**, 33–38.

Received on January 11, 2000; accepted on September 7, 2000